

## Histological and immunohistochemical study of the central nervous system of dogs naturally infected by *Leishmania (Leishmania) chagasi*

Fabiana Augusta IKEDA<sup>1</sup>  
 Márcia Dalastra LAURENTI<sup>2</sup>  
 Carlos Eduardo CORBETT<sup>2</sup>  
 Mary Marcondes FEITOSA<sup>3</sup>  
 Gisela Fabrino MACHADO<sup>3</sup>  
 Sílvia Helena Venturoli PERRI<sup>3</sup>

1 - Faculdade de Ciências Agrárias e Veterinárias da Universidade Estadual Paulista, Jaboticabal - SP

2 - Departamento de Patologia da Escola de Medicina da Universidade de São Paulo, São Paulo - SP

3 - Departamento de Clínica, Cirurgia e Reprodução Animal da Universidade Estadual Paulista, Araçatuba - SP

### Correspondence to:

MARY MARCONDES FEITOSA  
 Departamento de Clínica, Cirurgia e Reprodução Animal  
 Universidade Estadual Paulista  
 Rua Clóvis Pestana, 793 – Bairro Jardim Dona Amélia  
 16050-680 – Araçatuba – SP  
 feitosam@fmva.unesp.br

Received: 03/02/2004  
 Accepted: 06/02/2007

### Abstract

The present study aimed to characterize the histopathological alterations and to detect, by immunohistochemistry, the presence of amastigote forms of *Leishmania* in CNS tissue of dogs with and without neurological clinical signs of the disease. Two groups of animals were used: the first was composed of 18 dogs with visceral leishmaniasis without clinical evidence of neurological involvement, and the second, composed of 21 dogs with visceral leishmaniasis and neurological symptoms. The most frequent histopathological alterations found in the CNS of dogs of both groups were neuronal degeneration with neuronophagia, gliosis, leptomeningitis, vascular congestion, presence of perivascular lymphoplasmacytic infiltrate and areas of focal microhemorrhage. Antigen labeling for whole forms of *Leishmania* amastigotes was not observed in any fragment of the CNS of the dogs of either groups; however, most of them presented labeling of blood vessels walls, which suggests the presence of circulating parasite antigens.

### Key-words:

*Leishmania chagasi*.  
 Dogs.  
 Histopathology.  
 Immunohistochemistry.  
 Central nervous system.

### Introduction

Visceral leishmaniasis, also known as Kalazar, is an anthroponosis caused by protozoa of the genus *Leishmania*. In Brazil, visceral leishmaniasis is caused by *Leishmania (Leishmania) chagasi*, which has already been identified in dogs, cats, wild canines, marsupials and rodents<sup>1,2,3,4</sup>. Transmission between vertebrate hosts is carried out by the sting of the hematophagous phlebotomine *Lutzomyia longipalpis*<sup>2,3,5,6</sup> and, dogs, considered the main reservoir out of wildlife, are of great importance in maintaining the disease cycle. This importance comes from some facts: visceral leishmaniasis is more prevalent in the canine population than in the human population, human cases are normally preceded by canine cases, and dogs present a greater amount of parasites in the skin than

humans, which favors the infestation of vectors<sup>3,4,7</sup>.

Dog infection usually causes a chronic systemic disease, which is characterized by long periods of irregular fever, anemia, progressive weight loss, and cachexia in the terminal stage of the disease<sup>1,2,3,4,7,8,9,10</sup>. Infected animals can also present onychogryphosis, dermatological, ophthalmic, renal, and/or hepatic alterations, pneumonia, myocarditis, movement disorders, and hemorrhagic diathesis<sup>1,2,4,6,7,8,9,10,11,12,13,14,15,16</sup>.

In the infection by *Leishmania*, the cells of the mononuclear phagocyte system infected by parasites act as antigen-presenting cells, which activate T-helper lymphocytes (CD4+) type 1 (TH1), or type 2 (TH2). If activated, TH1 cells produce cytokines such as interferon gamma (IFN- $\gamma$ ), tumor necrosis factor (TNF), and interleukin 2 (IL-2), which, as they are considered proinflammatory,

enhance the efficiency of phagocytic cells and of cytotoxic lymphocytes. Activated macrophages, on their turn, produce oxygen-dependent free-radicals, which are toxic to the parasites, and may lead to parasitism control with total elimination of the infection. On the opposite, when the infection is associated with Type 2 T-helper lymphocyte (TH2), we have the production of anti-inflammatory cytokines such as interleukin 4 (IL-4), interleukin 5 (IL-5) and interleukin 10 (IL-10), and the proliferation of B cells with the production of antibodies. The resulting response of the immunoglobulins is very intense; however, it is deleterious and not protective. Thus, the infection develops. A potential danger of the impaired regulation of T-lymphocytes and of the enhanced activity of B-lymphocytes is the generation of a great amount of circulating immune complexes, which deposit on the walls of blood vessels, and may cause vasculitis, uveitis, dermatitis, polyarthritis, and glomerulonephritis. The circulating immune complexes may also bind the complement to the blood cells, and thus, decrease their half life, and may be associated to the development of pathological phenomena such as thrombocytopenia and immune-mediated anemia<sup>4,10,13,17</sup>.

Literature presents contradictions concerning the pathogenesis of visceral leishmaniasis in the central nervous system (CNS). While some authors reported the observation of parasites in all parts of the body, except in the CNS<sup>10</sup>, others observed intense deposition of parasite antigens and immunoglobulins in the interstitial and intravascular spaces of the choroid plexus in dogs with visceral leishmaniasis. This lead to choroiditis characterized by hypercellularity, capillary congestion, inflammatory cell infiltrate, thrombosis, epithelial metaplasia, and buildup of amyloid substance in the capillaries<sup>18,19</sup>. Concerning the encephalon and cerebellum, satellitosis, neuronophagia, intense mobilization of glial cells, degeneration of pyramidal neurons, and presence of amyloid buildup could be observed. Neuronal degeneration and

necrosis were also observed, besides edema in the Virchow-Robbin space, which contained amyloid intravascular buildup<sup>4,10,18,19</sup>.

Thus, the main goal of the present study was to characterize the CNS histopathological alterations, as well as to assess, by immunohistochemistry, the presence of *Leishmania* amastigotes in the CNS tissue of dogs with parasitological diagnosis of leishmaniasis, with and without clinical neurological signs of the disease, in order to clarify the mechanisms of the neurological lesion in canine visceral leishmaniasis.

## Materials and Method

Two groups of animals were used. The first was composed of 18 dogs with visceral leishmaniasis without clinical evidence of neurological involvement, and the second was composed of 21 dogs with visceral leishmaniasis and neurological symptoms. The animals had been referred to the Veterinary Hospital of the Veterinary Medicine Program of the Paulista State University "Júlio de Mesquita Filho"-UNESP – Campus Araçatuba, from June, 2000 to May, 2002.

Visceral leishmaniasis was diagnosed by lymph node aspiration biopsy and/or by ELISA serology test. All animals were subjected to a complete physical and neurological examination, and the data were registered in individual charts. After clinical evaluation, the animals were anesthetized with sodium pentobarbital (Hypnol 3%) and euthanized with a 10 mL ampule of 19.1% potassium chloride.

### Anatomical pathological examinations

The dogs were necropsied, the encephalon and the bone marrow were collected and evaluated with regards to the presence of macroscopic alterations. After the separation in two brain hemispheres, one of them was fixed in 10% phosphate buffered formalin pH 7.2. After a fixation period of approximately 24 hours, fragments

of the frontal cortex, lateral ventricle, piriform lobe, mesencephalon, cerebellar peduncle, cerebellum, cervical medulla, thoracic medulla, and lumbar medulla were collected. The fragments were embedded in paraffin and subjected to the routine histopathological procedure. Five-to six-micrometer-thick sections were stained by the hematoxylin-eosin method.

#### Immunohistochemistry

The immunohistochemical reaction was carried out to search for *Leishmania* amastigotes and antigens in the CNS by the Streptavidin-Peroxidase method. The sections were deparaffinized in a xylol wash at 60°C and rehydrated in absolute alcohol washes of decreasing concentrations, 95% and 70%, respectively. Antigen recovery was performed with the treatment of the sections in citrate buffer (3M), using a pressure cooker. Then several blockages were performed, such as of endogenous peroxidase, when hydrogen peroxide was used in association with methanol, and of secondary antibody, using normal serum of the same animal species from which the antibody was produced. Posteriorly, overnight incubation was carried out with anti-*Leishmania* primary polyclonal antibody, adsorbed with normal dog CNS powder, produced in mouse by the Laboratory of Pathology of Infectious Diseases of the Department of Pathology of the Medical School of the University of São Paulo. After incubation with secondary biotinylated antibody, incubation with Streptavidin-Peroxidase was carried out. The final reaction was revealed with hydrogen peroxide (H<sub>2</sub>O<sub>2</sub>) in the presence of Diaminobenzidina (DAB). Tissue counterstaining was performed with Harris hematoxylin. After section drying, the slides were mounted with coverslips using resin and were observed under an ordinary optical microscope to assess the presence and localization of *Leishmania* amastigotes and antigens.

#### Results

The main clinical neurological manifestations observed in the animals were

generalized seizures; visual alterations such as blindness, anisocoria and bilateral mydriasis; signs of paralysis of cranial nerves (strabismus, facial ptosis, dysphagia); signs of vestibular and cerebellar involvement (head tilting, nystagmus, motor incoordination, falls, intention tremor); paraparesis, tetraparesis and tetraplegia; myoclonias; vocalization; walking in circles, and episodes of tail chasing. The signs observed denote generalized CNS involvement, which reached the cerebral cortex, the encephalic trunk, the cerebellum, and the bone marrow.

The histopathological alterations most frequently found in the CNS of dogs naturally infected by *L. (L.) chagasi* with and without neurological symptoms were neuronal degeneration with neuronophagia, gliosis, which varied from focal to diffuse, leptomeningitis, vascular congestion and presence of perivascular lymphoplasmacytic infiltrate, and areas of focal microhemorrhages, among others. The number and percentage of animals in which the most frequent histopathological alterations were observed are shown in table 1. Significant differences were found regarding the number of animals with and without neurological symptoms that presented dark neurons, which characterize neuronal degeneration, diffuse gliosis and perivascular lymphoplasmacytic infiltrate. A greater number of animals with those histopathological alterations were found in the group with neurological symptoms ( $p < 0.05$ )

The immunohistochemistry reaction for parasite detection was carried out in sections of the same regions of the CNS previously stained with hematoxylin-eosin (HE): frontal cortex (FC), lateral ventricle (LV), piriform lobe (PL), mesencephalon (ME), cerebellar peduncle (CP), cerebellum (CE), cervical medulla (CM), thoracic medulla (TM), and lumbar medulla (LM). Figures 1 and 2 show photomicrographs of skin of dogs naturally infected by *Leishmania chagasi* that were used as positive and negative controls of the immunohistochemical reaction, respectively. Antigen labeling for

Table 1 - Main histopathological alterations observed in the CNS fragments, stained with hematoxylin-eosin (HE), in dogs with visceral leishmaniasis with and without neurological symptoms, and descriptive level between control group and group with neurological symptoms (Araçatuba – SP, 2004)

VARIABLE	CONTROL		NEUROLOGICAL		P
	N	%	N	%	
Leptomeningitis	12	66.7	19	90.5	0.075 <sup>(1)</sup>
Perivascular Lymphoplasmacytic Infiltrate	4	22.2	20	95.2	0.001 <sup>(2)</sup>
Choroiditis	5	27.8	4	19.0	0.395 <sup>(1)</sup>
Focal Microgliosis	8	44.4	13	61.9	0.276 <sup>(2)</sup>
Diffuse Gliosis	5	27.8	15	71.4	0.007 <sup>(2)</sup>
Satellitosis and Neuronophagia	18	100.0	21	100.0	—
Dark Neurons	17	94.4	13	61.9	0.019 <sup>(1)</sup>
White Matter Vacuolization	9	50.0	11	52.4	0.882 <sup>(2)</sup>
Gitter Cells	0	0.0	6	28.6	0.017 <sup>(1)</sup>
Vascular Congestion	18	100.0	21	100.0	—
Hemorrhages	16	88.9	16	76.2	0.273 <sup>(1)</sup>
Perivascular Edema	6	33.3	11	52.4	0.232 <sup>(2)</sup>

<sup>(1)</sup> descriptive level of Fisher's exact test <sup>(2)</sup> descriptive level of Qui-square test.

whole forms of *Leishmania* amastigotes was not observed in any fragment of the CNS of the dogs of either group; however, most of them presented labeling of blood vessels walls, which suggests the presence of circulating parasite antigens (Figure 3).

## Discussion

Medical literature has scarce information concerning the description of neurological symptoms associated to visceral leishmaniasis. Chungue, Gachihi and Muigai<sup>20</sup> reported the occurrence of generalized tremors in a patient with visceral leishmaniasis, and verified that the severity of the tremors was directly related to the parasitic load, for when parasite count was negative, indicating disease cure, the tremors disappeared. Despite these observations, the pathogenesis of the neurological involvement remained undetermined. Karak et al.<sup>21</sup>, described a case of a patient with visceral leishmaniasis with symptoms characteristic of unilateral cerebellar disorder and unilateral facial nerve paralysis, associated to a herpes zoster infection. In that case, the clinical signs

were justified by the presence of viral cerebellitis and peripheral neuropathy. In the dogs with meningoencephalitis associated to leishmaniasis, the signals observed denote generalized CNS involvement, which reaches the cerebral cortex, encephalic trunk, cerebellum, and bone marrow.

Many histopathological alterations were observed in the CNS of the animals in the control group. This corroborates the findings of Garcia-Alonso et al.<sup>18</sup>, who verified a clear pathological reaction in the CNS of dogs with visceral leishmaniasis without neurological symptoms. However, the histopathological alterations in the animals with neurological symptoms were more frequent and more intense. The histopathological alterations more frequently observed in the animals in the control group were: leptomeningitis, satellitosis and neuronophagia, and dark neurons. On the other hand, the histopathological alterations more frequently observed in the animals with neurological symptoms were leptomeningitis, satellitosis and neuronophagia, focal microgliosis, diffuse gliosis, and dark neurons, which corroborates the reports of Garcia-Alonso et al.<sup>18</sup> and

of Viñuelas et al.<sup>22</sup>. All the neurological symptoms observed in the dogs were compatible with the lesions observed in the histopathological examination, although there was no correlation between the intensity of the lesions and the severity of the clinical picture.

The immunohistochemical method did not evidence the presence of amastigote forms of the parasite in the CNS of the animals naturally infected by *L. (L.) chagasi* with and without neurological symptoms; however, it showed antigen labeling in the blood vessel walls. Our findings corroborate those described by Garcia-Alonso et al.<sup>18</sup>, who reported the presence of intense *Leishmania* antigen deposits in the choroid plexus of two dogs with visceral

leishmaniasis without neurological symptoms. Those findings suggest that the neurological picture associated to visceral leishmaniasis in the animals studied is due to the buildup of immune complexes, as occurs in other parts of the organism. Most CNS sections of the dogs in this study, when subjected to the immunohistochemical method, showed labeling inside the blood vessels, which may have occurred due to the presence of circulating *Leishmania* antigens.

Prasad and Sen<sup>23</sup> described chronic meningitis in a 10-year-old boy with visceral leishmaniasis. According to the authors, the neurological involvement started one year after the diagnosis of the disease. The specific treatment was not successful and there were several recurrence episodes within a period

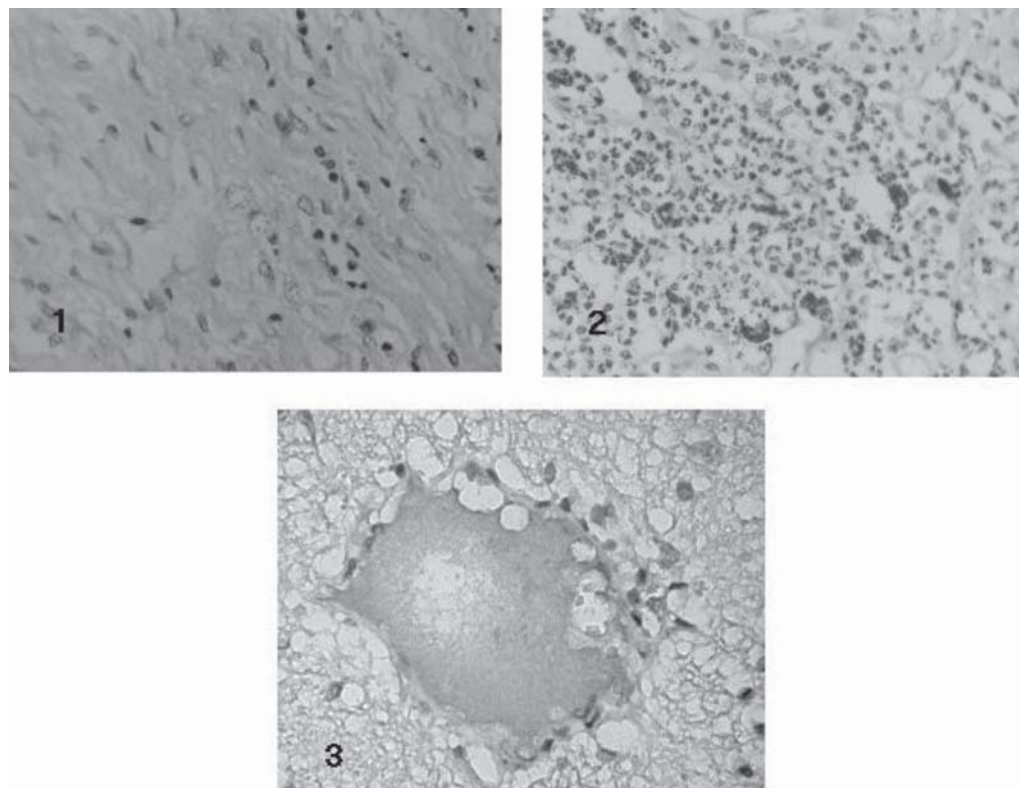


Figure 1 - Photomicrograph of skin of a dog naturally infected by *Leishmania chagasi*, used as negative control of the immunohistochemical reaction in which normal mouse serum was used as primary antibody. Note the absence of antigen labeling. (LSAB, AO 20x)

Figure 2 - Photomicrograph of skin of a dog naturally infected by *Leishmania chagasi*, used as positive control of the immunohistochemical reaction. Note the dark brown antigen labeling with no interference of nonspecific labeling. (LSAB, AO 20x)

Figure 3 - Photomicrograph of frontal cortex of a dog naturally infected by *Leishmania chagasi* with neurological symptoms. Note antigen labeling inside blood vessels. (LSAB, AO 40x)

of 20 months. In that period, several samples of CSF were collected from the patient, and in none of them there was evidence of the presence of amastigote forms of *Leishmania* in the CNS; only after splenectomy parasitic forms were observed in the CSF samples. The authors argue that, probably, after splenectomy the parasites migrated to the CSF, a safe site for proliferation, as it was not reached by most anti-*Leishmania* drugs that do not cross the hematoencephalic barrier. This could explain why repeated treatment protocols did not cure the patient. According to the authors, this was the first report in literature about the presence of *Leishmania* in the CSF of a patient with visceral leishmaniasis.

Despite some literature descriptions of the presence of amastigote forms of

*Leishmania* in the CNS of dogs with visceral leishmaniasis<sup>18,22</sup>, we did not detect the parasite in those tissues. Those findings were reported mainly in Europe - Spain and Italy - where the dogs are usually treated of visceral leishmaniasis. However, none of the reports mention the treatment the dogs underwent before euthanasia. If we follow the reasoning of Prasad and Sen<sup>23</sup>, a possible explanation for the appearance of parasites in the CNS of those dogs would be the attempt of the parasite to find a safer site in the organism where it could be less vulnerable to the attacks of the drugs used. This would also explain why the parasite was absent in our animals, as none of them were treated of the disease, having been euthanized as soon as the disease was diagnosed.

### **Estudo histológico e imunoistoquímico do sistema nervoso central de cães naturalmente infectados por *Leishmania (Leishmania) chagasi***

#### **Resumo**

O objetivo do presente estudo foi caracterizar as alterações histopatológicas e detectar por imunoistoquímica, a presença de formas amastigotas de *Leishmania* no sistema nervoso central de cães com e sem sintomatologia neurológica da doença. Foram utilizados dois grupos de animais; o primeiro foi composto de 18 cães com leishmaniose visceral sem evidência clínica de envolvimento neurológico, e o segundo, composto de 21 cães com leishmaniose visceral e sintomas neurológicos. As mais frequentes alterações histopatológicas encontradas no sistema nervoso central de cães de ambos os grupos foram degeneração neuronal com neuronofagia, gliose, leptomeningite, congestão vascular, presença de infiltrado linfoplasmocitário perivascular e áreas de microhemorragia. Não foram observadas marcações antigênicas para formas amastigotas de *Leishmania* em nenhum fragmento do sistema nervoso central de cães de ambos os grupos; entretanto, a maioria deles apresentava marcação em parede de vasos sanguíneos, o que sugere a presença de antígenos parasitários circulantes.

#### **Palavras-chave:**

*Leishmania chagasi*.  
Cães.  
Histopatologia.  
Imunoistoquímica.  
Sistema Nervoso Central.

#### **References**

- 1 GENARO, O. **Leishmaniose visceral canina experimental**. 1993. 202 f. Tese (Doutorado) - Universidade Federal de Minas Gerais, Belo Horizonte, 1993.
- 2 RIBEIRO, V. M. Leishmanioses. **Revista do Conselho Federal de Medicina Veterinária**. ano 3, n. 11, p. 13-14, 1997.

- 3 SANTA ROSA, I. C. A.; OLIVEIRA, I. C. S. Leishmaniose visceral: breve revisão sobre uma zoonose reemergente. **Clinica Veterinária**, ano II, n. 11, p. 24 – 28, 1997.
- 4 SLAPPENDEL, R. J.; FERRER, L. Leishmaniasis. In: GREENE, C. E. **Clinical microbiology and infectious diseases of the dog and cat**. Philadelphia: W.B.Saunders, 1998. p. 450-458.
- 5 ALENCAR, J. E.; NEVES, J.; DIETZE, R. Leishmaniose visceral (Calazar). In: VERONESI, R. **Doenças**

- infeciosas e parasitárias.** Rio de Janeiro: Guanabara Koogan, 1991. p. 706-717.
- 6 BURACCO, P. et al. Osteomyelitis and arthrosynovitis associated with *leishmania donovani* infection in a dog. **Journal Small Animal Practice**, v. 38, n. 1, p. 29-30, 1997.
- 7 FERRER, L. Leishmaniasis. In: KIRK, R. W.; BONAGURA, J. D. **Kirk's current veterinary therapy XI.** Philadelphia: W. B. Saunders, 1992. p. 266-270.
- 8 LONGSTAFFE, J. A. et al. Leishmaniasis in imported dogs in the United Kingdom; a potential human health hazard. **Journal of Small Animal Practice**, v. 24, p. 23-30, 1983.
- 9 MARZOCHI, M. C. A. et al. Leishmaniose visceral canina no Rio de Janeiro - Brasil. **Caderno de Saúde Pública**, v. 1, n. 4, p. 432-446, 1985.
- 10 NOLI, C. Leishmaniosis canina. **Waltham Focus**, v. 9, n. 2, p. 16-24, 1999.
- 11 CIARAMELLA, P. et al. A retrospective clinical study of canine leishmaniasis in 150 dogs naturally infected by *leishmania infantum*. **Veterinary Record**, v. 141, n. 21, p. 539-543, 1997.
- 12 GARCÍA-ALONSO, M. et al. Immunopathology of the uveitis in canine leishmaniasis. **Parasite Immunology**, v. 18, n. 12, p. 617-623, 1996b.
- 13 LOPEZ, R. et al. Circulating immune complexes and renal function in canine leishmaniasis. **Journal of Veterinary Medicine**, v. 43, n. 8, p. 469-474, 1996.
- 14 MORENO, P.; LUCENA, R.; GINEL, P. J. Evaluation of primary haemostasis in canine leishmaniasis. **Veterinary Record**, v. 142, n. 4, p. 81-83, 1998.
- 15 NIETO, C. G. et al. Pathological changes in kidneys of dogs with natural *Leishmania* infection. **Veterinary Parasitology**, v. 45, n. 1-2, p. 33-47, 1992.
- 16 VALLADARES, J. E. et al. Hepatobiliar and renal failure in a dog experimentally infected with *leishmania infantum*. **Veterinary Record**, v. 141, n. 22, p. 574-575, 1997.
- 17 ROITT, I.; BROSTOFF, J.; MALE, D. **Imunologia.** São Paulo: Manole, 1994. 400 p.
- 18 GARCÍA-ALONSO, M. et al. Presence of antibodies in the aqueous humour and cerebrospinal fluid during *Leishmania* infections in dogs. Pathological features at the central nervous system. **Parasite Immunology**, v. 18, p. 539-546, 1996a.
- 19 NIETO, C. G. et al. Detection of *Leishmania infantum* amastigotes in canine choroid plexus. **Veterinary Record**, v. 139, n. 14, p. 346-347, 1996.
- 20 CHUNGE, C. N.; GACHIHI, G.; MUIGAI, R. Is neurological involvement possible in visceral leishmaniasis in Kenya? **Transactions of the Royal Society of Tropical Medicine and Hygiene**, v. 79, n. 6, p. 872, 1985.
- 21 KARAK, B. et al. Neurological manifestations in a patient with visceral leishmaniasis. **Postgraduate Medical Journal**, v. 74, n. 873, p. 423-425, 1998.
- 22 VIÑUELAS, J. et al. Meningeal leishmaniasis induced by *Leishmania infantum* in naturally infected dogs. **Veterinary Parasitology**, v. 101, n. 1, p. 23-27, 2001.
- 23 PRASAD, L. S. N.; SEN, S. Migration of *leishmania donovani* amastigotes in the cerebrospinal fluid. **The American Journal of Tropical Medicine and Hygiene**, v. 55, n. 6, p. 652-654, 1996.
- 24 FEITOSA, M. M. et al. Alterações do líquido de cães com encefalite por cinomose e suas correlações com as alterações anatomopatológicas do sistema nervoso central. **ARS Veterinária**, v. 13, n. 1, p. 6-16, 1997.