

Epidemiological and clinical aspects of equine Herpesvirus encephalitis infection in horses that died with neurological signs from Minas Gerais state, Brazil

Érica Azevedo COSTA^{1,3}
 Anilton Cesar
 VASCONCELOS²
 Maria Rosa Quaresma
 BOMFIM¹
 Marcos Xavier SILVA³
 João Paulo Amaral
 HADDAD³
 Hábner Bastos AMORIM³
 Gabriella Breder Lara LIMA²
 Ronaldo FURTINI⁴
 Mauricio RESENDE¹

Correspondence to:

Érica Azevedo Costa, Departamento de Clínica e Cirurgia Veterinárias da Escola de Veterinária da UFMG, Av. Antônio Carlos 6627, Campus da UFMG, Caixa Postal 567, 30123-970, Belo Horizonte, MG, azevedoec@yahoo.com.br.

Recebido para publicação: 04/10/2008
 Aprovado para publicação: 30/10/2008

1 - Departamento de Microbiologia do Instituto de Ciências Biológicas da Universidade Federal de Minas Gerais, Belo Horizonte-MG
 2 - Departamento de Patologia do Instituto de Ciências Biológicas da Universidade Federal de Minas Gerais, Belo Horizonte-MG
 3 - Departamento de Medicina Veterinária Preventiva da Escola de Veterinária da Universidade Federal de Minas Gerais, Belo Horizonte-MG
 4 - Instituto Mineiro de Agropecuária, Belo Horizonte-MG

Abstract

During the period of October 2004 until February 2006, 75 samples of central nervous system (CNS) obtained from horses that died with neurological signs in the state of Minas Gerais were sent to the Laboratory of Compared Virology in ICB/UFMG for diagnosis of equine herpesviruses. All samples were previously diagnosed negative for rabies virus by the Laboratório de Saúde Animal of the Instituto Mineiro de Agropecuária (IMA). Among the analyzed samples, 39 (52%) were positive for the equine herpesvirus 1 (EHV-1) through the polymerase chain reaction assay (PCR). In most cases, the histopathological examination of the CNS revealed a mild vasculitis with perivascular mononuclear cuffing, congestion, arterial thrombosis and degeneration of nervous tissue. The positive CNS samples for EHV-1 were obtained from horses sampled from 30 municipalities of Minas Gerais state. The cases occurred in an isolated form in different periods of the year, not presenting a seasonal character. The clinical course duration was acute, varying between one and four days. The most frequently observed neurological signs were ataxia, unsteadiness in the hind limb, paralysis of hind limbs and recumbency. According to information provided by IMA, the infections caused by EHV-1 were as frequent as the ones caused by rabies virus in horses of Minas Gerais state during the studied period. Hence, it became important to include EHV-1 encephalitis in the differential diagnosis from other diseases of the central nervous system in horses of Minas Gerais state.

Key words:

Horses.
 Central Nervous System.
 PCR.
 Equine Herpesvirus 1 (EHV-1).
 Epidemiology.

Introduction

Equine herpesvirus 1 (EHV-1) and equine herpesvirus 4 (EHV-4), members of the *Alphaherpesvirinae* subfamily, are highly prevalent equine pathogens that can cause a range of clinical signs, from respiratory disease to the induction of abortion, neonatal mortality, and neurological damage resulting in paralysis.^{1,2} These two

herpesviruses are remarkably ubiquitous, and infection is enzootic in most horse populations. Exposure to the viruses occurs early in life with an estimated 80 - 90% of horses being infected by 2 years of age.³ The EHV-4, which can also cause neurological disorders, is much less frequently reported than EHV-1.⁴ The manifestations of EHV-1 infections are characterized by the strain of the virus, whether the infection is

primary, a reinfection, or a reactivation of latent virus along with several factors relating to the horse, including age, physical condition, immunological, and reproductive or pregnancy status.⁵

There is strong evidence that only certain strains of EHV-1 cause myeloencephalitis.⁶ It was recently reported that an alteration in the code of a single amino acid of DNA polymerase gene in samples of EHV-1 produces a hypervirulence and becomes a genetic marker between neuropathogenic and non-neuropathogenic samples.⁵ It is thought that the outbreaks of the neurological disease are initiated by reactivation and concomitant nasal transmission of mutant strains of EHV-1 carried by horses latently infected⁷. In susceptible horse populations, infection with a neurovirulent strain of EHV-1 may involve a single animal or be associated with large outbreaks of disease with high rates of morbidity and mortality resulting in devastating economic and welfare consequences.^{7,8} The outbreak frequency of the neurological disease caused by neurovirulent samples of EHV-1 has been rising in an alarming way over the years.^{2,9} The outbreaks are often associated with abortions and/or respiratory diseases, but they may also occur without precursor signs.¹⁰

The clinical signs of myeloencephalitis caused by EHV-1 range from mild to severe hind limb ataxia and paresis, which may progress to complete recumbency.¹¹ Frequently, tail paralysis and bladder incontinence are observed as perineal hypalgia or anesthesia. The clinical sign progression is usually rapid during the first 24 hours.¹¹ A gradual recovery may occur over weeks or months. The prognosis for horses that do not present recumbency is favorable; however, for horses that remain recumbent for periods greater than 24 hours^{11,12}, the outlook is not good.

It is not common to find gross pathologic lesions in the central nervous system (CNS), but small focal areas of hemorrhage distributed randomly throughout the meninges and parenchyma of the brain and spinal cord may be observed. The histological injuries of CNS include vasculitis necrotizing, congestion,

thrombosis, and secondary ischemic degeneration.¹³ These lesions are observed because neurological samples of EHV-1-induced myeloencephalitis are exhibited through an endoteliotropism instead of a specific neurotropism in contrast to several other alphaherpesviruses, such as bovine herpesvirus 5 (BHV-5) and Aujeszky's disease virus (ADV).⁴

In the acute stage of the neurological disease infection, the presumptive diagnostic of EHV-1 can be done by virus isolation or by PCR of nasopharyngeal swabs, mononuclear cells of the peripheral blood (PBMC), and/or cerebrospinal fluid. After death, histopathological indicators in the CNS and spinal cord may be confirmed by using the immunoperoxidase method, virus isolation, and/or PCR.^{14,15,16}

This study highlights the importance of including equine encephalitis by herpesvirus 1 (EHV-1) in the differential diagnosis of other neurological diseases in horses. It is noteworthy that CNS samples from horses that died with nervous signs are commonly analyzed only for detection of rabies virus. This approach could be very useful for understanding the true reality on the spread of EHV-1 in horses in the state of Minas Gerais.

Material and Method

Between October 2004 and February 2006, 112 nervous system samples from horses that had died with neurological signs were submitted to IMA (Instituto Mineiro de Agropecuária) for veterinary diagnosis. These samples were collected from horses of different ages and breeds from several regions in Minas Gerais state. The sample selection was not random; rather, it represented a subset of samples that were examined for rabies virus by IMA. Considering that the sampling process of these data should provide a reasonable estimate of the occurrence of EHV-1 encephalitis in Minas Gerais.

The main clinical signs observed in the horses included ataxia, unsteadiness of the hind quarters, and hindlimb paresis. These signs may be associated with rabies or encephalitis caused

by herpesvirus. A specific questionnaire with relevant information for each animal was collected, including epidemiological data, clinical signs, and duration of the clinical course. All samples were previously analyzed by immunofluorescence antibody test and mice inoculation for rabies at the Laboratório de Saúde Animal of IMA. Thirty-seven out of 112 samples (33%) were found positive for rabies and were excluded from the EHV-1 survey. The 75 remaining CNS samples were brought to the Laboratory of Compared Virology (LVC) of the Instituto de Ciências Biológicas of Universidade Federal de Minas Gerais (UFMG) for the EHV-1 survey.

According to data obtained by questionnaires, 92.2% of horses died by natural course of neurological disease, without euthanasia. No data for the state immunization of horses was obtained, since that the equine rhinopneumonitis virus vaccine does not confer immunity against neurological strains of EHV-1.⁵

For the DNA extraction, a 20% w/v suspension was prepared with fragments of CNS tissues using phosphate-buffered saline solution (pH 7.2). The suspension was vortexed and centrifuged at 4,000 x g for 5 min, and the supernatant was precipitated overnight with 16% polyethylene glycol 8,000 in 0.8 M NaCl.¹⁷ The samples were centrifuged at 14,000 x g for 3 min, and the pellet was used for DNA extraction using the guanidine-silica protocol.¹⁸

The following EHV-1 primers used were selected from the EHV1.HVS25A glycoprotein H (gH) sequence, GenBank Accession Number X51324: forward 5'-AAGAGGAGCACGTGTTGGAT-3', reverse 5'-TTGAAGGACGAATAGGACGC-3'; the second reverse primer for the semi-nested PCR was 5'-AGTAGGTCAGGCCGATGCCT-3'. These primers were estimated to yield a first round product of 636 bp and a second round of 287 bp.¹⁹ Moreover, EHV-4 primers were selected from the glycoprotein B (gB), sequence GenBank Accession Number M26171: forward 5'-CTGCTGTCATATATGCAGGGA-3', reverse 5'-CGTCCTTCTCGAAGACGGTA-3'; the second reverse primer for

the semi-nested PCR was 5'-CGCTAGTGTCATCATCGTTCG-3'. The expected PCR product size in a first round was 509 bp and a second round was 323 bp. Primers and semi-nested PCR conditions were performed as described previously.¹⁹ An internal control of the amplification efficiency and primers for the insulin growth factor gene (IGF-1) were used, which amplifies a product of 225 bp.²⁰ These primers were forward 5'-CTCACTGTCACTGCTAAA-3' and reverse 5'-AAGAAATCACAAAAGCAGC-3' and the PCR conditions were performed as previously described.¹⁹ The amplified products were analyzed with 2.0% agarose gel electrophoresis stained with ethidium bromide, using a 100 bp DNA ladder molecular marker (Invitrogen Corp., Carlsbad, CA). A positive control for EHV-1 used was the first strain detected in Minas Gerais and was designated Strain Bucareste. This strain was sequenced and the nucleotide sequence was deposited in the GenBank Accession number DQ864706. For EHV-4 strains was used only the internal control (IGF-1) gene.

For the histological examination, CNS tissue samples were placed in 10% neutral buffered formalin and subsequently embedded in paraffin, sectioned, and stained with haematoxylin and eosin.²¹

The CNS samples were analyzed only from EHV-1-positive horses by PCR assay.

Isolation of EHV-1 was attempted for 4 randomly chosen positive PCR samples. For virus isolation, 2.0 ml of homogenized CNS tissue were inoculated in 25 ml culture flasks of Rabbit Kidney (RK13) cells. Cells were grown in DMEM (Invitrogen Corp., Carlsbad, CA) containing 0.5 g/L NaHCO₃ and 20 mM HEPES and supplemented with 1 mM Na-pyruvate and 10% fetal bovine serum. When the cytopathic effect (CPE) was 90%, the tissue culture fluids were collected, centrifuged, and stored in liquid nitrogen. To confirm viral isolation, the DNA was extracted and amplified by specific semi-nested PCR, as described previously.¹⁹

In this work, four samples of CNS from horses were chosen for viral isolation.

The isolation of EHV-1 from horses showing nervous signs is difficult and highly variable. Some factors may be associated with the failure and low sensitivity of conventional isolation methods. The neural cells may be low in number, the segmental distribution of virus and also the poor conservation-quality of clinical samples. It can be assumed that the time between acute virus replication and horse death may be critical for identification of EHV-1 in neural tissues.^{15,16}

Statistical analysis of the data was performed using Fisher's exact test or the Chi-square test (χ^2 test).²² A p-value < 0.05 was considered significant and was calculated through Monte Carlo Simulations using SPSS 15.0 software. A statistical analysis was performed correlating the results obtained in the present study with the clinical history of each animal derived from descriptive reports sent by IMA veterinarians.

Results

EHV-1 and EHV-4 prevalence determined by semi-nested PCR assay

Out of the 75 rabies-negative CNS samples that were tested for equine herpesvirus myeloencephalitis (EHV-1 and EHV-4) by semi-nested PCR, 39 (52%) were positive for EHV-1. The specific fragment of 287 bp for EHV-1 was detected by semi-nested PCR with primers targeting glycoprotein H (gH)¹⁹. No EHV-4 was detected in the DNA of CNS samples. This result was similar to that reported in previous Brazilian studies where the EHV-4 was not detected in foetuses and young foals specimens²³. The endogenous fragment of 225 bp (IGF-1) was consistently detected in all 75 samples. The positive control used in this study was the first neurological strain of EHV-1 detected in Minas Gerais, previously designated as strain Bucareste²⁴.

Historical data

A total of 30 (71.4%) of the 42 municipalities examined presented positive samples for EHV-1. These EHV-1-positive samples were collected from 3 different

regions (Alto Paranaíba, Central and Southern regions of Minas Gerais), a majority of which, 21 (70%), showed only one positive case per county. The largest number of samples received for this survey was collected in the Central and Southern regions, with 22 and 25 submissions, respectively, but the highest positivity rate was found in the Southern region with 23 (59%) cases. The Center and Alto Paranaíba regions had 15 cases (38.5%) and 1 (2.6%) case, respectively. The municipalities with more than one case of EHV-1 were Pedro Leopoldo (Center region) and Uberaba (South region), with 3 cases per county, and Belo Horizonte, Itabirito (Center region), Cruzília, Juiz de Fora, Muriaé e São Sebastião do Paraíso (South region) with 2 positive cases. The cases of EHV-1 occurred all year round, and no seasonal clustering was observed.

Statistical analysis

The nervous signs that were most frequently reported in the records of horses infected by EHV-1 were ataxia (92.3%), unsteadiness in the hind quarters (71.8%), hindlimb paresis (61.5%), and recumbency (48.7%). In this work, the ataxia means only incoordination of walking (gait ataxia) and dysequilibrium. The EHV-1 PCR-positive and negative horses were correlated with the nervous signs presented, and the associations were found for the following signs: hindlimb paresis and unsteadiness in the hind quarters for horses that were EHV-1 PCR-positive. Table 1 shows the nervous signs presented by these animals.

Table 2 shows the correlations for sex, age, breed, and clinical course for EHV-1 PCR-positive- and EHV-1 PCR-negative-horses. Both male and female horses, including several breeds and non-immunized animals, were infected by EHV-1. The age of EHV-1 PCR-positive horses ranged from 3 months to 20 years, and 69.2% of these horses were 1 to 5 years old. The clinical course of the disease varied from 1 to 11 days, with 71.8% of cases ranging from 1 to 4 days. No significant association for the

Table 1 - Occurrence of nervous signs in EHV-1 PCR-positive and EHV-1 PCR-negative horses. Ataxia is the reference group - Belo Horizonte - Minas Gerais - 2007

Nervous signs	No. of horses EHV-1		p- value
	PCR positive	PCR negative	
Ataxia	36	15	
Unsteadiness in the hind limb	28	10	0.47 ^{FT}
Hind limb paresis	24	6	0.25 ^{FT}
Recumbency	19	13	0.21 ^{FT}
Muscular spasm	14	7	0.48 ^{FT}
Apathy	13	6	0.54 ^{FT}
Padding movements	11	4	0.56 ^{FT}
Opisthotonus	10	4	0.62 ^{FT}
Frequent convulsions	6	2	0.58 ^{FT}

FT - Fisher's Exact Test

Table 2 - Correlation with sex, age, breed and clinical course for EHV-1 PCR-positive and EHV-1-negative horses Belo Horizonte - Minas Gerais - 2007

Description	No. of horses EHV-1 PCR-positive	No. of horses EHV-1 PCR-negative	P value	OR (Confidence Interval 95%)	RR (Confidence Interval 95%)
Gender distribution					
F	29	23	0.46 ^{QS}	1.64 (0.55 - 4.96)	1.28 (0.76-2.17)
M	10	13			
Total	39	36			
Age distribution (Yr)					
≤ 4	21	24			
5 to 10	12	10	0.36 ^{FT}		
> 11	6	2	0.14 ^{FT}		
Breed distribution					
Mixed-breed	28	14	0.008 ^{QS}	4.00 (1.37 - 11.90)	2.00 (1.18 - 3.39)
Pure Breed	11	22			
Clinical course (days)					
1	13	10			
2 to 3	12	8	0.53 ^{FT}		
4 to 5	7	7	0.48 ^{FT}		
6 to 11	7	11	0.21 ^{FT}		

QS - Square Test; FT - Fisher's Exact Test; OR - Odds Ratio; RR - Relative Risk

intervals of the clinical course was found. With regard to the sex of the horses, the Odds Ratio values (OR) demonstrated a probability of infection of 1.64 for females when compared to males. The values of Relative Risk (RR) showed a relatively higher risk (1.28) for females than for males.

With regard to pure-bred status, there

was an association for the presence of EHV-1 for animals of unidentified breed. It is noteworthy that among the pure breeds are considered the Brasileiro de Hipismo, Mangalarga-Machador, Campolina, Arabic and Anglo-Arab. The Brazilian breeds as Brasileiro de Hipismo and Mangalarga-Machador, in this work, were included

breeds as “pure” despite being derived from the intersection of several breeds. A relatively higher infection risk of 1.87 was found among animals of unidentified breeds when compared to the pure-bred group. The OR values demonstrated a higher probability of 4.00 for the unidentified breed group when compared to the pure-bred group.

Histopathological observations

Out of 39 EHV-1 PCR positive CNS samples (brain, cerebellum, and spinal cord), 28 (71.8%) were received in 10% neutral buffered formalin for histopathological examination. In most of these samples (21/28, 75%), a mild vasculitis was observed with perivascular mononuclear cuffing composed predominantly of lymphocytes, dark shrunken neurons, diffuse gliosis, sometimes with neuronophagia, and focal congestion. The cerebellum was particularly affected with degeneration of nervous tissue and intense shrinkage of Purkinje and Granular Cells (Figura 1). The gray area of the spinal cord, as well as dark and shrunken neurons, showed a hypocellularity (Figura 2). An arterial thrombosis was also evident on cerebral meninges. In 7 samples, vasculitis was not found, but a degeneration of nervous tissue as gliose, neuronophagia, dark shrunken neurons, and vascular lesions as congestion (Figura 3) and thrombosis (Figura 4) were observed.

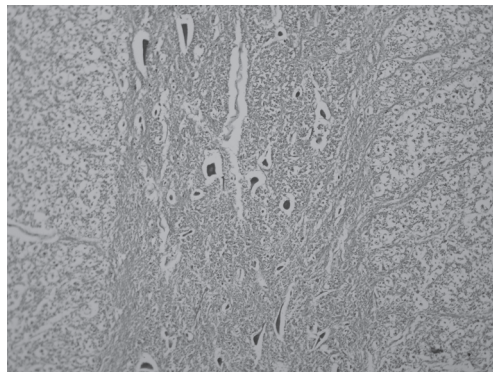


Figure 1 - Fragment of Spinal Cord, stained by HE, magnified with objective 40X. Gray area of the spinal cord showing hypocellularity and dark and shrunken neurons - Belo Horizonte - Minas Gerais - 2007

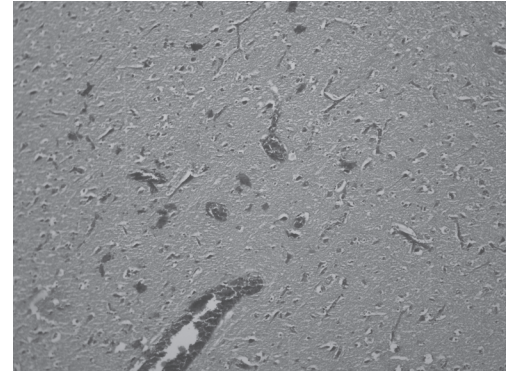


Figure 2 - Fragment of brain, stained by HE, magnified with objective 20X. Hyperemic vessels and moderate gliosis in neuropil - Belo Horizonte - Minas Gerais - 2007

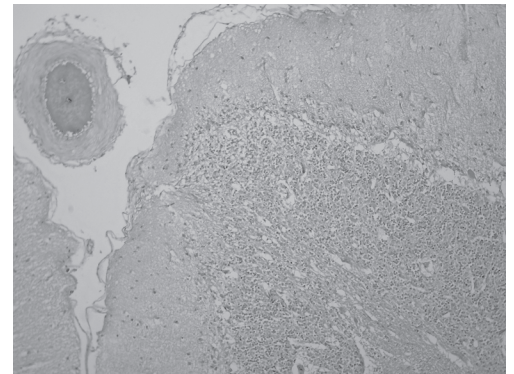


Figure 3 - Fragment of Cerebellum, stained by HE, magnified with objective 10X. Meningeal vessel occluded by a recent thrombi. Shrunken molecular layer at the top of the gyrus, decrease in Purkinje Cells with empty lacunas (basket cells only). Granulosa layer without any lesion - Belo Horizonte - Minas Gerais - 2007

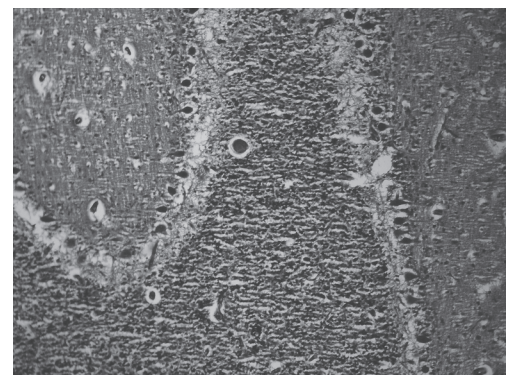


Figure 4 - Fragment of Cerebellum, stained by HE, magnified with objective 20X. Dark and shrunken Purkinje Cells, with some displacing into the Granulosa layer, which was also showed shrunken neurons - Belo Horizonte - Minas Gerais - 2007

Isolation of EHV-1

Out of 39 samples that were PCR positive for EHV-1, 4 were chosen randomly, and the virus was isolated from these samples. After three to four blind passages, cells showed many foci consisting of areas where the cells were rounded, and there was syncytium formation of the infected rabbit kidney (RK13) monolayer cell cultures. After 40 hours of incubation, the cytopathic effect progressed to involve the entire monolayer and cell lyses could be observed. To confirm the isolation of EHV-1, the specific fragment of 287 bp for EHV-1 was detected by semi-nested PCR with primers targeting the glycoprotein H (gH) in all 4 samples.

Discussion

In Brazil, the first infections related to EHV-1 were found in cases of abortions in the states of São Paulo, Minas Gerais, and Rio Grande do Sul, since the first report occurred in 1966 in São Paulo.^{25,26,27,28} Thus, serological studies have attempted to estimate the occurrence of EHV-1 infection in herds with reproductive problems in the states of São Paulo and Rio Grande do Sul. The positive rates for these states are 27.2 and 84.7%, respectively.^{27,28} The high rates of antibody presence suggest that EHV-1 is present in Brazil and may be more frequent in offspring of horses that have been reported as positive.²⁷ Meanwhile, the first report of encephalomyelitis associated with EHV-1 infection in a horse that showed neurological signs occurred in the state of São Paulo only very recently.^{15,16}

Outbreaks of the neurological disease caused by EHV-1 infection have been detected in several countries such as the USA⁷, Holland¹⁴, and Australia⁶, with considerable increases in recent years^{7,9}.

This encephalitis study suggests that, in Minas Gerais, EHV-1 is not only widespread but is also an important cause of encephalitis. Historically, the practitioner has associated viral encephalitis with rabies infection. Until now, encephalitis cases that

were negative for rabies did not have a definitive diagnosis in Minas Gerais. The presence of nervous signs frequently associated with other pathologies of the nervous system required further research to find the causative agents. Furthermore, there is also a need for EHV-1 research, especially if the clinical results of rabies infection are not conclusive or negative.

Outbreaks of the neurological form of EHV-1 are diagnosed at major facilities but it is believed that these are less frequent than isolated cases.¹⁴ In this study, only isolated cases of EHV-1 were diagnosed, with a maximum of 2 horses affected per property. The geographic distribution of this virus was concentrated mainly in the Southern region, with 23 (59%) cases, and the Central Region, with 16 (41%) cases. The absence of reports of the neurological form of EHV-1 in Minas Gerais is probably associated with the lack of laboratories that can diagnose neurological disorders in samples collected from horses. The form of EHV-1 that causes abortion, however, has been frequently observed in the state.

A larger number of cases related to neurological damage caused by EHV-1 occurred at the end of the winter, in spring, and at the beginning of summer, possibly reflecting a seasonal occurrence of abortions caused by EHV-1.¹⁴ In this study, the neurological disease caused by EHV-1 did not present any seasonality, as it was diagnosed in all months. In November and December, however, a larger number of cases were documented (6 cases in each month). In two cases, the neurological signs appeared during gestation and 30 days after labor in another. Neurological outbreaks caused by EHV-1 are frequently associated with abortions and/or respiratory disease, but they may occur without precursor signs.¹⁰

In this study, the most reported nervous signs from EHV-1-positive horses were ataxia, unsteadiness in the hind limbs, hindlimb paresis, and recumbency. Nervous signs such as hindlimb paresis and unsteadiness in the hind limbs were significant and suggested that horses presenting these

signs have a higher probability of being infected by EHV-1. Consistent with the literature^{6,7}, these data may assist in presumptive diagnoses and in accomplishing definitive diagnoses with the correct tissue material.

The onset of the nervous signs observed in this study varied from 1 to 11 days, but, in 71.8% of the cases with neurological involvement by EHV-1, the clinical course varied from 1 to 4 days. The clinical sign progression is usually rapid during the first 24 hours, and it reaches peak intensity within 2-3 days of onset, though a gradual recovery may occur after weeks or months.³

Regarding the presence of EHV-1 in horses of mixed breeds when compared to the pure-breed group, the results suggest that problems relating to management are involved, since mixed breeds usually have economic values lower than those of pure breed, however, there no data from previous studies that supports these findings.

Studies have demonstrated that the severity of disease resulting from EHV-1 infection is likely to be influenced by a number of factors, including physical condition of the host.⁵ Through this, the increased susceptibility of females to EHV-1 infection than males could have influenced by stress caused during pregnancy or after birth. During these periods, details in management should not be discarded, mostly greater population density among mares.

In this study, all histopathological lesions in CNS from horses that were EHV-1-positive were basic vascular injuries and secondary ischemic degeneration of the nervous tissue, as described for cases of EHV-1 myeloencephalopathy.¹³ These lesions in the CNS do not appear to be specific, showing an absence of direct effects of the virus on vessel walls or in neurons.²⁹ The lesions appear, however, to be a result of ischemia and consequent tissue anoxia, obtained after thrombosis, which probably also leads to the degeneration of nervous tissue as necrosis of neurons in some areas of the brain. The EHV-1 neurovirulence

seems to be secondary to circulatory damage.³⁰

Although vasculitis is a consistent finding, degeneration of nervous tissue is evident chiefly in horses with clinical evidence of severe neurological disease. Vasculitis is often severe and has a wide-spread, random, multifocal distribution with the most severe lesions usually seen in the brain stem and spinal cord.¹³ In this study, however, vasculitis was considered mild in most cases and absent in others. The degree of microscopic lesions characteristic of paralytic EHV-1 infection and the identification of the EHV-1 antigen in neural tissues decreased progressively in more chronic cases.³⁰ Thus, in these cases, the CNS had light microscopic lesions characteristic of paralytic EHV-1 infection and the lack of expression of viral antigen, which may mean that the virus was no longer present or had established a state of latency.³¹ We suggest that sampling at the proper time during the course of clinical disease appears to be an important factor for finding viral antigen and histopathological lesions characteristic of the disease. As the lymphoid tissues and the peripheral blood leukocytes (PBL) are the sites of latency of EHV-1, and the persistence of latent virus in leukocytes allows rapid dissemination through the vascular and lymphatic systems, the lesions frequently are not confined to the CNS^{13,31}. This finding suggests that, when horses with suspected EHV-1 myeloencephalopathy die or are euthanized, at least the head, spine, spleen, Lymph nodes, peripheral blood leukocyte (PBL) and lungs should be submitted for post-mortem examination because lesions may not be confined to the CNS of horses with EHV-1 myeloencephalopathy.¹³

The differential diagnoses in neurological disorders that affect horses, in addition to rabies, EHV-1 and EHV-4 are Aujeszky's disease, equine protozoal myeloencephalitis, polyneuritis equi, western equine encephalitis; eastern equine encephalitis, venezuelan equine encephalitis, sarcocysts, central nervous system trauma, lead poisoning, tetanus and botulism. This

suggests that the diagnosis of the 36 remaining CNS samples (negative for the rabies virus, EHV-1 and EHV-4) may be included in these cases.^{32,33}

The definitive diagnosis of neurological EHV-1 may be performed through virus isolation, detection of virus DNA by PCR, or through immunohistochemistry by the presence of viral antigens in the CNS and/or the spinal cord of the horse.^{6,34}

The present study showed that the neurological form of EHV-1 is underdiagnosed in Minas Gerais, reflecting a need

for more epidemiological studies, which would be essential for improving veterinarian awareness, and for assisting them in making rapid and efficient diagnoses.

Acknowledgements

We thank the veterinary practitioners who have participated in this study and to the farm owner. This study was supported by CNPq grant 474015/2001-7. Érica A. Costa and Maria Rosa Q. Bomfim received fellowship from FAPEMIG.

Aspectos epidemiológicos e clínicos da infecção neurológica associada ao herpesvírus eqüino 1 (ehv-1) em cavalos que morreram com sinais nervosos no Estado de Minas Gerais, Brasil

Resumo

Durante o período de Outubro de 2004 a Fevereiro de 2006, 75 amostras de sistema nervoso central (SNC) oriundas de eqüinos que morreram com sinais neurológicos no estado de Minas Gerais foram enviadas ao Laboratório de Virologia Comparada no ICB/UFMG para o diagnóstico de herpesvírus eqüino. Essas amostras foram previamente diagnosticadas negativas para o vírus da raiva através dos testes de imunofluorescência direta e inoculação em camundongos, no Laboratório de Saúde Animal (LSA) do Instituto Mineiro de Agropecuária (IMA). Dentre as amostras analisadas, 39 (52%) foram positivas para o herpesvírus eqüino 1 (EHV-1) através da técnica de reação em cadeia pela polimerase (PCR). Na maioria dos casos, o exame histopatológico do SNC revelou uma discreta vasculite com infiltrado perivascular de células mononucleares, congestão, trombose arterial e degeneração do tecido nervoso central. As amostras de SNC positivas para o EHV-1 foram coletadas de eqüinos oriundos de 30 municípios de Minas Gerais. Os casos de EHV-1 ocorreram de forma isolada não apresentando caráter sazonal. Na maioria dos casos (71,8%), a evolução dos sinais clínicos foi aguda, sendo que os sinais clínicos observados com mais frequência foram ataxia, instabilidade dos membros posteriores, paralisia dos membros posteriores e decúbito. De acordo com informações relatadas pelo IMA, as infecções causadas pelo EHV-1 foram tão frequentes como as infecções causadas pelo vírus da raiva em eqüinos no estado de Minas Gerais durante o período estudado. Portanto, torna-se importante a inclusão da encefalite pelo EHV-1 no diagnóstico diferencial de outras doenças do SNC de eqüinos no estado de Minas Gerais

Palavras-chave:

Eqüinos.
Sistema Nervoso Central.
PCR.
Herpesvirus eqüino 1 (EHV-1).
Epidemiologia.

References

1 GALOSI, C. M. et al. A polymerase chain reaction for detection of equine herpesvirus-1 in routine diagnostic submissions of tissues from aborted fetuses. **Journal**

of Veterinary Medicine B, v. 48, n. 5, p. 341-346, 2001.

2 MUMFORD, J. A.; EDINGTON, N. EHV-1 and equine paresis. **Veterinary Record**, v. 106, n. 12, p. 277, 1980.

- 3 ALLEN, G. P. Respiratory infections by equine herpesvirus types 1 and 4. In: LEKEUX, P. (Ed.). **Equine respiratory diseases**. New York: International Veterinary Information Service, 2002. Disponível em: <<http://www.ivis.org>. Document No. B0323.0202>. Acesso em: 28 jan. 2008.
- 4 VAN MAANEN, C. Equine herpesvirus 1 and 4 infections: an update. **Veterinary Quarterly**, v. 24, n. 2, p. 57-78, 2002.
- 5 NUGENT, J.; BIRCH-MACHIN, I.; SMITH, K. C.; MUMFORD, J. A.; SWANN, Z.; NEWTON, J. R.; BOWDEN, R. J.; ALLEN, G. P.; DAVIS-POYNTER, N. Analysis of equid herpesvirus 1 strain variation reveals a point mutation of the DNA polymerase strongly associated with neuropathogenic versus nonneuropathogenic disease outbreaks. **Journal of Virology**, v. 80, n. 8, p. 4047-4060, 2006.
- 6 STUDDERT, M. J.; HARTLEY, C. A.; DYNON, K.; SANDY, J. R.; SLOCOMBE, R. F.; CHARLES, J. A.; MILNE, M. E.; CLARKE, A. F.; EL-HAGE, C. Outbreak of equine herpesvirus type 1 myeloencephalitis: new insights from virus identification by PCR and the application of an EHV-1-specific antibody detection ELISA. **Veterinary Record**, v. 153, n. 14, p. 417-423, 2003.
- 7 ALLEN, G. P. Antemortem detection of horses latently infected with neuropathogenic strains of equine herpesvirus-1 in horses. **American Journal of Veterinary Research**, v. 67, n. 8, p. 1401-1405, 2006.
- 8 HENNINGER, R. W.; HENNINGER, R. W.; REED, S. M.; SAVILLE, W. J.; ALLEN, G. P.; HASS, G. F.; KOHN, C. W.; SOFALY, C. Outbreak of neurologic disease caused by equine herpesvirus-1 at a university equestrian center. **The Journal of Veterinary Internal Medicine**, v. 21, n. 1, p. 157-165, 2007.
- 9 SAFEGUARDING AMERICAN AGRICULTURE VETERINARY SERVICES CENTERS FOR EPIDEMIOLOGY AND ANIMAL HEALTH. **Equine herpesvirus myeloencephalopathy**: a potentially emerging disease. APHIS Info Sheet. Jan. 2007. Disponível em: <http://www.aphis.usda.gov/vs/ceah/cei/taf/emergingdiseasenotice_files/ehv1final.pdf>. Acesso em: 04 set. 2008.
- 10 DINTER, Z.; KLINGEBORN, B. Serological study of an outbreak of paresis due to equine herpesvirus 1 (EHV-1). **Veterinary Record**, v. 99, n. 1, p. 10-12, 1976.
- 11 THOMSON, G. W.; MCCREADY, R.; SANFORD, E.; GAGNON, A. Case report: an outbreak of herpesvirus myeloencephalitis in vaccinated horses. **Canadian of Veterinary Journal**, v. 20, n. 1, p. 22-25, 1979.
- 12 VAN MAANEN, C.; VAN MAANEN, C.; SLOET VAN OLDRUITENBORGH-OOSTERBAAN, M. M.; DAMEN, E. A.; DERKSEN, A. G. Neurological disease associated with EHV-1-infection in a riding school: clinical and virological characteristics. **Equine Veterinary Journal**, v. 33, n. 2, p. 191-196, 2001.
- 13 WILSON, W. D. Equine herpesvirus 1 myeloencephalopathy. **Veterinary Clinical of North American Equine Practice**, v. 13, n. 1, p. 53-72, 1997.
- 14 GOEHRING, L. S.; VAN MAANEN, C.; SLOET VAN OLDRUITENBORGH-OOSTERBAAN, M. M. Neurological syndromes among horses in the Netherlands. A 5 years retrospective survey (1999-2004). **Veterinary Quarterly**, v. 27, n. 1, p. 11-20, 2005.
- 15 LARA, M. C. C. S. H.; CUNHA, E. M. S.; VILLALOBOS, E. M. C.; NASSAR, A. F. C.; ASANO, K. M.; FERNANDES, W. R.; RICHTZENHAIN, L. J.; BRANDÃO, P. E.; MORI, E. First isolation of equine herpesvirus type 1 from a horse with neurological disease in Brazil. **Arquivos do Instituto Biológico**, v. 75, n. 2, p. 221-224, 2008.
- 16 MORI, E.; LARA, M. C. C. S. H.; CUNHA, E. M. S.; VILLALOBOS, E. M. C.; NASSAR, A. F. C.; ASANO, K. M.; FERNANDES, W. R.; RICHTZENHAIN, L. J.; BRANDÃO, P. E. Isolamento de herpesvirus equino tipo 1 (HVE-1) a partir do líquido de um cavalo com doença neurológica: primeiro relato no Brasil. **O Biológico**, v. 69, n. 2, p. 116, 2007.
- 17 ROSENTHAL, A.; COUTELLE, O.; CRAXTON, M. Large-scale production of DNA sequencing templates by microtitre format PCR. **Nucleic Acids Research**, v. 21, n. 1, p. 173-174, 1993.
- 18 BOOM, R.; SOL, C. J.; SALIMANS, M. M.; JANSEN, C. L.; WERTHEIM-VAN DILLEN, P. M.; VAN DER NOORDAA, J. Rapid and simple method for purification of nucleic acids. **Journal of Clinical Microbiology**, v. 28, n. 3, p. 495-503, 1990.
- 19 VARRASSO, A.; DYNON, K.; FICORILLI, N.; HARTLEY, C. A.; STUDDERT, M. J.; DRUMMER, H. E. Identification of equine herpesviruses 1 and 4 by polymerase chain reaction. **Australian of Veterinary Journal**, v. 79, p. 563-569, 2001.
- 20 MIKAWA, S.; YOSHIKAWA, G.; AOKI, H.; YAMANO, Y.; SAKAI, H.; KOMANO, T. Dynamic aspects in the expression of the goat insulin-like growth factor-1 (IGF-1) gene: diversity in transcription and post-transcription. **Bioscience Biotechnology and Biochemistry**, v. 59, n. 1, p. 87-92, 1995.
- 21 LUNA, L. G. (Ed.). **Manual of histologic staining methods of the Armed Forces Institute of Pathology**. New York: McGraw-Hill, 1968. 258 p.
- 22 SAMPAIO, I.B.M. **Estatística aplicada à experimentação animal**. 2. ed. Belo Horizonte: FUNDEP-MVZ. Escola de Veterinária da UFMG, 2007. 265 p.
- 23 CARVALHO, R.; OLIVEIRA, A. M.; SOUZA, A. M.; PASSOS, L. M. F.; MARTINS, A. S. Prevalence of equine herpesvirus type 1 latency detected by polymerase chain reaction. **Archives Virology**, v. 145, n. 9, p. 1773-1787, 2000.
- 24 COSTA, E. A.; LIMA, G. B. L.; FURTINI, R.; PORTILHO, R. V.; RESENDE, M.; COSTA, E. A.

- Meningoencephalitis in a horse associated with Equine Herpesvirus 1. **Arquivo Brasileiro de Medicina Veterinária e Zootecnia**, v. 60, n. 6, p. 1580-1583, 2008.
- 25 NILSSON, M. R.; CORREA, W. M. Isolamento do vírus do aborto eqüino no Estado de São Paulo. **Arquivos do Instituto Biológico**, v. 33, n. 2, p. 23-25, 1966.
- 26 CARVALHO, F. S. R.; COELHO, H. E.; BEDAQUE, M. Aborto eqüino por herpesvirus eqüi 1. **Revista do Centro de Ciências Biomédicas da Universidade Federal de Uberlândia**, v. 7, p. 45-47, 1991.
- 27 CUNHA, E. M. S.; DE FERRARI, C. I.; LARA, M. C. S. H.; SILVA, L. H. Q. Presença de anticorpos contra o herpesvirus eqüino 1 (HVE-1) em eqüinos no noroeste do estado de São Paulo. **Arquivos do Instituto Biológico**, v. 69, n. 1, p. 1-5, 2002.
- 28 DIEL, D. G.; ALMEIDA, S. R.; WEIBLEN, R.; FRANDOLOSO, R.; ANZILIERO, D.; KREUTZ, L. C.; GROFF, F. H. S.; FLORES, E. F. Prevalência de anticorpos contra os vírus da influenza, da arterite viral e herpesvírus em eqüinos do estado do Rio Grande do Sul, Brasil. **Ciência Rural**, v. 36, n. 5, p. 1467-1673, 2006.
- 29 CHARLTON, K. M.; MITCHELL, D.; GIRARD, A.; CORNER, A. H. Meningoencephalomyelitis in horses associated with equine herpesvirus 1 infection. **Veterinary Pathology**, v. 13, n. 1, p. 59-68, 1976.
- 30 SPILKI, F. R.; ESTEVES, P. A.; FRANCO, A. C.; LIMA, M.; HOLZ, C. L.; BATISTA, H. B. R.; DRIEMEIER, D.; FLORES, E. F.; WEIBLEN, R.; ROEHE, P. M. Neurovirulência e neuroinvasividade de herpesvírus bovinos tipo 1 e 5 em coelhos. **Pesquisa Veterinária Brasileira**, v. 22, n. 2, p. 58-63, 2002.
- 31 WELCH, H. M.; BRIDGES, C. G.; LYON, A. M.; GRIFFITHS, L.; EDINGTON, N. Latent equid herpesviruses 1 and 4: detection and distinction using the polymerase chain reaction and co-cultivation from lymphoid tissues. **Journal of General Virology**, v. 73, n. 2, p. 261-268, 1992.
- 32 FURR, M.; REED, S. **Equine neurology**. Seiten: Blackwell Science, 2007. 432 p.
- 33 PAIXÃO, T. A.; RÉGO, I. O. P., SANTOS, R. L. Anti-*Sarcocystis neurona* immunostaining associated with equine protozoal myeloencephalitis in Brazil. **Ciência Rural**, v. 37, n. 6, p. 1820-1823, 2007.
- 34 OLSEN, T. F. Equine herpesvirus myeloencephalopathy in a 14-year-old quarter horse stallion. **Canadian of Veterinary Journal**, v. 42, n. 3, p. 217-220, 2001.