Autopsy and Case Reports 2012;2(1):19-23

Article / Autopsy Case Report
Artigo / Relato de Caso de Autópsia

"Nutrothorax" complicating a misplaced nasogastric feeding tube in a severely ill patient

Aloísio Felipe-Silva[a], Fernando Peixoto Ferraz de Campos[b]

Felipe-Silva A, Campos FPF. "Nutrothorax" complicating a misplaced nasogastric feeding tube in a severely ill patient. Autopsy Case Rep [Internet]. 2012;2(1):19-23. http://dx.doi.org/10.4322/acr.2012.003

ABSTRACT

Introduction of nasogastric feeding tubes is usually blindly performed and is generally considered a safe procedure. However, the rate of complications of a blind insertion technique varies from 0.3 to 15%, and is usually related to inadvertent insertion of nasogastric tubes into the trachea and distal airways. The main predisposing factors related to tube malpositioning and complications are altered mental status with decreased cough or gag reflex, a preexisting endotracheal tube and severe illness. Complications include severe aspiration pneumonia, hydrothorax, hemothorax, empyema and pneumothorax. The mortality related to misplacement of a nasogastric tube is around 0.1-0.3% of the procedures. This 61-year old female had a history of poor appetite, weight loss, dyspnea and fever. A chest axial computerized tomography showed enlarged mediastinal lymph nodes. Laboratory showed hypercalcemia with normal PTH and hypokalemia. As the patient remained anorectic, a nasogastric feeding tube was placed, through which the administration of enteral diet, by continuous infusion pump, was started. After 12 hours the patient developed dyspnea, hypoxemia and hypotension. During orotracheal intubation, it was disclosed the presence of the nasogastric tube in the trachea as well as the infused diet within the respiratory tract. Autopsy revealed an unusual complication of a nasogastric tube misplacement, which led to a massive collection of enteral nutrition fluid into the pleural space – a "nutrothorax". Additionally, an underlying stage IV anaplastic large cell lymphoma with interstitial lung and bronchial mucosa involvement was diagnosed.

Keywords: Enteral Nutrition; Lymphoma, Non-Hodgkin; Pleural Effusion; Hydrothorax; Autopsy

CASE REPORT

A 61-year old female patient sought medical attention complaining of poor appetite and weight loss during the last 3 weeks. She referred malaise, a recent onset of dyspnea and fever during the last 5 days. She denied any other gastrointestinal, genitourinary or respiratory symptoms. The patient has been paraplegic of unknown cause since the age of 32 and was a mild smoker.

Physical examination upon admission revealed a drowsy, weakened, pale, lightly emaciated, dehydrated and feverish patient.

[a] Anatomic Pathology Service - Hospital Universitário - Universidade de São Paulo - São Paulo/SP – Brazil.
[b] Department of Internal Medicine - Hospital Universitário - Universidade de São Paulo - São Paulo/SP – Brazil.

Copyright © 2012 **Autopsy and Case Reports** – This is an Open Access article distributed of terms of the Creative Commons Attribution Non-Commercial License (http://creativecommons.org/licenses/by/3.0/) which permits unrestricted non-commercial use, distribution, and reproduction in any médium provided article is properly cited.

Room air oxygen saturation reading was 86% and respiratory rate was 8 movements per minute. The pulse rate was 80 beats per minute and blood pressure was 90 × 60 mmHg. Mild edema was evidenced on the lower limbs. She had pressure ulcers in sacral, pelvic and trochanteric regions with apparent infection signs on the latter. Remainder physical and neurological examination was unremarkable. Capillary blood glucose was 147 $mg.dL^{-1}$.

The chest X-ray showed a small bilateral pleural effusion and the electrocardiogram was within the normal limits. Initial laboratory tests showed mild anemia, moderate leukocytosis, hypercalcemia and hypokalemia (Table 1).

The chest axial computerized tomography showed enlarged mediastinal lymph nodes (greater than 2.4 cm in its longest axis) in the right para-aortic chain, hilar and carinal regions, as well as in the aortopulmonary window; moderate pleural effusion and associated restrictive bilateral atelectasis.

The patient was admitted with diagnoses of hypercalcemia with normal PTH, hypokalemia and mediastinal lymphadenopathy. Fever was attributed to an underlying lymphadenopathy (suspected lymphoma) and possibly to a secondary infection of pressure ulcers. Hypercalcemia was initially treated with intravenous saline hydration and furosemide, followed by pamidronate administration.

On the third day of hospitalization, as the patient remained anorectic, a standard silastic nasogastric feeding tube was blindly placed, through which the administration of enteral diet was started by a continuous infusion pump. This kind of feeding tube has a covered metal stylet on the tip. Introduction of the feeding tube was blindly performed and uneventful. The verification of tube placement was clinically evaluated by auscultation of the epigastric area while insufflating air through the tube. After 12 hours of the diet administration the patient developed dyspnea, hypoxemia and hypotension, demanding mechanical ventilatory support. During orotracheal intubation, it was disclosed the presence of the nasogastric tube in the trachea as well as the infused diet within the respiratory tract. The patient progressed rapidly to cardiopulmonary arrest unresponsive to cardiopulmonary resuscitation. An autopsy was required.

Autopsy Findings

A massive right sided, pinkish and milky pleural effusion (about 1000 mL) was noted (Figure 1), accompanied by right lung collapse and extensive exudative pleuritis. Right main bronchus

Table 1 – Laboratory tests

		RV			RV
Hemoglobin	11.5	12.3-15.3 g%	iCa	2.4	1.1-1.4 $mmol.L^{-1}$
Hematocrit	36	36.0-45.0%	tCa	14.5	8.6-10.0 $mg.dL^{-1}$
MCV	82	80-96 fL			
MCH	32	27.5-33.2pg	BUN	16	5-25 $mg.dL^{-1}$
RDW	18.2	11-16%	Creatinine	1.1	0.4-1.3 $mg.dL^{-1}$
Leukocytes	16600	4.4-11.3 $10^3/mm^3$			
Mielocytes	6	0%	Sodium	143	136-146 $mEq.L^{-1}$
Bands	4	1-5%	Potassium	2.7	3.5-5.0 $mEq.L^{-1}$
Segmented	27	45-70%			
Eosinophils	1	1-4%	ALT	13	9-36 U/L
Basophils	0	0-2.5%	AST	105	10-31 U/L
Linfocytes	44	18-40%	Albumin	2.16	3-5 $g.dL^{-1}$
Monocytes	18	2-9%	TSH	1.64	0.5-4.7 $mcUI.L^{-1}$
Platelets	157.10^3	150-400 $10^3/mm^3$	PTH	16	10-65 $pg.mL^{-1}$

ALT = alanine aminotransferase, AST = aspartate aminotransferase, BUN = blood urea nitrogen, iCa = ionized calcium, MCH = mean corpuscular hemoglobin, MCV = mean cospuscular volume, PTH = parathyroid hormone, RDW = red cell distribution width, tCa = total calcium, TSH = thyroid stimulating hormone, RV = reference value.

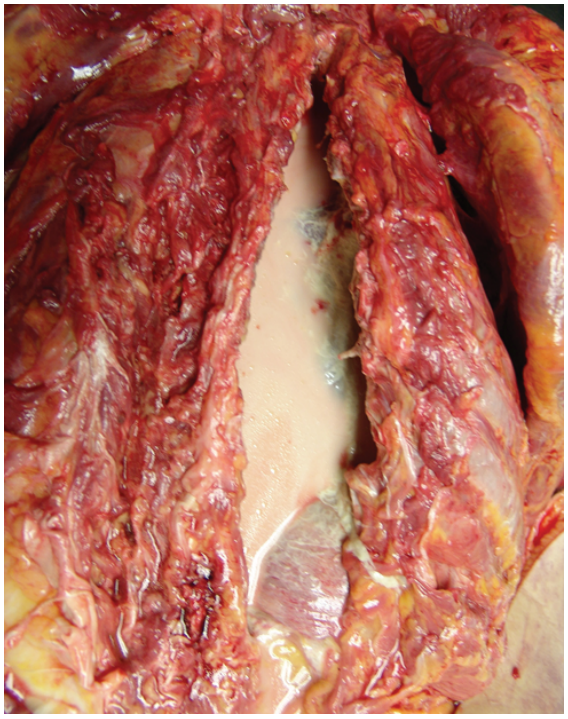

Figure 1 – Autopsy posterior view of the thoracic cavity. Note the milky enteral nourishment fluid covering almost all pleural surfaces. Diaphragm is seen in the bottom.

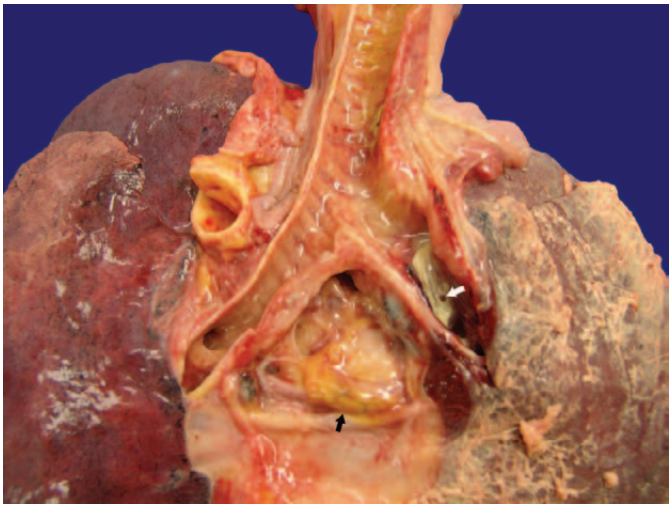

Figure 2 – Autopsy posterior view of trachea and main bronchi (opened). Note puncture lesion at the right main bronchus (white arrow) and inflamed background mucosa and right lung pleuritis. Note enlarged carinal lymph node (black arrow).

examination depicted a puncture lesion within an inflamed background mucosa (Figure 2). This was consistent with a lesion caused by the nasogastric feeding tube.

Multiple enlarged (up to 3.0 cm), partially necrotic and confluent lymph nodes were detected in the para-aortic chain, hilar and carinal regions (Figure 2). Enlarged (up to 2.0 cm) and partially necrotic lymph nodes were also detected in abdominal para-aortic, peripancreatic and retroperitoneal regions.

Microscopic examination revealed lymph node architecture effacement by solid sheets of pleomorphic cells with horse-shoe or kidney-shaped nuclei in a necrotic and inflammatory background (Figure 3A). Immunostaining was diffusely positive for CD3 (Figure 3C) and CD30 (Figure 3D) and focally positive for CD56, CD4 and CD5. Immunostains for ALK, EMA, CD20, CD8 and EBV were negative. Cell proliferation index by Ki67 was 90%. These findings were consistent with an ALK-negative anaplastic large cell lymphoma (ALCL).

Spleen and bone marrow were diffusely infiltrated by ALCL. There were also multiple microscopic foci of interstitial infiltration in the liver, lungs, bronchial mucosa (Figure 3B) and kidneys. Microscopic examination of the right lung showed edema, congestion and focal foreign body giant cell reaction. Left lung showed only moderate congestion.

DISCUSSION

Introduction of nasogastric feeding tubes is usually blindly performed and is considered a very safe procedure in awake patients.[1] The placement of a nasogastric tube is usually evaluated by aspirating fluid from the proximal port or insufflating air while auscultating the epigastric area. However, both these physical examination based techniques may fail to detect tube malpositioning. Radiological confirmation of tube positioning is considered the gold standard method.[2]

The rate of complications of a blind insertion technique varies from 0.3 to 15%.[1] and is usually related to inadvertent insertion of nasogastric tubes into the trachea and distal airways. Severe aspiration pneumonia, hydrothorax, hemothorax, empyema and delayed pneumothorax have been described as complications of releasing chemicals into the lungs and pleural spaces.[3-6] Rarely, there may be penetration into the pleural cavity, which is a potentially lethal complication. Actually, the mortality related to misplacement of a nasogastric tube is around 0.1-0.3%.[1,7] Haas and colleagues have

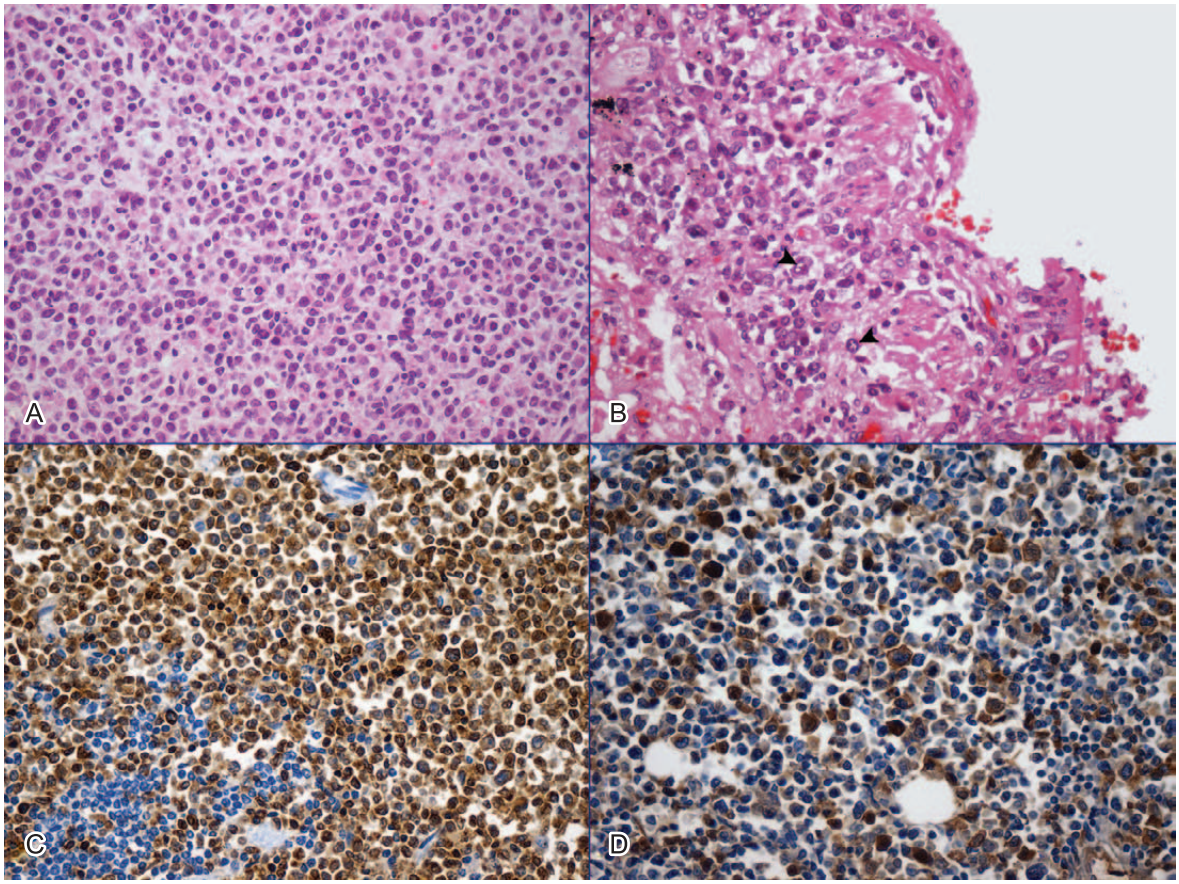

Figure 3 – Anaplastic large cell lymphoma (**A**) with bronchial mucosa infiltration (**B**) – Hematoxilin and Eosin (400×). Immunostaining were positive for CD3 (**C**) and CD30 (**D**) – (400×).

coined the term "nutrothorax" to name the collection of enteral nutrition fluid in the pleural space.[8]

The main predisposing factors related to tube malpositioning and complications are altered mental status with decreased cough or gag reflex, a preexisting endotracheal tube and severe illness. The bore and rigidity of the nasoenteral feeding tube are also related to the incidence of complications. The placement of large-bore nasogastric tubes in patients under general anesthesia is less frequently associated with the overwhelming bronchopulmonary complications observed with small-bore tubes in critically ill patients.[1]In fact, in Odocha series of tracheopleuropulmonary injuries following enteral feeding tube insertion, 14% of the patients had advanced cancer or other terminal state.[7]

The peak incidence of ALK-negative ALCL is in adults, with a modest male predominance (1.5:1).[9] Most patients present with advanced stage III or IV disease, with peripheral and/or abdominal lymphadenopathy and B symptoms, with an overall 5-year survival less than 45%.[10]

This patient had a stage IV ALCL with some interstitial lung and bronchial mucosa involvement. She also had an altered mental status (drowsiness), although consciousness level was preserved. Ishigami et al described an autopsy case in which the pleural misinsertion of a nasogastric feeding tube was attributed to an increased fragility in a lung with pneumonia. They also found multinucleated giant cells in pleural exudate and in lung parenchyma that most likely appeared because of a foreign body reaction against the nourishment material.[11]

No previous significant primary pleuropulmonary disease was seen at this autopsy. However, one could hypothesize that multifocal interstitial infiltration by ALCL could have increased mucosal and parenchymal fragility, thus predisposing to lung perforation by a misplaced feeding tube.

In summary, this case illustrates an unusual and dramatic presentation of nasogastric tube misplacement complications in a severely ill patient. Clinical and nurse staff should keep alert with respect to the nasogastric tube position. A 2-step radiological confirmation approach is advised when placing small-bore nasoenteral tubes in critically ill

patients.[1]Simple bedside tests are unreliable in this setting and careful imaging confirmation should become the standard of care.

ACKNOWLEDGEMENTS

We are grateful to Rosa Maria C. Zanardi for the technical support on the visual work.

REFERENCES

1. Halloran O, Grecu B, Sinha A. Methods and complications of nasoenteral intubation. JPEN J Parenter Enteral Nutr. 2011;35(1):61-6. PMid:20978245. http://dx.doi.org/10.1177/0148607110370976

2. Marderstein EL, Simmons RL, Ochoa JB. Patient safety: effect of institutional protocols on adverse events related to feeding tube placement in the critically ill. J Am Coll Surg. 2004;199(1):39-47. PMid:15217627. http://dx.doi.org/10.1016/j.jamcollsurg.2004.03.011

3. Torrington KG, Bowman MA. Fatal hydrothorax and empyema complicating a malpositioned nasogastric tube. Chest. 1981;79(2):240-2. PMid:7460662. http://dx.doi.org/10.1378/chest.79.2.240

4. Miller KS, Tomlinson JR, Sahn SA. Pleuropulmonary complications of enteral tube feedings. Two reports, review of the literature, and recommendations. Chest. 1985;88(2):230-3. PMid:3926393. http://dx.doi.org/10.1378/chest.88.2.230

5. Sabga E, Dick A, Lertzman M, Tenenbein M. Direct administration of charcoal into the lung and pleural cavity. Ann Emerg Med. 1997;30(5):695-7. http://dx.doi.org/10.1016/S0196-0644(97)70090-8

6. Kawati R, Rubertsson S. Malpositioning of fine bore feeding tube: a serious complication. Acta Anaesthesiol Scand. 2005;49(1):58-61. PMid:15675983. http://dx.doi.org/10.1111/j.1399-6576.2005.00508.x

7. Odocha O, Lowery RC, Mezghebe HM, Siram SM, Warner OG. Tracheopleuropulmonary injuries following enteral tube insertion. J Natl Med Assoc. 1989;81(3):275-81. PMid:2496234. PMCid:2571629.

8. Haas LE, Tjan DH, van Zanten AR. 'Nutrothorax' due to misplacement of a nasogastric feeding tube. Neth J Med. 2006;64(10):385-6. PMid:17122457.

9. Mason DY, Harris NL, Delsol G, et al. Mature T – and NK-cell neoplasms. Anaplastic large cell lymphoma, ALK-negative. In: Swerlow SH, Campo E, Harris NL, et al., editors. WHO Classification of Tumours of Haematopoietic and Lymphoid Tissues. Lyon: IARC; 2008. p. 317-9.

10. ten Berge RL, de Bruin PC, Oudejans JJ, Ossenkoppele GJ, van der Valk P, Meijer CJ. ALK-negative anaplastic large-cell lymphoma demonstrates similar poor prognosis to peripheral T-cell lymphoma, unspecified. Histopathology. 2003;43(5):462-9. PMid:14636272. http://dx.doi.org/10.1046/j.1365-2559.2003.01726.x

11. Ishigami A, Kubo S, Tokunaga I, Gotohda T, Nishimura A. An autopsy case of severe pleuritis induced by misinsertion of a nasogastric nourishment tube: diagnostic significance of multinucleated giant cells. Leg Med (Tokyo). 2009;11(4):191-4. PMid:19362870. http://dx.doi.org/10.1016/j.legalmed.2009.02.065

Conflict of interest: None

Submitted on: 16th February 2012
Accept on: 1st March 2012

Correspondence: Serviço de Anatomia Patológica
Av. Prof. Lineu Prestes, 2565 – Cidade Universitária - São Paulo/SP – Brazil
CEP: 05508-000 – Phone: +55 (11) 3091-9379.
E-mail: aloisiosilva@hu.usp.br