

Anatomopathological findings in captive-raised red-winged tinamou (*Rhynchotus rufescens*)

Achados anatomopatológicos em perdizes (Rhynchotus rufescens) criadas em cativeiro

Claudia MOMO¹; Eduardo GARRIDO²; Karin WERTHER³

¹ Universidade de São Paulo, Faculdade de Medicina Veterinária e Zootecnia, Departamento de Patologia, São Paulo – SP, Brazil

² Instituto Federal do Norte de Minas Gerais, Salinas – Minas Gerais, Brazil

³ Universidade Estadual Paulista “Júlio de Mesquita Filho”, Faculdade de Ciências Agrárias e Veterinárias, Departamento de Patologia Veterinária, Jaboticabal – SP, Brazil

Abstract

The red-winged tinamou (*Rhynchotus rufescens*), a bird from the Tinamidae family, can be easily adapted to captivity. It is considered suitable for producing good quality meat while presenting great feed conversion rate, characteristics that make it interesting for commercial production. Therefore, in order to determine the major diseases that affect these birds, 114 birds from two different aviary types that died over a 12-year period, 1994-2006, were analyzed macro- and microscopically. Anatomical and pathological examinations showed that the most frequently affected systems were the urinary and digestive tracts. In the urinary tract, the main finding was gout, followed by amyloidosis and parasitism by the trematode *Paratanaisia confusa*. In the digestive tract, the presence of foreign material and parasitism by *Capillaria penidoi* were observed in the esophagus and crop. This study aims to describe the main anatomical and pathological findings in captive-bred red-winged tinamou and correlate them with the aviary type.

Keywords: *Paratanaisia confusa*. *Capillaria penidoi*. Amyloidosis. Uric gout.

Resumo

A perdiz (*Rhynchotus rufescens*) membro da família Tinamidae é uma ave que apresenta relativa facilidade à adaptação ao cativeiro. É considerada apta à produção de carne de boa qualidade, com ótima conversão alimentar. Essas características a torna interessante para produção comercial. Visando conhecer as principais afecções que acometem essas aves, foram analisados achados macro e microscópicos de 114 perdizes que vieram a óbito ao longo de 12 anos, entre 1994 e 2006 provenientes de criatório experimental, mantidas em dois diferentes tipos de recintos. Os exames anatomopatológicos revelaram que os sistemas mais acometidos foram o urinário e o digestório. No primeiro, a gota úrica foi o principal achado, seguida da amiloidose e parasitismo pelo trematoda *Paratanaisia confusa*. No sistema digestório, foi observada a presença de corpo estranho e parasitismo por *Capillaria penidoi* em esôfago e ingluvío. As aves mantidas em alojamento com piso natural apresentaram maior parasitismo, enquanto as que foram mantidas em recinto com piso de concreto e palha apresentaram maior quantidade de corpos estranhos no sistema gastrointestinal, caquexia e amiloidose. O objetivo deste trabalho foi descrever os principais achados anatomopatológicos em perdizes criadas em cativeiro, correlacionando-os com o tipo de recinto adotado.

Palavras-chave: *Paratanaisia confusa*. *Capillaria penidoi*. Amiloidose. Gota úrica.

Introduction

According to official Brazilian data, the number of commercial and conservation-oriented farms that breed red-winged tinamou (*Rhynchotus rufescens*) has increased in recent years and, currently, comprises six farms (IBAMA, 2015). Given the potential of the species for animal husbandry (MORO, 2001), it is important to know the diseases that can hamper its development. There are few published studies concerning the diseases that affect these birds

Correspondence to:

Karin Werther

Universidade Estadual Paulista “Júlio de Mesquita Filho”,
Faculdade de Ciências Agrárias e Veterinárias, Departamento
de Patologia Veterinária

Via de Acesso Prof. Paulo Donato Castellane, s/n
CEP 14884-900, Jaboticabal, São Paulo, SP, Brazil
e-mail: werther@fcav.unesp.br

Received: 17/09/2015

Approved: 15/08/2016

(MARQUES et al., 2012). Among them, a retrospective study of *post-mortem* examinations of red-winged tinamou reported that the urinary system affected by gout was the most frequent (WERTHER, 2003).

Because of increasing interest in commercially breeding the red-winged tinamou and the lack of specific literature, the aim of this study was to determine the macroscopic and microscopic findings observed in captivity-bred birds that died over a twelve-year period and correlate with the type of farm.

Material and Methods

The 114 birds used in this study were raised in two different experimental farms located in two universities in São Paulo State, Brazil, at the FCAV, UNESP in Jaboticabal and FZEA, USP in Pirassununga. The first facility consisted of a shed divided into several stalls of approximately 2 m² each, with cement floor bedded with *Cynodon dactylon* hay. The stalls were separated by 60-cm brick walls and wire fencing with metallic roof and lateral plastic curtain. The stalls were equipped with trough-type feeders and automatic waterers. There were no hiding places or nests. Each stall housed 10 to 12 birds, including males and females. The pelletized feed contained 20% protein and was produced at the university. The animals that died (n = 52) under these conditions comprised the aviary group 1 (AV1). The other facility consisted of stalls separated by screen fencing, with dirt floor where some plants grew, covered with terracotta tiles to protect against rain and sun. The stalls were also equipped with trough feeders and drinkers. The grass bushes worked as hiding places. Each stall housed 10 to 12 male and female birds. The pelleted feed supplied contained 24% protein and was also produced at the university. The animals that died (n = 62) under these conditions formed aviary group 2, AV2.

The animals that died during 1994-2006 were autopsied at the Department of Veterinary Pathology of the FCAV-UNESP, Jaboticabal. Initially, the nutritional status (pectoral musculature and epicardial fat ring) of dead animals was assessed and classified as

adequate, thin or cachectic (MAXIE, 1993). Subsequently, organ samples were collected, fixed in buffered 10% formalin solution and subjected to routine histological techniques using hematoxylin-eosin and Congo red stains to determine the presence of amyloid substance under a polarized light microscope.

For statistical analysis, the results were submitted to Fisher's exact test to determine the association between the lesions and groups AV1 and AV2. There are association when $p < 0,05$. When phi coefficient is positive, the association is positive and there are more animals affected in group AV2; when phi coefficient is negative, the association is negative and animals of AV1 are more affected. Phi coefficient 0,0 to 0,3 is considered a weak association, while 0,4 to 0,7 is moderate, and 0,8 to 1,0 is a strong association.

Results

Regarding the nutritional status, from the 52 birds of AV1 group, 63.5% were considered adequate while 36.5% were thin or cachectic. Of the 62 birds of AV2 group, 68.8% were adequate and 31.2% thin or cachectic.

The macroscopic and microscopic analysis of the several organ systems studied indicated that the digestive and urinary tract were the most affected. The presence of foreign material was observed in the digestive tract while gout and parasitism by *Paratainasia confusa* was the most common condition in the urinary tract. Furthermore, amyloidosis was observed in both digestive and urinary systems (Figure 1). The same animal was often affected by several diseases simultaneously.

There is a positive association, though weak, between groups and the presence of parasitism ($p < 0,0018$ and $\phi = 0,2840$), while the comparison between of the two groups shows that parasitism was observed only in AV2. There is also a weak and positive association between groups and the presence of gout and a weak and negative association between groups and the presence of amyloidosis and foreign materials.

In this case, birds of AV2 were also more often affected by gout while amyloidosis ($p < 0,0086$ and $\phi = -0,2548$) and ingestion of foreign materials ($p < 0,0365$ and $\phi = -0,2024$) were less frequent than AV1. The variety of lesions observed in various organs is summarized in Table 1.

Table 1 – Organs involved and conditions that affected the red-winged tinamou (*Rhynchotus rufescens*) of AV1 and AV2 groups, necropsied – FCAV/UNESP, Jaboticabal (SP) – 2015

Conditions	Organs	AV1	AV2
Foreign matter	Crop	1 (1.5%)	--
	Esophagus	1 (1.5%)	--
	Proventriculus	4 (6.2%)	3 (2.6%)
	Gizzard	9 (13.9%)	--
	Intestine	2 (3.1%)	--
	TOTAL	26.1%	2.6%
Gout	Crop	1 (1.5%)	6 (5.1%)
	Liver	6 (9.2%)	17 (14.5%)
	Pancreas	--	1 (0.9%)
	Kidney	5 (7.7%)	29 (24.7%)
	Oviduct	--	2 (1.8%)
	Air sac	--	3 (2.6%)
	Lung	--	1 (0.9%)
	Heart	5 (7.7%)	21 (17.8%)
	Joints	1 (1.5%)	8 (6.8%)
	TOTAL	27.6%	75.1%
	Amyloidosis	Intestine	3 (4.6%)
Liver		8 (12.3%)	3 (2.6%)
Pancreas		2 (3.1%)	--
Kidney		11 (17.0%)	8 (6.8%)
Heart		3 (4.6%)	1 (0.9%)
Muscles		1 (1.5%)	--
Spleen		2 (3.1%)	1 (0.9%)
TOTAL		46.1%	11.2%
<i>P. confusa</i>	Kidney	--	10 (8.5%)
<i>C. penidoi</i>	Crop	--	3 (2.6%)
	TOTAL LESIONS	65	117

The presence of a foreign material was observed in nine (26.1%) birds of AV1 group and only one (2.9%) animal of AV2. The most frequently observed foreign material was grass stems, usually found in the ventricle and proventriculus, and in the microscopic exam, these areas contain chronic inflammatory cells. Fifty percent of the birds with foreign material in the digestive tract had perforations in the ventricle and proventriculus (Figure 2). Of the birds with foreign material, 50% were cachectic.

Gout was more often observed in the birds of AV2 group, especially in the kidneys. Amyloidosis was more prevalent in AV1 compared to AV2, while the kidney was the most affected organ. Renal and gastrointestinal parasitism by the trematode *Paratanaisia confusa* and the nematode *Capillaria penidoi*, respectively, was observed only in animals of AV2 group. Figure 3 shows the animals of AV1 and AV2 groups and the several diseases that were sometimes found in the same animal.

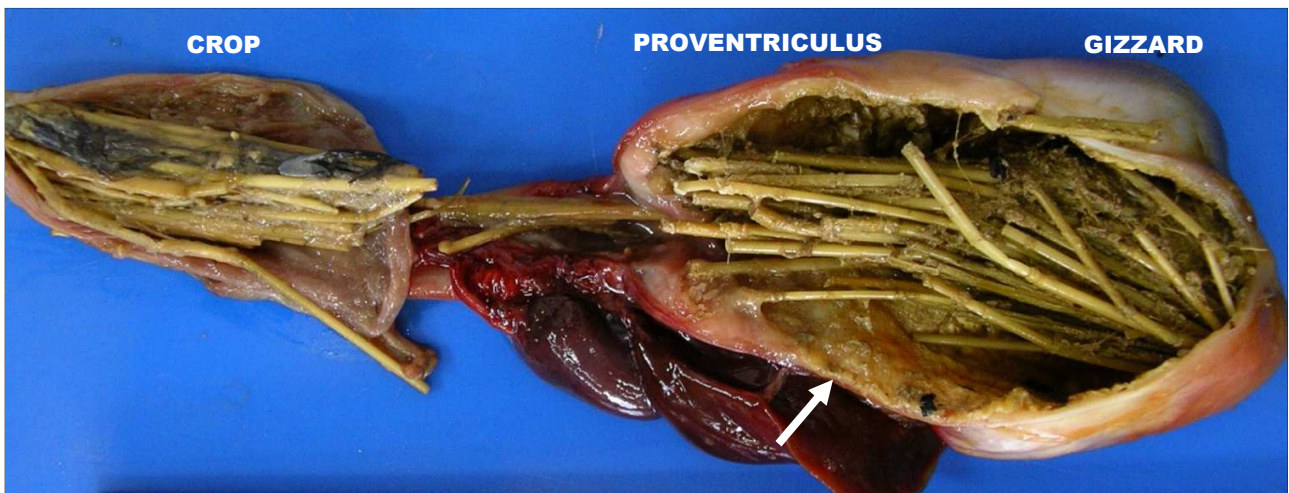


Figure 2 – Organs from a tinamou in AV1: crop, proventriculus, and gizzard containing various grass stems. Note that the isthmus (arrow) remains open

The comparison of the two diagrams shows that AV1 birds with foreign material also had amyloidosis and gout while AV2 birds with foreign material had no correlation with other

conditions. Birds with kidney parasite, observed only in AV2 group, were also affected by amyloidosis and gout.

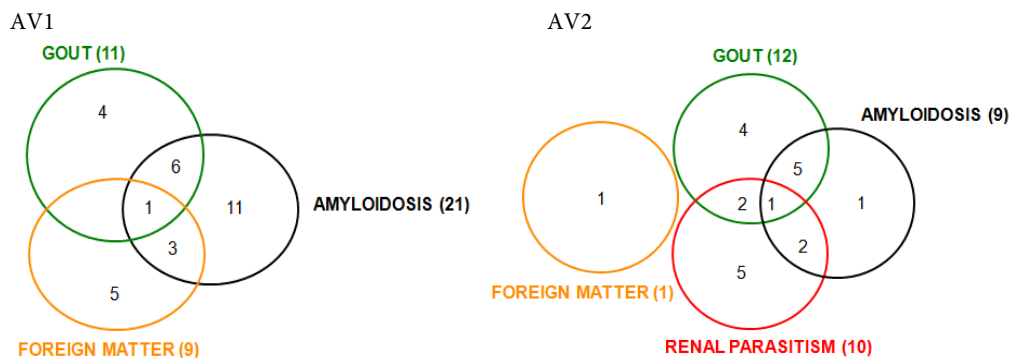


Figure 3 – Two diagrams illustrating the primary conditions and the number of tinamou affected by each in AV1 and AV2 in a study carried out – FCAV/UNESP, Jaboticabal (SP) – 2015

Discussion

The macro and microscopic analysis of organs during necropsy of red-winged tinamou showed the presence of systemic disorders (amyloidosis and gout) affecting various organs, as well as conditions that were restricted to certain organs (foreign material, kidney and gastrointestinal parasite).

Amyloidosis, an example of systemic disease, was observed in both groups. The AA amyloid (associated

amyloid) is synthesized from the precursor SAA protein (serum amyloid A), secreted by the liver. SAA concentrations increase in cases of inflammation or chronic diseases (MYERS et al., 2012), in birds with parasitic enteritis, old birds, and birds subjected to social stress (MEYERHOLZ et al., 2005). Among the birds with amyloidosis, 72.4% had chronic inflammation in multiple organs, suggesting a link between these and amyloid formation, similar to that described in the literature (MAXIE, 1993). Parasitism

by *Capillaria penidoi*, considered a chronic inflammatory process (MAPELI, 2001), may be responsible for the amyloidosis observed in tinamou in this work. Likewise, the chronic inflammatory lesions of the gastrointestinal mucosa caused by foreign material may interact with amyloidosis, although this association has not been mentioned in the literature.

Another example of a systemic condition was gout, which occurred more often in birds of AV2 compared to AV1 ($\phi = 0,3130$). Gout is more a sign of renal failure than a distinct disease (LIERZ, 2003). The multifactorial origin of gout includes nutritional factors, nephropathies, infectious and toxic processes (OROSZ et al., 1997). Crude protein percentages contained in the diet supplied to the birds were 24% and 20% in AV2 and AV1, respectively, suggesting that this may be one of the causes of gout in birds, as has been stated in the literature (LUMEIJ, 1994a; GOODMAN, 1996). Since the causes of gout are water shortages and excessive heat, gout was discarded with these animals as they were housed in a controlled environment. As causes of gout were discarded water shortages and excessive heat, as the animals were housed in a controlled environment.

The digestive system and the urinary tract were the most affected by non-systemic conditions. The digestive system had the presence of foreign materials and parasitism by *Capillaria penidoi*. Foreign materials, such as grass stems from the substrate, were observed more in AV1 birds, respectively. The birds of AV2 group were housed in dirt-floored stalls where grass clumps were used as hiding places. These data suggest that environmental (the lack of hiding places) and social stress associated with grass availability favored its intake (KINSEL et al., 2004). This behavior is common among tinamou (MARQUES, 2014) due to several factors, including parasitism, nutritional deficiency (vitamin/fibers), overcrowding and food scarcity (MORISHITA et al., 1993). The consequences are traumatic injuries, including perforation of the digestive tract (KINSEL et al., 2004), which was also observed in 50% of birds in this study. Cachexia

observed in 50% of affected birds may be caused by dysphagia, anorexia and regurgitation (LUMEIJ, 1994b; MORRISEY, 1999; SCHMIDT, 1999), in addition to the action of the foreign material in the site, which impeded normal organ function (KINSEL et al., 2004). In this study, 77.7% of the cachectic birds had foreign material in the gastrointestinal tract. Another cause of cachexia was parasitism by *Capillaria penidoi* (2.1%) in the crop and esophagus, observed only in AV2 birds, which may be responsible for lower feed efficiency (MAPELI, 2001). The same author stated that capillariasis occurs more frequently in tinamou reared in stalls with dirt floors, as observed in this work. Amyloidosis, generated by chronic inflammation, was diagnosed in 38.5% of the birds with foreign material (RIDDELL, 1987).

The most common conditions diagnosed in the urinary system were gout, infestation by the trematode *Paratanaisia confusa* and amyloidosis. The red-winged tinamou *Rhynchotus rufescens* is parasitized by both *P. confusa* (MAPELI et al., 2003) and *P. robusta* (NASCIMENTO; ARANTES, 2001) and the first species requires intermediate hosts, such as slugs and snails (BRANDOLINI et al., 1997; GOMES et al., 2005). *P. confusa* was diagnosed in birds of AV2 group, which were housed in dirt-floored stalls with grass, where environmental recontamination and the presence of intermediate hosts are favored. Furthermore, the birds of AV1 group, which were housed in stalls with concrete floor, did not show this parasitism. The parasites were observed in the lumen of the collecting ducts/tubules, where they can cause obstruction (GOMES et al., 2005). In 50% of the parasitized birds, the observed mixed local inflammatory reaction may have stimulated the production of amyloids, which build up and compromise the functioning of various organs. On the other hand, the parasite presence leads to a compensatory dilation of the collecting duct in such way that the urine is no longer retained (PINTO et al., 2004). Although this parasite's pathogenicity is considered low (21 and 22), in this study, 20% of the

parasitized birds also had gout, another 20% had amyloidosis, and 10% were affected by both conditions. This suggests a possible direct relationship between parasitism and secondary renal lesions.

The birds of AV2 were also parasitized by *Paratainasia confusa*, and this may be considered another factor that predisposes the birds for gout. Recent studies in humans (DEHGHAN et al., 2008) have reported the involvement of genes in the development of gout, which might be occurring in these animals, as they are bred intensively since 1987 from a few animals from Rio Grande do Sul State (QUEIROZ, 2003). Of the 23 birds with gout, 13 (56.5%) also had amyloidosis. A similar result has been reported for the Chilean Flamingo (*Phoenicopterus chilensis*), in which gout was observed secondary to renal amyloidosis (CAMUS et al., 2002). In severe renal impairment, the amyloid interferes with tubular reabsorption and uric acid secretion, resulting in systemic gout (CASSONE; PHALEN, 2002). The affected organ dysfunction occurs due to compression of the tissue by the deposition of extracellular protein. The same mechanism may be responsible for renal ischemia that can lead to hyperuricemia with systemic deposition of uric acid crystals (LUMEIJ, 1994a). The literature suggests that the renal glomeruli are the primary site for amyloid deposition in the kidney (MAXIE, 1993; MYERS et al., 2012). However, in this study, significant interstitial amyloid deposition was observed on the interstitium and on the kidney vessel wall while a modest amount was observed in the glomeruli.

Another factor that may induce amyloidosis is the environmental stress to which birds kept and bred in captivity are subjected (RIDDELL, 1987). One study (OLSEN, 1994) in the literature suggests that amyloidosis in domesticated Anseriformes resulting from social stress caused lesions in the liver, spleen, adrenal, kidney, intestine, heart and lung. Since the birds of the present study are from experimental aviaries and, therefore, used for various research projects concerning reproduction traits (MORO et al., 2000), behavior (THOLON, 2002), among others, it is possible that the stress arising from social and environmental intensive management could have favored the development of amyloidosis.

Given the results presented and the different stall characteristics where the birds were raised, it can be stated that dirt-floored stalls with hiding points and no bedding (AV2) minimize foreign material ingestion, but favor parasitism. On the other hand, the cement floor (AV1) stalls prevent parasitism, but favor the ingestion of foreign material. The higher population density in AV1 and social stress may have also caused higher occurrence of amyloidosis. Therefore, these results identify conditions and management techniques that minimize undesirable effects while respecting the biology and natural behavior of the studied species.

Ethical Approval: The experimental protocol was approved by the University's Ethics Committee (n.27229/12).

References

- BRANDOLINI, S. V. P.; AMATO, S.; PEREIRA, A. A. Relacionamento de *Tanaisia bragai* (Digenea, Eucotylidae) e seu hospedeiro intermediário, *Subulina octona* (Gastropoda, Subulinidae) sob condições experimentais. **Parasitologia al Día**, v. 21, n. 3-4, p. 109-113, 1997. doi: 10.4067/S0716-07201997000300008.
- CAMUS, A.; ROBERTS, C.; HEATLEY, J. J.; PIRIE, G. What is your diagnosis? **Journal of Avian Medicine and Surgery**, v. 16, n. 1, p. 69-71, 2002. doi: 10.1647/1082-6742(2002)016[0069:WIYD]2.0.CO;2.
- CASSONE, L. M. C.; PHALEN, D. N. Avian pathology challenge. **Journal of Avian Medicine and Surgery**, v. 16, n. 1, p. 65-68, 2002. doi: 10.1647/1082-6742(2002)016[0065:APC]2.0.CO;2.
- DEHGHAN, A.; KÖTTGEN, A.; YANG, Q.; HWANG, S. J.; KAO, W. H. L.; RIVADENEIRA, F.; BOERWINKLE, E.; LEVY, D.; HOFMAN, A.; ASTOR, B. C.; BENJAMIN, E. J.; DUIJN, C. M.; WITTEMAN, J. C.; CORESH, J.; FOX, C. S. Association of three genetic loci with uric acid concentration and risk of gout: a genome-wide association study. **The Lancet**, v. 372, n. 9654, p. 1953-1961, 2008. doi: 10.1016/S0140-6736(08)61343-4.
- GOMES, D. C.; MENEZES, R. C.; TORTELLY, R.; PINTO, R. M. Pathology and first occurrence of the kidney trematode *Paratanaisia bragai* (Santos, 1934) Freitas, 1959 (Digenea, Eucotylidae) in *Phasianus colchicus* L., 1758 from Brazil. **Memórias do Instituto Oswaldo Cruz**, v. 100, n. 3, p. 285-288, 2005. doi: 10.1590/S0074-02762005000300013.
- GOODMAN, G. J. Metabolic disorders. In: ROSSKOPF, W.; WOERPEL, R. (Ed.). **Diseases of cage and aviary birds**. 3rd ed. Philadelphia, PA: Williams & Wilkins, 1996. p. 477-478.
- INSTITUTO NACIONAL DO MEIO AMBIENTE E DOS RECURSOS NATURAIS RENOVÁVEIS (IBAMA). **Criadores conservacionistas e mantenedores São Paulo**. 2010.
- KINSEL, M. J.; BRIGGS, M. B.; CRANG, R. F. E.; MURNANE, R. D. Ventricular phytobezoar impaction in three Micronesian kingfishers (*Halcyon cinnamomina cinnamomina*). **Journal of Zoo and Wildlife Medicine**, v. 35, n. 4, p. 525-529, 2004. doi: 10.1638/03-089.
- LIERZ, M. Avian renal disease: pathogenesis, diagnosis, and therapy. **Veterinary Clinics of North America: exotic animal practice**, v. 6, n. 1, p. 29-55, 2003. doi: 10.1016/S1094-9194(02)00029-4.
- LUMEIJ, J. T. Gastroenterology. In: RITCHIE, B.W.; HARRISSON, G. J.; HARRISSON, L. R. (Ed.). **Avian medicine: principles and application**. Lake Worth, FL: Wingers, 1994a. p. 482-521.
- LUMEIJ, J. T. Nephrology. In: RITCHIE, B. W.; HARRISSON, G. J.; HARRISSON, L. R. (Ed.). **Avian medicine: principles and application**. Lake Worth, FL: Wingers, 1994b. p. 538-555.
- MAPELI, E. B. **Infecções naturais por helmintos em perdizes (*Rhynchotus rufescens* Temminck, 1815) de vida livre e de cativeiro, nos estados do Mato Grosso do Sul (sub-região Paiaguás) e de São Paulo**. 2001. 58 f. Dissertação (Mestrado) - Faculdade de Ciências Agrárias e Veterinárias, Universidade Estadual Paulista, Jaboticabal, 2001.
- MAPELI, E. B.; NASCIMENTO, A. A.; SZABÓ, M. P. J.; TEBALDI, J. H. Infecções naturais por helmintos em perdizes (*Rhynchotus rufescens* Temminck 1815) de cativeiro, no município de Jaboticabal, Estado de São Paulo. **Arquivos do Instituto Biológico**, v. 70, n. 4, p. 415-418, 2003.
- MARQUES, M. V. R. Tinamiformes (codorna, inhambu, macuco, jaó e perdiz). In: CUBAS, Z. S.; SILVA, R. C. R.; CATÃO-DIAS, J. L. (Ed.). **Tratado de animais selvagens: medicina veterinária**. 2nd ed. São Paulo: Roca, 2014. p. 303-329.
- MARQUES, M. V. R.; FERREIRA JUNIOR, F. C.; ANDERY, D. A.; FERNANDES, A. A.; ARAÚJO, A. V.; RESENDE, J. S.; DONATTI, R. V.; MARTINS, N. R. S. Health assessment of captive tinamids (Aves, Tinamiformes) in Brazil. **Journal of Zoo and Wildlife Medicine**, v. 43, n. 3, p. 539-548, 2012. doi: 10.1638/2011-0262R1.1.
- MAXIE, G. M. The urinary system. In: JUBB, K. V. F.; KENNEDY, P. C.; PALMER, N. (Ed.). **Pathology of domestic animals**. 4th ed. San Diego, CA: Academic Press, 1993. p. 447-538.
- MEYERHOLZ, D. K.; VANLOUBBEECK, Y. F.; HOSTETTER, S. J.; JORDAM, D. M.; FALES-WILLIAMS, A. J. Surveillance of amyloidosis and other diseases at necropsy in captive trumpeter swans (*Cygnus buccinator*). **Journal of Veterinary Diagnostic Investigation**, v. 17, n. 3, p. 295-298, 2005. doi: 10.1177/104063870501700318.
- MORISHITA, T. Y.; AYE, P. P.; HARR, B. S. Crop impaction from feather ball formation in caged layers. **Avian Diseases**, v. 43, n. 1, p. 160-163, 1993. doi: 10.2307/1592777.

- MORO, M. E. G. Red winged tinamou (*Rhynchotus rufescens*) – utilization for meat production. In: FOWLER, M. E.; CUBAS, Z. S. (Ed.). **Biology, medicine and surgery of South American wild animals**. Ames, IA: Iowa State University, 2001. p. 75-76.
- MORO, M. E. G.; TAVARES, F. A.; LIMA, C. G. Desempenho reprodutivo da perdiz (*Rhynchotus rufescens*) submetida a diferentes níveis energéticos na ração. **Revista Brasileira de Ciência Avícola**, v. 2, n. 1, p. 13-18, 2000. doi: 10.1590/S1516-635X2000000100002.
- MORRISEY, J. K. Gastrointestinal diseases of psittacine birds. **Seminars in Avian and Exotic Pet Medicine**, v. 8, n. 2, p. 66-74, 1999. doi: 10.1016/S1055-937X(99)80038-3.
- MYERS, R. K.; MCGAVIN, M. D.; ZACHARY, J. F. Cellular adaptations, injury, and death: morphologic, biochemical, and genetic basis. In: ZACHARY, J. F.; MCGAVIN, M. D. (Ed.). **Pathologic basis of veterinary disease**. 5th ed. St. Louis, MO: Elsevier, 2012. p. 2-59.
- NASCIMENTO, A. A.; ARANTES, I. G. Helminthiasis of tinamous. In: FOWLER, M. E.; CUBAS, Z. S. (Ed.). **Biology, medicine, and surgery of South American wild animals**. Ames, IA: Iowa State University, 2001. p. 76-80.
- OLSEN, J. H. Anseriformes. In: RITCHIE, B.W.; HARRISSON, G. J.; HARRISSON, L. R. (Eds.). **Avian medicine: principles and application**. Lake Worth, FL: Wingers, 1994. p. 1236-1275.
- OROSZ, X.; DORRESTEIN, G. M.; SPEER, B. L. Urogenital disorders. In: ALTMAN, R. B.; CLUBB, S. L.; DORRESTEIN, G. M.; QUESEMBERRY, K. (Ed.). **Avian medicine and surgery**. Philadelphia, PA: WB Saunders, 1997. p. 632-633.
- PINTO, R. M.; MENEZES, R. C.; TOTELLY, R. Systematic and pathologic study of *Paratanaisia bragai* (Santos, 1934) Freitas, 1959 (Digenea, Eucotyliidae) infestation on ruddy ground dove *Columbina talpacoti* (Temminck, 1811). **Arquivo Brasileiro de Medicina Veterinária e Zootecnia**, v. 56, n. 4, p. 472-479, 2004. doi: 10.1590/S0102-09352004000400008.
- QUEIROZ, S. A. A criação de perdizes na FCAV/UNESP. In: SIMPÓSIO DE CRIAÇÃO DA PERDIZES (*Rhynchotus rufescens*) EM CATIVEIRO, 1., 2003, Jaboticabal. **Proceedings...** Jaboticabal: UNESP, 2003. p. 1-17.
- RIDDELL, C. **Avian histopathology**. Kennett Square, PA: American Association of Avian Pathologists, 1987. 152 p.
- SCHMIDT, R. E. Pathology of gastrointestinal diseases of psittacine birds. **Seminars in Avian and Exotic Pet Medicine**, v. 8, n. 2, p. 75-82, 1999. doi: 10.1016/S1055-937X(99)80039-5.
- THOLON, P. **Avaliação da adaptação de perdizes (*Rhynchotus rufescens*) ao cativeiro**. 2002. 64 f. Dissertação (Mestrado) – Faculdade de Ciências Agrárias e Veterinárias, Universidade Estadual Paulista, Jaboticabal, SP., 2002.
- WERTHER, K. Principais enfermidades de perdizes. In: SIMPÓSIO DE CRIAÇÃO DA PERDIZES (*Rhynchotus rufescens*) EM CATIVEIRO, 1., 2003, Jaboticabal. **Proceedings...** Jaboticabal: UNESP, 2003. CD-ROM.