

# Cardiac lymphoma in dogs – report of three cases with citological diagnosis

## *Linfoma cardíaco em cães – relato de três casos com diagnóstico citológico*

Natália Pisciotano Noronha<sup>1\*</sup> ; Wiktor Prata Bakiewicz<sup>1</sup>; Luiz Roberto Biondi<sup>1</sup>; Patrícia Pereira Costa Chamas<sup>1</sup>

<sup>1</sup> Universidade Metropolitana de Santos, Faculdade de Medicina Veterinária, Santos - SP, Brazil

### ABSTRACT

Lymphoma is a very common lymphoid malignancy in dogs, but cardiac involvement is rare. Primary cardiac lymphoma is defined as lymphoma involving the heart, the pericardium, or both, and is classified as extranodal anatomical form. The present report describes the cases of three animals with cardiac lymphoma. All cases presented moderate to severe pericardial effusion and cardiac tamponade. The cytological analysis of the effusion was consistent with the diagnosis of cardiac lymphoma. The anatomopathological evaluation of the tumor extracted from the heart of one of the animals, after euthanasia, was consistent with cardiac lymphoma. The other two animals were treated with Madison-Wisconsin chemotherapy protocol and survived between 6 to 8 months. This report emphasizes the importance of pericardial effusion cytology for the diagnosis, appropriate treatment approach and monitoring of cardiac tumors in dogs and cats.

**Keywords:** Lymphoma. Pericardial effusion. Cytology. Cardiology.

### RESUMO

O linfoma é uma malignidade linfóide muito comum nos cães, mas o envolvimento cardíaco é raro. O linfoma cardíaco primário é definido como linfoma que envolve o coração, o pericárdio ou ambos, sendo classificado como forma anatômica extranodal. O presente relato descreve os casos de três animais com linfoma cardíaco, que apresentaram efusão pericárdica moderada a importante e tamponamento cardíaco, sendo a análise citológica da efusão consistente com o diagnóstico de linfoma cardíaco nos três animais. A avaliação anatomopatológica do tumor extraído do coração de um dos animais, após eutanásia, foi compatível com linfoma cardíaco. Os outros dois animais foram tratados com protocolo quimioterápico segundo Madison-Wisconsin e apresentaram sobrevida entre 6 a 8 meses. Por meio deste relato, ressalta-se a importância da citologia do líquido das efusões pericárdicas, para o diagnóstico e adequado tratamento e acompanhamento dos tumores cardíacos de cães e gatos.

**Palavras-chave:** Linfoma. Efusão pericárdica. Análise citológica. Cardiologia.

#### Correspondence to:

Natália Pisciotano Noronha  
Universidade Metropolitana de Santos, Faculdade de Medicina Veterinária, Hospital Veterinário  
Av. Dr. Antônio Manoel de Carvalho, 3935, Morro Nova Cintra  
CEP: 11080-300, Santos - SP, Brazil  
e-mail: npnoronha@hotmail.com

Received: January 10, 2019

Approved: April 08, 2019

**How to cite:** Noronha NP, Bakiewicz WP, Biondi LR, Chamas PPC. Cardiac lymphoma in dogs – report of three cases with citological diagnosis. *Braz J Vet Res Anim Sci.* 2019;56(2):e153496. <https://doi.org/10.11606/issn.1678-4456.bjvras.2019.153496>

### Introduction

Tumors involving the heart are relatively infrequent in animals and may be primary or metastatic. In dogs, reports describing primary heart tumors are more numerous than those describing metastatic heart disease. Malignant hemangiosarcoma is reported as the most common cardiac tumor in dogs, followed by aortic body tumors; other reports include cardiac myxomas, ectopic thyroid or parathyroid tumors, pericardial mesotheliomas, and lymphomas. Depending on their anatomical location and associated hemodynamic changes (restriction to ventricular filling secondary to external cardiac compression and venous congestion), cardiac tumors can cause pericardial effusion

and cardiac tamponade, with consequent decrease in cardiac output and cardiogenic shock. Arrhythmias can appear as a consequence of cardiac neoplasms and may also contribute to hemodynamic compromise (Ware & Hopper, 1999).

Lymphomas originate from lymphoreticular cells and comprise some of the most common neoplasias in dogs. They usually arise in lymphoid tissues, such as spleen, liver and bone marrow; however, they can also appear in almost all other tissues of the body. The most common forms of presentation of lymphoma in dogs, in descending order of prevalence, are multicenter, mediastinal, gastrointestinal, cutaneous and extranodal. Primary extranodal forms can occur anywhere outside the lymphatic system, such as the eyes, central nervous system, bones, testicles, bladder, kidneys, nasal cavity or heart (Kisseberth, 2013).

Primary lymphoma is rare in dogs and is defined as the lymphoma involving only or primarily the heart and / or pericardium (Tong et al., 2015). When this type of lymphoma causes pericardial effusion, it is then classified as stage V, according to the staging proposed by the World Health Organization (extranodal in an organ other than the liver or spleen) and sub-stage b (with clinical signs). Dogs with lymphoma above stage III and presence of clinical manifestations have worse prognosis for remission and survival than those with lower grade lymphoma; therefore, cardiac lymphoma is one of those with a worse prognosis. Cardiac lymphoma is a rare but potentially treatable cause of pericardial effusion (Macgregor et al., 2005).

The objective of this study is to report three cases of cardiac lymphoma in dogs and to highlight the importance of the cytological analysis of the contents obtained by

pericardiocentesis for the differential diagnosis of cardiac neoplasias that cause pericardial effusion.

## Case reports

*Case 1:* An 8-year-old female Labrador Retriever went to the Veterinary Hospital of the Metropolitan University of Santos - UNIMES, with the complaint of two months' duration expiratory dyspnea and exercise intolerance. Previous examinations with Doppler echocardiogram, abdominal ultrasonography and chest radiography had been performed in previous visits, but without a conclusive diagnosis.

Physical examination showed moderate abdominal fluid and auscultation of muffled heart and lung sounds. On echocardiography, the presence of nodular structures with irregular contours was observed in the pericardial space near the cardiac base, suggesting neoformation, and an important pericardial effusion causing right cardiac chamber tamponade (Figure 1). Abdominal ultrasonography revealed hepatomegaly and dilated hepatic vascular architecture suggesting a congestive process, in addition to moderate ascites. In the thoracic radiography, only mild pleural effusion was reported. After performing paracentesis, thoracentesis and pericardiocentesis, these fluids were analyzed by cytology. Neoplastic cells were not found in abdominal and pleural effusion. In the cytologic analysis of the pericardial fluid, a massive population of monomorphic lymphoblasts with loose chromatin nuclei, evident nucleoli and aberrant mitosis figures were observed, supporting the diagnosis of lymphoma.

Ten days after the diagnosis, the Madison-Wisconsin chemotherapy protocol for lymphoma (vincristine,

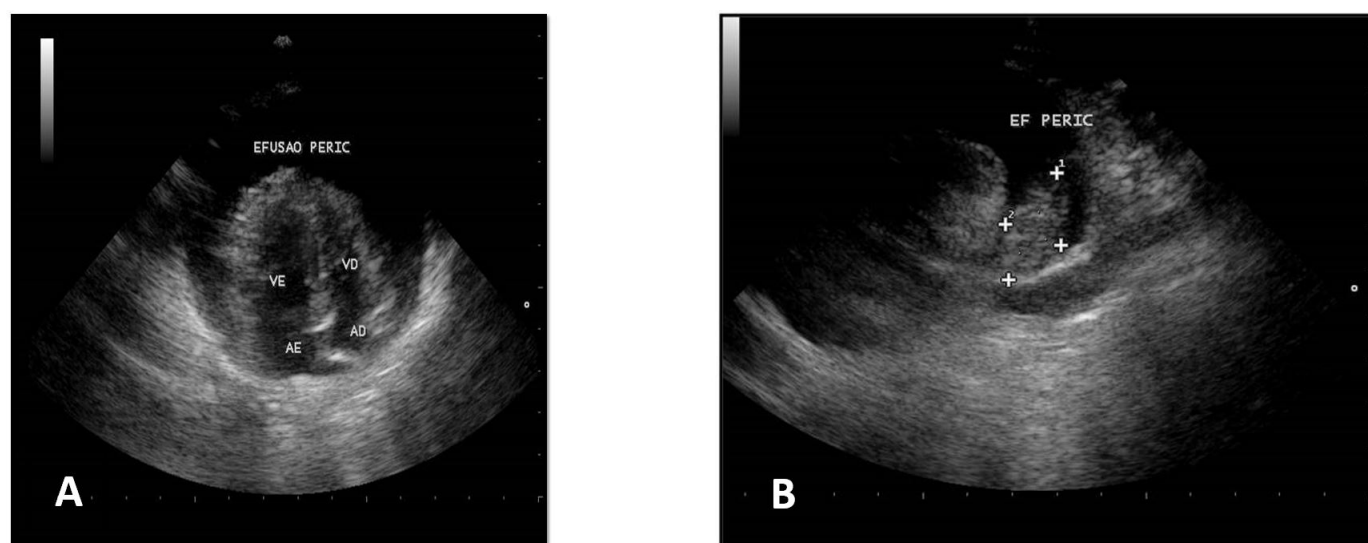


Figure 1 – Two-dimensional ecodopplercardiogram (Case 1 patient) demonstrating pericardial effusion (A) and presence of hyperechogenic formation inside the pericardial space (B)

cyclophosphamide, doxorubicin and prednisone) was instituted. During the protocol, blood screening tests were performed. Immediately after the initiation of the chemotherapeutic treatment, a significant improvement in the general status of the patient was observed. The protocol was extended for 26 weeks. During this period, control exams were performed, and no recurrence of effusions was observed. After finishing the chemotherapy protocol, a new echocardiogram was requested, which revealed mitral valve thickening and mild mitral valve insufficiency without hemodynamic repercussion, but no intrapericardial effusion or mass were observed.

The patient was discharged and followed up, being stable and free of the disease for 13 months. After this period, the patient returned to the hospital due to the presence of generalized peripheral edema. The origin of the edema was not elucidated, but maybe it was caused by a generalized lymphatic compromise secondary to lymphoma relapse. New imaging tests were performed to detect lymphoma recurrence in the heart, but no formation or effusion was observed. The Madison-Wisconsin chemotherapy protocol was restarted for a few days. During the treatment period, no decrease in edema was observed and unfavorable evolution of the patient's condition was evident, so the owner chose euthanasia. The time of patient's survival, from diagnosis to euthanasia, was 395 days.

*Case 2:* An 8-year-old mongrel female dog went to the Veterinary Hospital of the Metropolitan University of Santos - UNIMES, with hematochezia, exercise intolerance, bulging abdomen and hyporexia in the last 10 days.

During physical examination, muffled respiratory and cardiac sounds on auscultation, pale mucous membranes and moderate abdominal effusion were observed. There were no alterations in the blood profile and the echocardiogram showed a large amount of intrapericardial fluid causing cardiac tamponade, as well as the presence of an intrapericardial hyperechogenic nodular image with undefined contours, suggesting neof ormation. Abdominal ultrasonography denoted remarkable amount of high cellularity fluid, hepatomegaly and splenomegaly.

Paracentesis and pericardiocentesis were performed, and the content obtained in these procedures was sent for cytological analysis. In the pericardial fluid, there was a monomorphic population of lymphoblasts with loose nuclei of chromatin, evident nucleoli and figures of aberrant mitoses, supporting the diagnosis of lymphoma. However, no neoplastic cells was observed in abdominal effusion .

Because of the unavailability of the drugs, the Madison-Wisconsin chemotherapy protocol for lymphoma

was only initiated 30 days after the first visit. During the chemotherapy protocol, the animal remained stable for only 4 weeks; after this period, recurrence of abdominal and pericardial effusion was observed. The traditional protocol was maintained, but it was observed that, at each weaning at the dose of prednisone, as recommended by the protocol, the animal presented worsening in clinical manifestations and fluid accumulation. In order to minimize unfavorable clinical manifestations, the initial dose recommended by the protocol (2 mg/kg SID) was maintained without reduction throughout the treatment period.

Even with protocol adjustments, the animal remained unstable, requiring frequent paracentesis and pericardiocentesis. After 20 weeks of treatment, the animal presented pleural effusion for the first time, in addition to recurrent abdominal and pericardial effusion. New cytological analysis of effusions revealed malignant lymphoblastic cellularity in the pericardial fluid and absence of neoplastic cellularity in the others. After 2 weeks, the animal died at home due to significant respiratory distress. The survival time of this patient was 154 days.

*Case 3:* A 12-year-old male Cocker Spaniel went to the Veterinary Hospital of the Metropolitan University of Santos - UNIMES, with acute onset of lethargy and anorexia, without the presence of respiratory distress or cyanosis. Physical examination revealed pale mucous membranes, mild dehydration, muffled heart sounds, filiform pulse and tachypnea. An emergency thoracic radiograph was performed, which showed cardiomegaly, according to VHS measurement method, and dorsal displacement of the trachea without pulmonary alterations. Based on this result, echocardiographic examination was performed, demonstrating a moderate amount of pericardial effusion. FAST abdominal ultrasound was also performed and denoted a small amount of abdominal free fluid. Due to the severity of the symptoms presented by the patient, support fluid therapy and oxygen therapy were instituted. Abdominal and pericardial fluid were collected for cytological analysis; abdominal effusion was negative for neoplastic cells, but in the pericardial effusion, the presence of an abundant monomorphic lymphoblastic population was observed, supporting the diagnosis of lymphoma (Figure 2).

The owners were informed about the presumable diagnosis of lymphoma and, due to the cost of the chemotherapy protocol and the severe status of the patient, they chose euthanasia. After consent of the tutors, necropsy of the patient was performed, where the presence of an infiltrative mass in the right ventricular free wall was observed, either in the internal and external portion of the chamber. Thickening of

the pericardium was also observed (Figure 3). Fragments of the infiltrative mass, pericardium and mediastinal lymph node were sent for microscopic analysis. Histological findings were consistent with diffuse lymphoplasmocytic lymphoma in the myocardium and pericardium (Figure 2). The mediastinal lymph node was free of malignancy.

## Discussion

Primary heart tumors are rare in dogs, with an incidence of 0.12 to 4.44% of oncologic cases, with hemangiosarcoma the most frequently reported cardiac neoplasia (Ware & Hopper, 1999). Lymphoma is the most common malignant hematopoietic neoplasia in dogs, but cardiac involvement is

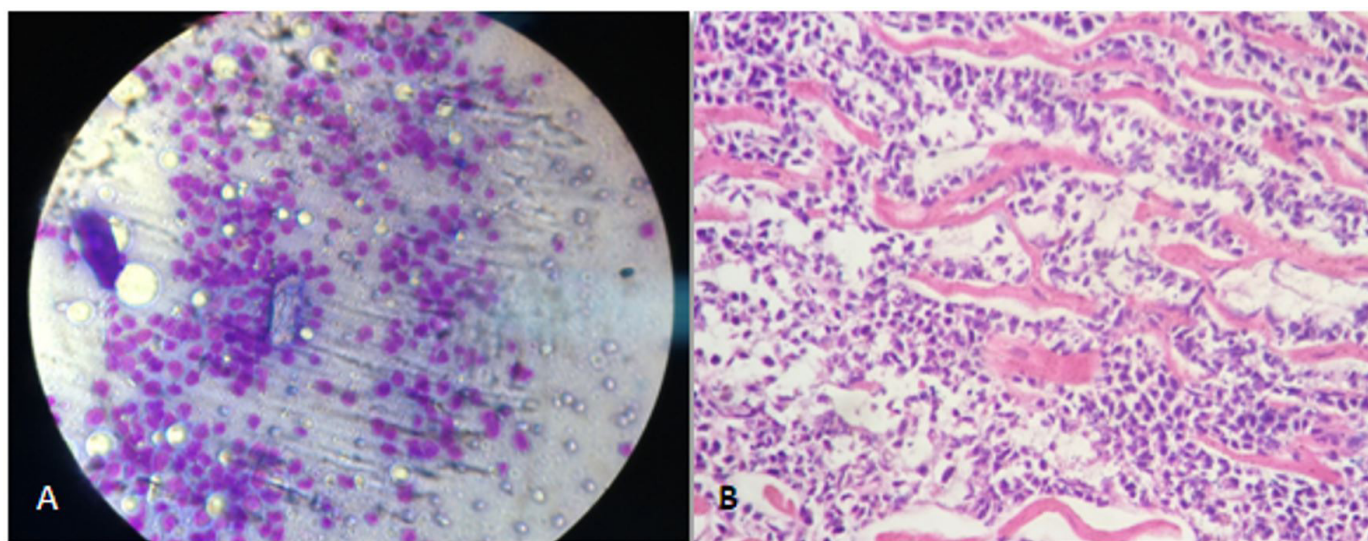


Figure 2 –(A) Cytology of pericardial effusion (patient of Case 3) revealing monomorphic population of lymphoblasts; (B) Histopathological study of the infiltrative mass in the right ventricle of the same patient, demonstrating the presence of diffuse and dense infiltration of round cells, dissecting cardiomyocytes

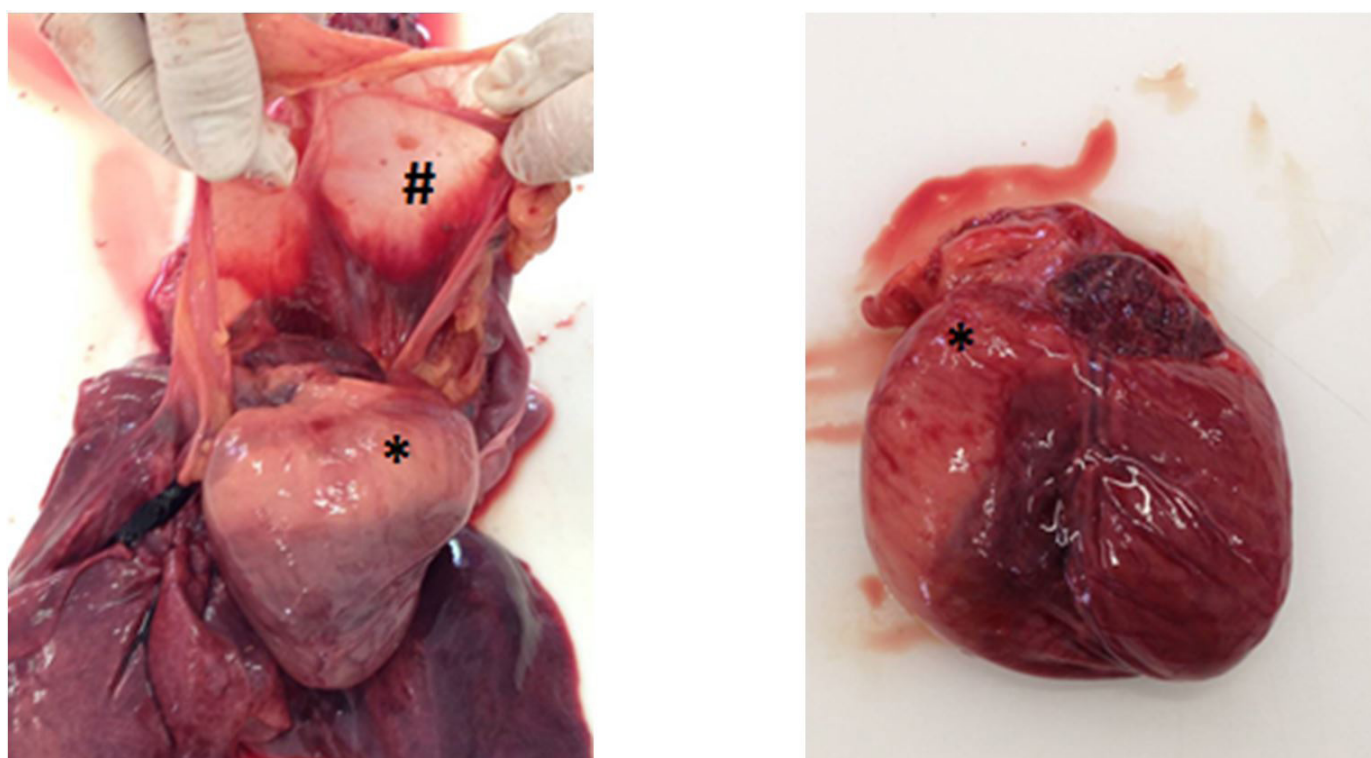


Figure 3 –Macroscopic aspect of the Case 3 patient's heart, demonstrating the presence of right ventricular mass infiltrating the right ventricular free wall (\*), as well as thickening of the pericardium (#)

rare (Sims et al., 2003; Tong et al., 2015). Primary cardiac lymphoma is defined as lymphoma involving only the heart and / or pericardium (Tong et al., 2015).

Pericardial disorders represent approximately 1% of all cardiovascular diseases in dogs and generally are associated with the presence of effusion. The most common causes of pericardial effusion are related mainly to pericardial or myocardial tumors or to idiopathic pericarditis (Sims et al., 2003). The three most common tumors that cause pericardial effusion include hemangiosarcoma, chemodectoma and mesothelioma. The pericardial effusion caused by lymphoma is rare in dogs, occurring in only 2 of the 164 (1.2%) cases previously studied in this species (Macgregor et al., 2005).

Several studies reported that pericardial fluid analysis and cytological examination failed to identify the cause of pericardial effusions in dogs, elucidating the diagnosis in only 7.7 to 12.8% of the cases. However, this accuracy changes when it refers to heart lymphoma. Macgregor et al. (2005) studied 12 cases of cardiac lymphoma, and the definitive diagnosis was possible in 11 cases by cytology of pericardial effusion. Similar results were obtained in the present study, in which the cytology of pericardial effusion was conclusive in the three cases that presented cardiac lymphoma.

The pericardial fluid of dogs with idiopathic or neoplastic pericardial effusion generally has a grossly bloody or “port wine” appearance, due to the high concentration of erythrocytes. In a retrospective study of 254 dogs with pericardial effusion due to different causes, it was observed that in cases where effusions had hematocrit lower than 10%, cytological analysis had a good diagnostic accuracy for the cardiac tumors, with 84.2% sensitivity and 71.9% specificity (Cagle et al., 2014). In the present study, the total red cell count of the pericardial effusion was not performed.

A retrospective study of 6 dogs showing cardiac tumors demonstrated that ultrasound-guided fine-needle aspiration cytology was able to confirm diagnosis in all cases (Pedro et al., 2016). However, in the present study, this procedure was not performed, due to the inherent risks of the technique and also to the fact that, by the cytology of effusion, the diagnosis was already conclusive.

Echocardiography is the most commonly used diagnostic technique for cardiac examination, with a sensitivity of 17-82% for detection of cardiac masses (Macdonald et al., 2009). In two different studies of dogs with pericardial

effusion of different causes, it was demonstrated that computed tomography and magnetic resonance imaging did not obtain better results in the detection of cardiac tumors when compared to two-dimensional echocardiography (Boddy et al., 2011; Scollan et al., 2015). The echocardiogram demonstrated the presence of a cardiac tumor in two of the three patients in the present study; necropsy revealed the presence of intracardiac mass in the patient in which no mass was observed at the echocardiogram.

There are few descriptions of the *antemortem* diagnosis of cardiac lymphoma in dogs and few studies detail clinical findings and prognosis in dogs affected with this type of tumor. In one study, mean survival time for dogs with cardiac lymphoma treated with combined chemotherapy agents was 157 days, and for dogs that did not receive chemotherapy, the median survival time was 22 days. This difference was not statistically significant, but in the chemotherapy group, several dogs had long-term survival. Cardiac lymphoma is among the categories of neoplasms that, historically, have worse prognosis; however, studies suggest that cardiac lymphoma does not always present a poor prognosis when compared to other stage V lymphomas subscale b (Macgregor et al., 2005; Tong et al., 2015). Patients followed up in this report presented variable survival time, ranging from 1 day for the patient who did not receive chemotherapy to 154 and 395 days for the patients treated with chemotherapy.

## Conclusions

Although rare, cardiac lymphoma is a potentially treatable cause of pericardial effusion and should be considered in the differential diagnosis of cardiac neoplasias. Cytological analysis of pericardial effusion is suitable to conclude the diagnosis of this disease. Further reports and studies are required regarding the survival and prognosis of animals with cardiac lymphoma treated with chemotherapy.

## Conflict of Interest

The authors state they have no conflicts of interest to declare.

## Ethics Statement

This Project was approved by the Ethics Committee of the Metropolitan University of Santos - UNIMES under the protocol number 522092018.

## References

- Boddy KN, Sleeper MM, Sammarco CD, Weisse C, Ghods S, Litt HI. Cardiac magnetic resonance in the differentiation of neoplastic and nonneoplastic pericardial effusion. *J Vet Intern Med.* 2011;25(5):1003-9. <http://dx.doi.org/10.1111/j.1939-1676.2011.0762.x>. PMID:21781165.
- Cagle LA, Epstein SE, Owens SD, Mellema MS, Hopper K, Burton AG. Diagnostic yield of cytologic analysis of pericardial effusion in dogs. *J Vet Intern Med.* 2014;28(1):66-71. <http://dx.doi.org/10.1111/jvim.12253>. PMID:24236526.
- Kisseberth WC. Neoplasia of the heart. In: Withrow S, Vail D, Page R, editors. *Small animal clinical oncology*. 5th ed. Philadelphia: Saunders; 2013. p. 700-5.
- MacDonald KA, Cagney O, Magne ML. Echocardiographic and clinicopathologic characterization of pericardial effusion in dogs: 107 cases (1985-2006). *J Am Vet Med Assoc.* 2009;235(12):1456-61. <http://dx.doi.org/10.2460/javma.235.12.1456>. PMID:20001781.
- Macgregor JM, Faria ML, Moore AS, Tobias AH, Brown DJ, Morais HSA. Cardiac lymphoma and pericardial effusion in dogs: 12 cases (1994-2004). *J Am Vet Med Assoc.* 2005;227(9):1449-453. <http://dx.doi.org/10.2460/javma.2005.227.1449>. PMID:16279390.
- Pedro B, Linney C, Navarro-Cubas X, Stephenson H, Dukes-McEwan J, Gelzer AR, Kraus MS. Cytological diagnosis of cardiac masses with ultrasound guided fine needle aspirates. *J Vet Cardiol.* 2016;18(1):47-56. <http://dx.doi.org/10.1016/j.jvc.2015.09.002>. PMID:26683157.
- Scollan KF, Bottorff S, Stieger-Vanegas S, Nemanic S, Sisson D. Use of multidetector computed tomography in the assessment of dogs with pericardial effusion. *J Vet Intern Med.* 2015;29(1):79-87. <http://dx.doi.org/10.1111/jvim.12479>. PMID:25307069.
- Sims CS, Tobias AH, Hayden DW, Fine DM, Borjesson DL, Aird B. Pericardial effusion due to primary cardiac lymphosarcoma in a dog. *J Vet Intern Med.* 2003;17(6):923-7. <http://dx.doi.org/10.1111/j.1939-1676.2003.tb02534.x>. PMID:14658732.
- Tong LJ, Bennett SL, Thompson SL, Adsett SL, Shiel RE. Right-sided congestive heart failure in a dog because of a primary intracavitary myocardial lymphoma. *Aust Vet J.* 2015;93(3):67-71. <http://dx.doi.org/10.1111/avj.12289>. PMID:25708789.
- Ware WA, Hopper DL. Cardiac tumors in dogs: 1982-1995. *J Vet Intern Med.* 1999;13(2):95-103. PMID:10225598.

---

**Financial support:** Author declares this study has been exempt of financial support.

**Authors Contributions:** All authors participated in the writing of the article, considering the reading and review stages.