

Short Communication

Diagnosis and surgical correction of atrial septal defect by inflow occlusion technique

Rodrigo Ramos de FREITAS¹;
Gustavo Augusto Keusch
Albano NOGUEIRA¹;
Eduardo Toshio IRINO¹;
Samantha Leite de SOUZA¹;
Angelo João STOPIGLIA¹;
Denise Tabacchi FANTONI²;
Luciana Oliveira Domingos
BARBUSCI²;
Maria Helena Matiko Akao
LARSSON³;
Fabio Biscegli JATENE⁴

1 - Laboratório de Cirurgia Cardiorrácica do Departamento de Cirurgia da Faculdade de Medicina Veterinária e Zootecnia da Universidade de São Paulo, São Paulo - SP.

2 - Departamento de Cirurgia da Faculdade de Medicina Veterinária e Zootecnia da Universidade de São Paulo, São Paulo - SP.

3 - Departamento de Clínica Médica da Faculdade de Medicina Veterinária e Zootecnia da Universidade de São Paulo, São Paulo - SP.

4 - Departamento de Córdio-pneumologia da Faculdade de Medicina da Universidade de São Paulo, São Paulo - SP.

Correspondência para:

EDUARDO TOSHIO IRINO
Laboratório de Cirurgia Cardiorrácica
Departamento de Cirurgia
Faculdade de Medicina Veterinária e
Zootecnia - USP
Av. Prof. Orlando Marques de Paiva, 87
Cidade Universitária "Armando de Salles de
Oliveira"
05508-270 - São Paulo - SP
São Paulo - SP
edutoshio@hotmail.com

Abstract

The present report is a clinical case of surgical repair of atrial septal defect in a dog. This report is aimed at presenting the diagnostic approach as well as the surgical repair using the inflow occlusion technique and later suture of the defect. It is therefore a highly feasible and practicable technique in veterinary medicine, since it does not use extracorporeal circulation.

Key-words:

Inflow Occlusion.
Atrial Septal Defect.
Dog.

Received: 17/09/2003
Accepted: 22/06/2004

During the fetal development of the animal, the interatrial septum is not a continuous structure dividing the atrial chambers, but rather, it is formed by two septa, respectively the septum primum (ventral portion), septum secundum (in the medial dorsal portion) and between them is the oval foramen, which is responsible for the blood flow from the left to the right atrium in this phase of development^{1,2,3,4}.

Within this context, atrial septal defect may be classified into three subtypes, which are called: defect of the *septum primum* (*ostium primum*), defect of the *septum secundum* (*ostium secundum*) and maintenance of the oval foramen. In veterinary medicine, only the first two are considered true defects².

In dogs, atrial septal defect is usually followed by other congenital heart diseases, and an isolated finding is rare. When this is the case, the defect of *septum primum* (*ostium primum*) is more rare².

A male, 9-month-old Lhasa Apso

dog, weighing 5 kilos had a clinical history of syncope. However, the animal showed good physical conditions, acyanosis, normal pulse and no alterations at cardiorespiratory auscultation. Serum analysis for *Dirofilaria* was negative and blood tests had normal values. At the electrocardiogram, right axis deviation and right ventricular overload were observed. At the radiographic examination, increased right cavities, dorsal deviation of trachea and pleural effusion were observed. An echocardiogram was then requested, where dilation of both atrial cavities, left ventricle and pulmonary artery was observed in addition to signs of hyperinflation. A hemodynamically significant ostium secundum atrial septal defect of 6 mm was identified (Figure 1).

Surgical repair of the atrial septal defect was considered the best treatment option. Preanesthetic medication was administered in combination with

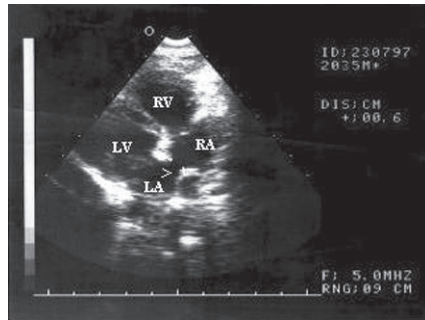


Figure 1 - Bi-dimensional echocardiogram: right parasternal longitudinal four-chamber view showing the ostium secundum type of atrial septal defect (arrow)

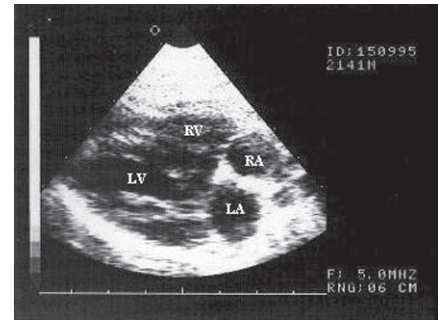


Figure 3 - Bi-dimensional echocardiogram: four-chamber longitudinal view showing the intact septum more echogenic probably due the suture

acepromazine maleate (0.05mg/kg [0.02mg/lb],IM) and meperidine hydrochloride (1mg/kg[0.45mg/lb],IM). Induction of anesthesia with fentanyl citrate (0.005mg/kg [0.002mg/lb]) was followed by the administration of etomidate (0.5mg/kg [0.2mg/lb]) and isoflurane 100% for anesthetic maintenance using a closed circuit. Vecuronium 0.1mg/kg[0.04mg/lb] was administered as a neuromuscular blocker. Electrocardiographic monitoring, invasive pressure, oximetry as well as the analysis of anesthetic gases were performed throughout the surgical procedure. The surgical repair of the atrial septal defect was carried out by conventional right intercostal thoracotomy and the inflow occlusion technique (Figure

2), in two normothermia periods of respectively three and five minutes. The defect was closed by continuous suture with 3-0 polypropylene thread, and no surgical patches were required. There were no complications during the surgical procedure and the postoperative follow-up. The animal was reexamined 20 days postoperatively, when no further episodes of syncope were reported, and no signs of the defect were observed by echocardiogram (Figure 3). Twenty-four months after the surgical intervention, the animal was in good clinical conditions.

Clinical history as well as additional tests reported in this study are in agreement with those found in literature, especially those

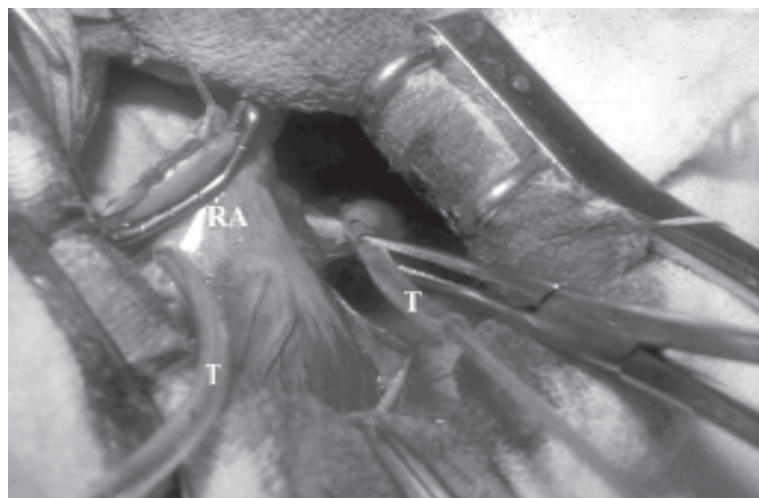


Figure 2 - Right atrium suture and the inflow occlusion technique. RA: Right Atrium; T: Tourniquet

considering echocardiographic examination the test that provides a definitive diagnosis^{3,4,5,6}. The definitive treatment for atrial septal defect includes intracardiac surgical procedure, with or without extracorporeal circulation, using suture or occlusion with a patch^{1,7}. One of the techniques that does not require extracorporeal circulation is inflow occlusion, which consists of the transient blockage of blood circulation by passing a loop around

both vena cava and the azygos vein^{7,8}.

The inflow occlusion technique was chosen for the present case because it is less deleterious, since once the animal is placed on extracorporeal circulation, there are subsequent blood alterations that may result in severe damages to the organism^{9,10}. It is therefore, a highly feasible and practicable intracardiac surgical technique in veterinary medicine, with a good prognosis.

Diagnóstico e correção cirúrgica do defeito septal atrial pela técnica de parada circulatória

Resumo

O presente caso trata-se do relato de correção cirúrgica do defeito septal atrial em cão. Este caso objetivou a demonstração dos métodos diagnósticos utilizados assim como o reparo cirúrgico utilizando-se da técnica de parada circulatória e posterior fechamento do defeito através de sutura. Tal técnica mostrou-se altamente exequível em medicina veterinária já que não utiliza circulação extra-corpórea.

Palavras-chave:

Parada circulatória.
Defeito septal atrial.
cão.

References

- BONAGURA, J. D. Moléstia cardíaca congênita. In: ETTINGER, S. J. *Tratado de medicina interna veterinária*. São Paulo: Manole, 1992, p. 1026-1082.
- ETTINGER, S. J.; SUTER P. F. Congenital heart disease. In: ETTINGER, S. J., SUTER P. F. *Canine Cardiology*. Philadelphia : WB Saunders Company. 1970, p. 477-578.
- SAN ROMAN, J. A.; VILACOSTA, I.; ZAMORANO, J.; CASTILLO, J. A.; ROLLAN, M. J.; VILLANUEVA, M. A.; ALMERIA, C.; SÁNCHEZ-HARGUINDEY, L. Transthoracic and transesophageal echocardiography in the pre- and postoperative assessment of interatrial communication. *Rev Esp Cardiol*, v. 46, n. 12, p. 810-815, 1993.
- SUBIRANA, M. T.; BORRAS, X.; CARALPS, J. M.; ARIS, A.; PADRO, J. M.; CAMARA, M. L.; TORNER SOLER, M. Cirugía de la Comunicación Interauricular en el adulto. Resultado a largo plazo en 100 casos consecutivos. *Rev Esp Cardiol*, v. 41, n. 1, p. 26-30, 1988.
- FONTES, V. F.; PEDRA, C. A. PEDRA, S. R.; ESTEVES, C. A.; BRAGA, S. L.; ASSEF, J. E.; PONTES JUNIOR, S. C.; SANTANA, M. V.; HIJAZI, Z. M.; SOUZA, J. E. Experiência inicial no fechamento percutâneo da Comunicação Interatrial com a Prótese de Amplatzer. *Arq Bras Cardiol*, v. 70, n. 3, p. 147-153, 1998.
- KIRBERGER, R. M.; BERRY, W. L. Atrial septal defect in a dog: the value of Doppler echocardiography. *Journal of the South African Veterinary Association*, v. 63, n. 1, p. 43-48, 1992.
- SLATTER, D. Textbook of Small Animal Surgery. In: EYSTER GE. *Basic Cardiac Surgical Procedures*. Philadelphia: WB Saunders Co, 1993, p. 912.
- FOSSUM, T. W. Small Animal Surgery. In: ORTON, C. E. *Surgery of the Cardiovascular System*. St. Louis: Mosby-Year Booh, 1997, p. 578.
- KAMENEVA, M. V.; UNRAR, A.; ANTAKI, J. F.; WATACH, M. J.; CALHOON, J. H.; BOROVETZ, H. S. Decrease in red blood cell deformability caused by hypothermia, hemodilution, and mechanical stress: factors related to cardiopulmonary bypass. *ASAIO J*, v. 45, n. 4, p. 307-310, 1999.
- MURIITHI, E. W.; BELCHER, P. R.; RAO, J. N.; CHAUDHRY, M. A.; NICOL, D.; WHEATLEY, D. J. The effects of heparin and extracorporeal circulation on platelet counts and platelet microaggregation during cardiopulmonary bypass. *J Thorac Cardiovasc Surg*, v. 120, n. 3, p. 538-543, 2000.