

## Intestinal Protozoa in apprehended New World nonhuman primates

Paulo Roberto de  
CARVALHO FILHO<sup>1</sup>  
Sergian Vianna CARDOZO<sup>2</sup>  
Carlos Torres RIBEIRO<sup>3</sup>  
Simoni Machado de  
MEDEIROS<sup>4</sup>  
Carlos Wilson Gomes  
LOPES<sup>5</sup>

1 - Ciências Veterinárias da Universidade Federal Rural do Rio de Janeiro, Seropédica - RJ  
2 - Microbiologia Veterinária da Universidade Federal Rural do Rio de Janeiro, Seropédica - RJ  
3 - Centro de Triagem de Animais Silvestres, IBAMA  
4 - Projeto Sanidade Animal (EMBRAPA/UFRuralRJ)  
5 - Departamento de Parasitologia Animal do Instituto de Veterinária da Universidade Federal Rural do Rio de Janeiro, Seropédica - RJ

### Correspondence to:

CARLOS WILSON GOMES LOPES  
Departamento de Parasitologia Animal  
Instituto de Veterinária  
Universidade Federal Rural do Rio de Janeiro  
BR-465 Km 07  
23890-000 - Seropédica - RJ  
lopescwg@ufrj.br

Received: 18/06/2004  
Accepted: 23/08/2005

### Abstract

The objective of this study was to identify intestinal protozoa in fecal samples of illegally commercialized New World nonhuman primates apprehended by governmental authorities and sent to a Wildlife Screening Center in the municipality of Seropédica, State of Rio de Janeiro, under the administration of Instituto Brasileiro de Meio Ambiente e Recursos Naturais. Feces from marmosets (crossbreeding among *Callithrix jacchus* and *C. penicillata*) and brown howler monkeys (*Alouatta fusca*) were collected and submitted to Richtie's formaldehyde-ether sedimentation technique. Smears were made with the sediment and submitted to safranin-methylene blue and Wheatley's modified trichrome stainings. Phenol-auramine staining was used in order to compare positive smears for *Cryptosporidium* oocysts stained with safranin-methylene blue technique. Three (100%) fecal samples of brown howler monkeys and eight of common marmosets (88.9%) were positive for *Cryptosporidium* oocysts. *Blastocystis hominis*-like forms were observed in all samples of brown howler monkeys and in 66.7% (6/9) of marmosets. New World nonhuman primates *Callithrix* crossbreed species and *A. fusca* can harbor forms similarly identified as potential zoonotic organisms. The strict contact between monkeys and humans can represent risks for both by mutual transmission of pathogens. It is unknown if monkey species studied in the present work are either infected with these parasites in natural environment or acquire it when submitted to human contact. Stressing is also a factor that deserves attention on animals submitted to capture, apprehension and transport to Wildlife Screening Centers.

### Key-Words:

Marmosets.  
brown howler monkeys.  
*Cryptosporidium*.  
*Blastocystis hominis*.  
Nonhuman primates.

### Introduction

Increased probability of parasitism is a cost of living in a group<sup>1</sup>. Many monkey species (*e.g.* *Alouatta seniculus*) have chronic endoparasite infections. Most of these infections are probably asymptomatic, based on low number of parasites per individual monkeys and qualitative measures of health, although, some of the parasite species are

potential pathogens<sup>2</sup>.

Protozoa of the genus *Cryptosporidium* have been found in feces of many mammalian hosts and it is associated to acute enterocolitis<sup>3,4,5</sup>. *Cryptosporidium* infection is known to be transmitted through person-to-person transmission or through zoonotic transmission<sup>6,7</sup>. The organism *Cryptosporidium* is an emergent zoonotic agent reported in humans in 1976 at which time it was regarded

as a rare opportunistic infection of immunocompromised individuals<sup>8</sup>. Nowadays, cryptosporidiosis is one of the most common second diagnoses in AIDS patients<sup>9</sup>.

*Cryptosporidium* infection is diagnosed by identifying the oocyst stages of the parasites in host feces or biopsy tissue. Oocysts are difficult to demonstrate during routine fecal examination, because their small size (2-6 µm)<sup>10</sup>, and are most commonly identified in clinical laboratories by acid-fast staining of fecal smears or concentrates with carbolfuchsin (cold Kinyoun stain, dimethyl sulfoxide-carbolfuchsin, or Ziehl-Neelsen stain)<sup>11,12,13,14</sup>, by fluorescence staining with phenol-auramine<sup>15,16</sup>, or by oocyst flotation on Sheather's sucrose solution followed by phase microscopy<sup>8,13</sup>. Other effective methods of oocysts detection are also used, including safranin staining<sup>17,18</sup>, iodine staining<sup>13</sup>, Hemacolor staining<sup>19</sup>, methylene blue-eosin staining<sup>20</sup>, Giemsa staining<sup>21</sup>, negative staining by periodic acid-Schiff reagent<sup>22</sup>, electron microscopy<sup>23</sup> and indirect immuno-fluorescence technique<sup>24</sup>.

*Blastocystis hominis* is an intestinal parasite that has been observed in three distinct forms: vacuolated, granular and ameboid forms. It reproduces by both binary fission and endosporulation<sup>25,26,27</sup>. Although, this organisms is generally thought of as a common non-pathogenic inhabitant of the intestinal tract, it has been incriminated as a cause of enteric disease and diarrhea in man<sup>28,29,30</sup>. The presence of *B. hominis* in dogs, cats, monkeys, rats, rabbits, mice, guinea pigs, frogs, snakes, earthworms, houseflies and swines is briefly mentioned by Zierdt & Tan<sup>31</sup>, Boreham and Stenzel<sup>26</sup>, Stenzel and Boreham<sup>27</sup>.

This paper aims at to relate enteroparasitosis in two species of illegally commercialized New World nonhuman primates apprehended by Brazilian governmental authorities and temporarily housed in a Wildlife Screening Center.

## Materials and Methods

### Origin of fecal samples

Fecal samples of New World nonhuman

primates were acquired in a Wildlife Screening Center (CETAS) located in the municipality of Seropédica in the State of Rio de Janeiro, Brazil (22° 43' S, 43° 42' W, height: 40 meters). This center has been administrated by Instituto Brasileiro de Meio Ambiente e Recursos Naturais (IBAMA), which has an institutional pact with Instituto Estadual de Florestas – Rio de Janeiro (IEF/RJ) and Universidade Federal Rural do Rio de Janeiro. CETAS receives illegally commercialized wild animals apprehended by governmental authorities.

### Nonhuman primates examined

Fecal samples were acquired from four brown howler monkeys (*Alouatta fusca*) and 21 hybrid marmosets (*Callithrix* spp.). One stool sample was acquired from a posted severely injured newcomer marmoset that died few hours after arriving at CETAS. The indetermination of *Callithrix* species examined in the present study is due to hybridization commonly found among specimens from this genus (crossbreeding between *Callithrix jacchus* – common marmoset – and *C. penicillata* – black tufted-ear marmoset). Newcomer animals are arranged in 40 m<sup>3</sup> cages for howler monkeys and 2,5 m<sup>3</sup> for marmosets respecting group organization observed when they arrive at the center. Age varied too much, and being apprehended animals, it was virtually impossible to determine it. Nevertheless, animals could be classified into three age groups: juveniles, young adults and elderly animals.

### Sample collects and material procedures

It was operationally impossible to proceed to individual collets from all animals housed at CETAS for the following reasons: (i) primates have been lodged into groups and to proceed to individual collets, animals would have to be captured, anesthetized and submitted to anal stimulation to induce defecation; (ii) these procedures conducted to animals that were not submitted to previous feeding stopping, would cause health risks and (iii) submit animals to isolation would induce stressing, which would be a harmful factor to the parasite research and to the study. To avoid

theses factors, clean sheets of paper were distributed over the floor, along the place where the animals are used to defecate. Only feces found over the paper were used as samples, which were collected 24 hr post-floor defecation. Approximately ten grams of fresh feces were put in properly labeled, clean wide mouthed containers with tightly fitting lids, fixed in polyvinyl alcohol (PVA) and immediately sent to the Department of Animal Parasitology at the Veterinary Institute in the Universidade Federal Rural do Rio de Janeiro, Seropédica, RJ, Brazil. At the laboratory, samples were diluted in PBS pH 7.2, drizzled throughout a double-layered gauze and submitted to modified formaldehyde-ether centrifuge-sedimentation technique<sup>32</sup>. One drop of the sediment was transferred to a glass microscope slide, added to another drop of Lugol's iodine solution (6%), covered with a coverglass and examined in a light microscope. Duplicate sediment smears were done using the material obtained by the previous technique and stained by safranin-methylene blue (S-MB) technique<sup>5</sup> and Wheatley's trichrome technique<sup>25</sup> to identification of *Cryptosporidium* oocysts and other intestinal protozoa in light microscope respectively. Fecal smears positive for *Cryptosporidium* oocysts were submitted to phenol-auramine (P-A) staining<sup>15</sup> and read on an Epi-fluorescence microscope in order to corroborate diagnoses using S-MB technique.

#### Measurement of *Cryptosporidium* oocysts

*Cryptosporidium* oocysts were measured by using a K-15X micrometric ocular (Carl Zeiss Jena) in a tri-ocular microscope (Jena Med, Carl Zeiss Jena) to confirm similarity among specimens identified in the present study and those that are already known to parasitize other nonhuman primates.

## Results

#### Health status of the animals

During the period of clinical evaluation,

only two juveniles brown howler monkeys had diarrhea. Feces obtained from the cage, where these animals were housed, were weakly molded. *Cryptosporidium* oocysts (from 6 to 10 oocysts per field) were found in the sediment smear stained by S-MB technique while low infection by *Blastocystis hominis*-like forms was identified by trichrome staining technique (less than 1 organism per field).

#### Centrifuge-sedimentation technique

In a total of 12 samples, corresponding to 25 animals included in the present study, in only one of them it became possible to identify some parasite related structure using the centrifuge-sedimentation technique. *Blastocystis hominis*-like life stages, very similar to granular forms of this organism, were found in wet amount of the fecal sediment from stools collected under a common marmoset cage (Figure 1). No other protozoa or helminth ova were found using this technique.

#### Safranin - methylene blue technique

Ten stool samples (91.7%) submitted to S-MB technique were positive for *Cryptosporidium* oocysts (Tables 1 and 3). Oocysts observed were bright, red in color, refractile and round in shape, seen against a blue background. Internal morphology was observed in many of the stained oocysts (Figure 2). They measured from 2.0 to 4.3  $\mu\text{m}$  in diameter. Of 40 oocysts measured, length and width were  $3.18 \pm 0.52$  and  $2.80 \pm 0.55 \mu\text{m}$ , respectively. Samples positive for *Cryptosporidium* oocysts on S-AM staining were also positive on P-A staining (Figure 3).

#### Trichrome staining technique

Seven fecal samples (75%) were positive for some protozoa parasite when observed on slides stained by Wheatley's trichrome staining (Tables 2 and 4). *Blastocystis hominis*-like (Figure 4) forms were visualized on seven slides stained by this technique while *Chilomastix mesnili* cysts were found in only

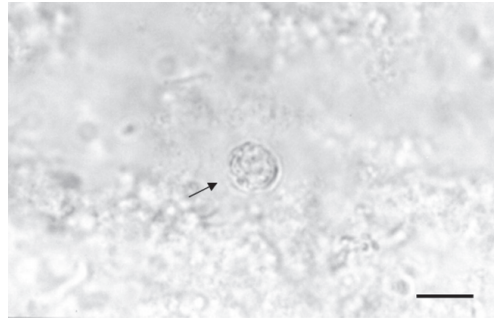


Figure 1 - *Blastocystis hominis*-like life stage in feces sample of marmosets (pointed by an arrow). Ritchie's centrifuge- sedimentation method. Bar = 10  $\mu$ m




Figure 2 - *Cryptosporidium* oocyst in feces sample of brown howler monkeys (pointed by an arrow). Safranin – methylene blue staining technique. Bar = 20  $\mu$ m

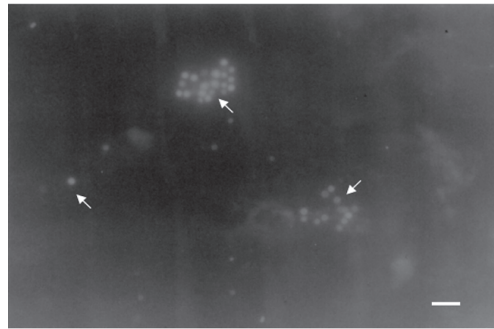


Figure 3 - *Cryptosporidium* oocysts in feces sample of marmosets (pointed by arrows). Phenol – auramine staining technique on Epi- fluorescence microscopy. Bar = 20  $\mu$ m

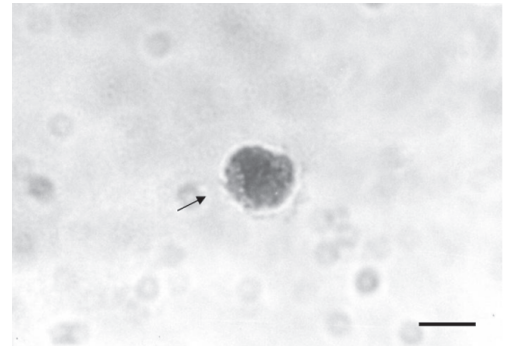


Figure 4 - *Blastocystis hominis*-like life stage in feces sample of brown howler monkeys (pointed by an arrow). Wheatley's trichrome staining technique. Bar = 10  $\mu$ m

one sample examined. This flagellated parasite was found in concomitance with *B. hominis*-like structures of an individual sample of an adult male brown howler monkey that was housed alone.

### Discussion

Through these results, individuals of the species *A. fusca* and *Callithrix* crossbreed species can be infected by the intestinal protozoans *Cryptosporidium*, *C. mesnili* and *B. hominis*-like. Special attention must be given to the first and the third parasites due to (i) high frequency that these were found in fecal samples and (ii) the possibility that these organisms in being transmitted from monkeys to human. Clinical signs seem not to be obligate in healthy animals similarly to infection in humans. It is not possible to assert if the juvenile howler monkeys evaluated in

the present study either had diarrhea due to *Cryptosporidium* infection or had considerably large quantity of oocysts in fecal stool caused by stressing process on account of other factors as housing conditions, food adaptation or reduced activity in captive environment. *Blastocystis* seems to be submitted to same type of doubts.

Another aspect that deserves comments is the fact that none monkey submitted to this study had helminth ova in their feces. It is known that some primates of the genus *Alouatta* have a particular behavior related to defecation sites and group arrangement. This feature seems to make members of the group with low rate of parasite infection<sup>2</sup> and possibly conducts to low rate of parasitism even inside screening facilities.

Some nonhuman primate (NHP)

species have been described as hosts of *Cryptosporidium*, including *Papio hamadryas* (= *cynocephalus*), *Macaca nemestrina*, *M. mulatta*, *M. radiata*, *M. fascicularis*, *Saimiri* species<sup>4,33,34,35,36</sup>. *Cryptosporidium* oocysts were detected in feces from *Ateles belzebuth*, *Cercocebus torquatus lunulatus*, *Cercopithecus aethiops*, *C. campbelli*, *C. talapoin*, *Erythrocebus patas*, *M. mulatta* and *Lemur macaco-mayottensis*, in a study designed at the Barcelona zoo. No clinical sign of cryptosporidiosis was observed<sup>37</sup>. A study developed with

monkeys trapped in the rural area of Kenya revealed that 70.7% of vervet monkeys (*C. aethiops*) and 28.8% of olive baboons (*P. cynocephalus anubis*) had *Cryptosporidium* oocysts in fecal samples<sup>38</sup>.

McClure<sup>39</sup> related a single case of diarrhea in pig-tailed macaque (*Macaca nemestrina*) where it was found large number of *B. hominis* forms in fecal smears. Beyond this species, *Blastocystis* was also found in feces samples of *M. mulatta* (100% of the samples), *M. fuscata fuscata* (75%), *M. radiata*

Table 1 - *Cryptosporidium* infection in monkeys

Species	Common name	Samples examined	Samples positive	Positive rate (%)
<i>Alouatta fusca</i>	Brown howler monkeys	3 (04)	3 (04)	100,0
<i>Callithrix</i> sp.	Marmoset	9 (21)	8 (17)	88,9
<b>Total</b>		12 (25)	11 (21)	91,7

Number inside parenthesis means animals examined or included in positive samples.

Table 2 - *Blastocystis hominis*-like infections in monkeys

Species	Common name	Samples examined	Samples positive	Positive rate (%)
<i>Alouatta fusca</i>	Brown howler monkeys	3 (04)	3 (04)	100,0
<i>Callithrix</i> sp.	Marmoset	9 (21)	6 (15)	66,7
<b>Total</b>		12 (25)	9 (19)	75,0

Number inside parenthesis means animals examined or included in positive samples.

Table 3 - Intensity of *Cryptosporidium* infection in fecal samples

Species	+	++	+++	++++
<i>Alouatta fusca</i>	0 (0)	2 (02)	1 (2)	0 (0)
<i>Callithrix</i> sp.	5 (8)	3 (09)	0 (0)	0 (0)
<b>Total</b>	5 (8)	5 (11)	1 (2)	0 (0)

Number outside parenthesis means samples included in each intensity cell and inside parenthesis means number of animals (+) < 1 oocyst per slide field; (++) 1-5 oocysts per field; (+++) 6-10 oocysts per field; (++++) > 10 oocysts per field

Table 4 - Intensity of *Blastocystis hominis*-like infection in fecal samples

Species	+	++	+++	++++
<i>Alouatta fusca</i>	1 (02)	2 (2)	0 (0)	0 (0)
<i>Callithrix</i> sp.	4 (10)	2 (5)	0 (0)	0 (0)
<b>Total</b>	5 (12)	4 (7)	0 (0)	0 (0)

a) Number outside parenthesis means samples included in each intensity cell and inside parenthesis means number of animals (+) < 1 organism per slide field; (++) 1-5 organism per field; (+++) 6-10 organism per field; (++++) > 10 organism per field

(100%) and *Saimiri sciureus* (100%), collected from monkeys bred at the Monkey Care Laboratory of the Primate Research Institute of Kyoto University, revealing high rate of infection by this organism. Fecal smears of common marmosets (*C. jacchus*) were searched for *B. hominis* in animals housed at the same place and in none of them it was found any organism related to this parasite<sup>36</sup>.

Zoonotic transmission of genotype 2 anthrozoophilic *Cryptosporidium parvum* was identified among free-ranging mountain gorillas (*Gorilla gorilla beringei*) and humans who work or live within the Bwindi Impenetrable National Park boundaries<sup>40</sup>. About *B. hominis*, phylogenetic studies reveal relative similarity among strains isolated from *M. fuscata fuscata* and human<sup>41</sup>. Primate species, especially common marmosets, are used to live in strict contact with humans as

pets, an illegal but usual practice. This fact can submit humans to risk in acquiring parasites phylogenetically similar to anthroponotic protozoa and start inducing cross-transmission among nonhuman primates and humans. In other hand, workers that handle these animals, as veterinarians, biologists or general staff in zoos, wildlife screening centers or wildlife preservation parks, have to be informed concerning the risks involved in their jobs and how to avoid or decrease it to the minimum acceptable.

## Acknowledgements

Authors thank CNPq and FAPERJ for research auspices, and thank Mrs. Ana Raquel Gomes Faria Bezerra, Mr. Rodrigo de Cerqueira da Costa and CETAS general staff for institutional support.

## Protozoários intestinais em primatas não-humanos apreendidos

### Resumo

O objetivo deste estudo foi identificar protozoários intestinais em amostras fecais de primatas neotropicais não-humanos, comercializados ilegalmente, apreendidos por autoridades governamentais, e enviados para um centro de triagem de animais silvestres no município de Seropédica, Estado do Rio de Janeiro, sob a administração do Instituto Brasileiro de Meio Ambiente e Recursos Naturais. Fezes de micos-saguí (cruzamento entre *Callithrix jacchus* e *C. penicillata*) e bugios marrons (*Alouatta fusca*) foram coletados e submetidos à técnica de centrifugo-sedimentação de Ritchie. Esfregaços foram confeccionados com o sedimento e submetidos à coloração pelas técnicas da safranina-azul de metileno e Tricrômio modificada de Wheatley. Três (100%) amostras fecais de bugios marrons e oito (88,9%) de micos-saguí foram positivos para oocistos de *Cryptosporidium*. Formas de *Blastocystis hominis*-simile foram observadas em todas as amostras de bugios marrons e em 66,7% (6/9) de micos-saguí. Primatas neotropicais não-humanos como os micos-saguí originados do cruzamento de espécies de *Callithrix* e a espécie *A. fusca* podem abrigar formas similarmente identificadas como organismos com potencial zoonótico. O contato estrito entre macacos e humano pode representar riscos para ambos por transmissão mútua de patógenos. Não está esclarecida se as espécies de macacos estudadas no presente trabalho são também infectadas com estes parasitos em ambiente natural ou adquirem estes quando submetidos ao contato humano. Estresse é também um fator que merece atenção para os animais submetidos à captura, apreensão e transporte para o centro de triagem de animais silvestres.

### Palavras-chave:

Micos-saguí.  
Bugios marrons.  
*Cryptosporidium*  
*Blastocystis hominis*.  
Primatas não humanos.

## References

- 1 ALEXANDER, R. D. The evolution of social behavior. **Annual Review of Ecology and Systematics**, v. 5, p. 325-383, 1974.
- 2 GILBERT, K. A. Red howling monkey use of specific defecation sites as a parasite avoidance strategy. **Animal Behaviour**, v. 54, p. 451-455, 1997.
- 3 LEVINE, N. D. Taxonomy and review of the coccidian genus *Cryptosporidium* (Protozoa, Apicomplexa). **Journal of Parasitology**, v. 31, p. 94-98, 1984.
- 4 MILLER, R. A.; BRONSDON, M. A.; KULLER, L.; MORTON, W. R. Clinical and parasitologic aspects of cryptosporidiosis in nonhuman primates. **Laboratory Animal Science**, v. 40, p. 42-46, 1990.
- 5 FAYER, R.; UNGAR, B. L. P. *Cryptosporidium* spp. and cryptosporidiosis. **Microbiology Reviews**, v. 50, p. 458-483, 1986.
- 6 BAXBY, D.; HART, C. A.; TAYLOR C. Human cryptosporidiosis: a possible case of hospital cross infection. **British Medical Journal**, v. 287, p. 1760-1761, 1983.
- 7 BLAGBURN, B. L.; CURRENT, W. L. Accidental infection of a researcher with human *Cryptosporidium*. **Journal of Infectious Diseases**, v. 148, p. 772-773, 1983.
- 8 CURRENT, W. L.; REESE, N. C.; ERNEST, J. V.; BAYLAY, W. S.; HEYMAN, B. M.; WEINSTEIN, W. M. Human cryptosporidiosis in immuno-competent and immuno-deficient persons. Studies of an outbreak and experimental transmission. **New England Journal of Medicine**, v. 308, p. 1252-1257, 1983.
- 9 COLFORD, J. M.; TAGER, I. B.; HIROZAWA, A. M.; LEMP, G. F.; ARAGON, T.; PETERSEN, C. Cryptosporidiosis among patients infected with human immunodeficiency virus. **American Journal of Epidemiology**, v. 144, p. 807-816, 1996.
- 10 ENTRALA, E.; RUEDA-RUBIO, M.; JANSSEN, D.; MASCARU, C. Influence of hydrogen peroxide on acid-fast staining of *Cryptosporidium parvum* oocysts. **International Journal of Parasitology**, v. 25, n. 12, p. 1473-1477, 1995.
- 11 HENRIKSEN, S. A.; POHLENZ, J. F. L. Staining of Cryptosporidia by a modified Ziehl-Neelsen technique. **Acta Veterinaria Scandinava**, v. 22, p. 594-596 1981.
- 12 GARCIA, L. S.; BRUCKNER, D. A.; BREWER, T. C.; SHIMIZU, R. Y. Techniques for the recovery and identification of *Cryptosporidium* oocysts from stool specimens. **Journal of Clinical Microbiology**, v. 18, p. 185-190 1983.
- 13 MA, P.; SOAVE, R. Three-step stool examination for cryptosporidiosis in 10 homosexual men with protracted watery diarrhea. **Journal of Infectious Diseases**, v. 147, p. 824-828, 1983.
- 14 BRONSDON, M. A. Rapid dimethyl sulfoxide-modified acid-fast stain of *Cryptosporidium* oocysts in stool specimens. **Journal of Clinical Microbiology**, v. 19, p. 952-953, 1984.
- 15 NICHOLS, G.; THOM, B. T. Screening for *Cryptosporidium* in stools. **Lancet**, v. 323, n. 8379, p. 734-735, 1984.
- 16 NAVIN, T. R.; JURANEK, D. D. Cryptosporidiosis: clinical, epidemiologic and parasitologic review. **Reviews of Infectious Diseases**, v. 6, p. 313-327, 1984.
- 17 BOGAERTS, J.; LEPAGE, P.; ROUVROY, D.; VANDEPITTE, J. *Cryptosporidium* spp., a frequent cause of diarrhea in central Africa. **Journal of Clinical Microbiology**, v. 20, p. 874-876, 1984.
- 18 MATHAN, M. M.; VENKATESAN, S.; GEORGE, R.; MATHEW, M.; MATHAN, V. I. *Cryptosporidium* and diarrhoea in southern Indian children. **Lancet**, v. 2, p. 1172-1175, 1985.
- 19 MA, P.; VILLANUEVA, T. G.; KAUFMAN, D.; GILLOOLEY, J. F. Respiratory cryptosporidiosis in the acquired immune deficiency syndrome: use of modified cold Kinyoun and Hemacolor stains for rapid diagnoses. **Journal of American Medical Association**, v. 252, p. 1298-1301, 1984.
- 20 STENZEL, D. J.; BOREHAM, P. F. L. *Blastocystis hominis* revisited. **Clinical Microbiology Reviews**, v. 9, n. 4, p. 563-584, 1996.
- 21 MATA, L.; BOLANOS, H.; PIZZARO, D.; VIVES, M. Cryptosporidiosis in children from some highland Costa Rican rural and urban areas. **American Journal of Tropical Medicine and Hygiene**, v. 33, p. 24-29, 1984.
- 22 HOREN, W. P. Detection of *Cryptosporidium* in human fecal specimens. **Journal of Parasitology**, v. 69, p. 622-624, 1983.
- 23 BAXBY, D.; GETTY, B.; BLUNDELL, N.; RATCLIFFE, S. Recognition of whole *Cryptosporidium* oocysts in feces by negative staining and electron microscopy. **Journal of Clinical Microbiology**, v. 19, p. 566-567, 1984.
- 24 STIBBS, H. H.; ONGERTH, J. E. Immunofluorescence detection of *Cryptosporidium* oocysts in fecal smears. **Journal of Clinical Microbiology**, v. 24, n. 4, p. 517-521, 1986.
- 25 YAMADA, M.; YOSHIKAWA, H.; TEGOSHI, T.; MATSUMOTO, Y.; YOSHIKAWA, T.; SHIOTA, T.; YOSHIDA, Y. Light microscopical study of *Blastocystis* spp. in monkeys and fowls. **Parasitology Research**, v. 73, p. 527-531, 1987.
- 26 BOREHAM, P. F. L.; STENZEL, D. J. *Blastocystis* in human and animals: morphology, biology and Epizootiology. **Advanced Parasitology**, v. 32, p. 1-70, 1993.
- 27 TAN, H. K.; ZIERDT, C. K. Ultrastructure of

- Blastocystis hominis*. **Zentralblatt Fur Bakteriologie, Parasitenkunde, Infektionskrankheiten Und Hygiene**, v. 42, p. 315-324 1973.
- 28 ZIERDT, C. H.; TAN, H. K. Ultrastructure and light microscope appearance of *Blastocystis hominis* in a patient with enteric disease. **Zentralblatt Fur Bakteriologie, Parasitenkunde, Infektionskrankheiten Und Hygiene**, v. 50, p. 277-283, 1976b.
- 29 PHILLIPS, B. P.; ZIERDT, C. H. *Blastocystis hominis*: Pathogenic potential in human patient and in gnotobiotics. **Experimental Parasitology**, v. 39, p. 358-364, 1976.
- 30 PANAYOTATOU, A. Sur la blastocystose. Trois cao d'enterite a *Blastocystis hominis*. **Bulletin de la Société de Pathologie Exotique Filiales**, v. 21, p. 755-760, 1928.
- 31 ZIERDT, C. H.; TAN, H. K. Endosymbiosis in *Blastocystis hominis*. **Experimental Parasitology**, v. 39, p. 422-430, 1976a.
- 32 RITCHIE, L. S. An ether sedimentation technique for routine stool examination. **Bulletin of US Army Medical Department**, v. 8, p. 326, 1948.
- 33 KOVATCH, R. M.; WHITE, J. D. Cryptosporidiosis in two juveniles rhesus monkeys. **Veterinary Pathology**, v. 9, p. 426-440, 1972.
- 34 COCKRELL, B. Y.; VALERIO, M. G.; GARNER, F. M. Cryptosporidiosis in the intestines of rhesus monkeys (*Macaca mulatta*). **Laboratory Animal Science**, v. 24, p. 881-887, 1974.
- 35 BRYANT, J. L.; STILLS, H. F.; MIDDLETON, C. C. Cryptosporidia in squirrel monkeys (abstract 6). Proceedings, 34<sup>th</sup> Annual Session of the American Association for Laboratory Animal Science. Casemore DP, Jackson FB 1984. Hypothesis: cryptosporidiosis in human beings is not primarily a zoonosis. **Journal of Infection**, v. 9, p. 153-156, 1983.
- 36 WILSON, D. W.; DAY, P. A.; BRUMMER, M. E. G. Diarrhea associated with *Cryptosporidium* spp. in juveniles macaques. **Veterinary Pathology**, v. 21, p. 447-450, 1984.
- 37 GÓMEZ, M. S.; GRACENEA, M.; GOSÁLBEZ, P.; FELIU, C.; ENSEÑAT, C.; HIDALGO, R. Detection of oocysts of *Cryptosporidium* in several species of monkeys and in one prosimian species at the Barcelona zoo. **Parasitology Research**, v. 78, p. 619-620, 1992.
- 38 MURIUKI, S. M. K.; MURUGU, R. K.; MUNENE, E.; KARERE, G. M.; CHAI, D. C. Some gastro-intestinal parasites of zoonotic (public health) importance commonly observed in old world non-human primates in Kenya. **Acta Tropica**, v. 71, p. 73-82, 1998.
- 39 MCCLURE, H. M.; STROBERT, E. A.; HEALY, G. R. *Blastocystis hominis* in a pig-tailed macaque: a potential enteric pathogen for nonhuman primates. **Laboratory Animal Science**, v. 30, n. 5, p. 890-894, 1980.
- 40 NIZEYI, J. B.; SEBUNYA, D.; DASILVA, A. J.; CRANFIELD, M. R.; PIENIAZEK, N. J.; GRACZYK, T. K. Cryptosporidiosis in people sharing habitats with free-ranging mountain gorillas (*Gorilla gorilla beringei*), Uganda. **American Journal of Tropical Medicine Hygiene**, v. 66, n. 4, p. 442-444, 2002.
- 41 YOSHIKAWA, T.; WU, Z.; NAGANO, I.; TAKAHASHI, Y. Molecular comparative studies among *Blastocystis* isolates obtained from humans and animals. **Journal of Parasitology**, v. 89, n. 3, p. 585-594, 2003.
- 42 REDMAN, D. R.; CROSS, R. F.; HANCOCK, D. D. Application of a methylene blue-eosin stain for detecting *Cryptosporidium* spp. in bovine fecal or intestinal smears. **Annual Proceedings of American Association of Veterinary Laboratory Diagnoses**, v. 26, p. 231-240, 1983.