

# Analysis of the brainstem internal morphology of the capuchin monkey (*Cebus apella*)

## *Análise da morfologia interna do tronco encefálico de macaco-prego (Cebus apella)*

Karina do Valle MARQUES<sup>1</sup>; Mariana Matera VERAS<sup>2</sup>; Zenon SILVA<sup>3</sup>; Flavia de OLIVEIRA<sup>4</sup>; Daniela Cristina O. SILVA<sup>5</sup>; Irvênia Luiza S. PRADA<sup>6</sup>; Edson A. LIBERTI<sup>4</sup>

<sup>1</sup>Federal University of Tocantins, School of Medicine, Palmas-TO

<sup>2</sup>Laboratory of Experimental Air Pollution, Department of Pathology, School of Medicine, University of São Paulo, São Paulo-SP

<sup>3</sup>Department of Morphology Federal University Goiás, Goiânia-GO

<sup>4</sup>Institute of Biomedical Science, Department of Anatomy, University of São Paulo, São Paulo-SP

<sup>5</sup>University of Campinas, School of Odontology, Campinas-SP

<sup>6</sup>Department of Surgery, College of Veterinary Medicine, University of São Paulo, São Paulo-SP

### Abstract

The gross anatomy and the internal morphology of the brainstem of the monkey *Cebus apella* were described based on the observations made on adult brainstems. Six adult *Cebus apella* monkeys were used for anatomical observations and for the study of the internal morphology they were cut into serial sections at six different levels (pyramidal decussation; superior portion of the olive; inferior portion of the olive; pons; superior colliculus and inferior colliculus) and properly stained for studies of the internal structure. Our results show that the *Cebus apella* brainstem is characterized by the presence of a bulbopontine sulcus; an enlarged brainstem, particularly of the medulla oblongata, with a consequent lateralization of the trapezoid body, the presence of inferior olivary complex, the apparent origin of cranial nerves distant from the pyramids and of its decussation; presence of the antero-lateral sulcus separating the pyramids of the olives; expressive development of the trapezoid body, of the pons, nuclei of the pons and of the cerebral peduncle. These results are consistent with previous descriptions for other primates and suggest that the organization and development of the Brainstem structures share similarities with superior primates including humans which reflect the motor abilities of the studied species.

**Keywords:** Brainstem. Medulla oblongata. Pons. Midbrain. *Cebus apella*.

### Resumo

A anatomia e a morfologia interna do tronco encefálico (TE) do macaco-prego (*Cebus apella*) foram descritas com base nas observações feitas em troncos encefálicos de macacos adultos. Seis macacos *Cebus apella* adultos foram utilizados para as observações anatômicas. Para os estudos da morfologia interna os TE foram cortados seriadamente em seis níveis diferentes: decussação piramidal, porção superior da oliva, porção inferior da oliva, ponte, colículo superior e colículo inferior. Após esse procedimento eles foram corados com a técnica de Mulligan modificada por nós. Nossos resultados mostram que o TE de *Cebus apella* é caracterizado pela presença do sulco bulbo-pontino, aumento do tamanho do TE, especialmente da medula oblonga, com consequente lateralização do corpo trapezoide, presença do sulco ântero-lateral separando as pirâmides das olivas; desenvolvimento expressivo do corpo trapezoide, da ponte, dos núcleos da ponte e do pedúnculo cerebral. Estes resultados são consistentes com descrições prévias para outros primatas na literatura e sugerem que a organização e desenvolvimento do TE exhibe semelhanças com primatas superiores, incluindo o homem, o que reflete as habilidades motoras da espécie estudada.

**Palavras-chave:** Tronco encefálico. Medula oblonga. Ponte. Mesencéfalo. *Cebus apella*.

### Introduction

The brainstem is a sub-cortical structure located at the junction between the brain and the spinal cord. The cranial nerves (with the exception of I and II) originate in the brainstem, which includes the mid-brain, the pons, and the medulla oblongata. The Brainstem provides the main motor and sensory in-

#### Correspondence to:

Karina do Valle Marques  
Fundação Universidade Federal do Tocantins, Curso de Medicina  
Campus Universitário de Palmas. Av: NS 15 ALCNO 14; Bloco BALA, Sala  
10/D (Coordenação de Medicina/UFT)109 Norte  
CEP: 77020-210 - Palmas, TO - Brasil  
Phone: (63) 3232-8158  
e-mail: karinadovalle@uft.edu.br

Received: 15/01/2009

Approved: 29/10/2009

**Grant support:** This work was supported by Fundação de Amparo à Pesquisa do Estado de São Paulo - FAPESP 03/03446-8

nerve to the face and neck via the cranial nerves. The brainstem encompasses three neural centers: the medulla, pons, and midbrain. Neuroanatomy of some Old World Monkey is well known because they are considered important models for research in human neurophysiology. The brainstem anatomy has already been extensively studied in man, rhesus monkey (*Macaca mulatta*)<sup>1,2</sup>, gorilla (*Gorilla*)<sup>3</sup> and tarsier (*Tarsius*)<sup>4</sup>. In contrast, the South American species have not been studied so carefully. Unfortunately, for the background of this paper, relatively little seems to be known about the internal structure of the capuchin monkey brainstem.

The brown capuchin monkey (*Cebus apella*) is a New World primate from South America and member of the Cebidae family (Suborder *Haplorrhini*). It is one of the most widespread species of primates in the neotropics. Inhabits most subtropical or tropical forests, but has also been seen in dry forest, gallery forest, disturbed and secondary forest from northern Amazon rainforest of the Guyanas and Brazil to the west of the Rio Negro, as far north as the Orinoco in Venezuela<sup>5,6,7,8,9</sup>. These monkeys have fine manual ability, big and highly convoluted brains and are very sociable. The species is robust and stocky and lives in groups of eight to 15 animals. They have long and prehensile tails and prefers the understory and mid-canopy of the forest, but often descends from the trees to forage and play<sup>10,11,12,13,14</sup>.

The knowledge of non human primate's neuroanatomy is important not just for its intrinsic value, but also, because it offers data for a better understanding of the evolutionary process. Considering this, the purpose of this study was to describe the gross morphology and the internal structures of the brainstem in capuchin monkey (native name: macaco-prego), in order to supply important morphological aspects of the neuroanatomy of the mentioned species, which can subdivide further researches.

## Material and Method

In this research, brainstems from adult *Cebus apella* monkey were used. The specimens were obtained from IBAMA-MG (Brazilian Institute of the Environment and Renewable Resources) and consisted of six encephalons from three male and three female monkeys. Experiments were conducted in accordance with National and Institutional Guidelines for Animal Welfare. They were also approved by the School of Veterinary Medicine Review Board for Experimental Studies. Encephalons were transported to the Laboratory of Anatomy of the Federal University of Uberlândia-MG, Brazil, where they were dissected and maintained in 10% formaldehyde solution (v/v) until analysis. After gross morphology analysis, brainstems were transverse (perpendicular to the longest axis) cut into slices at six different levels (pyramidal decussation; superior portion of the olive; inferior portion of the olive; pons; superior colliculus and inferior colliculus) for the internal morphology analysis. These sections were frozen in liquid nitrogen and cut again in serially transverse sections of 60 µm thickness. These slices were prepared with the aid of a freezing microtome. All sections were retained in sequence in glass slides and stained with a modified Mulligan solution. Briefly, the slides were immersed in Mulligan I solution for four minutes, washed for two minutes in tap water, then immersed in Mulligan solution II for four minutes. After a second wash, they were immersed in Mulligan solution III. All slides were analyzed and every detail of grey substance delineated in transparent paper. The photographs were obtained by scanning the slides (Scanner Genius Colorp. HR-7X USB Slim). The anatomical terms are referred according to the International Anatomical Terminology<sup>15</sup> and to Gerhard and Olszewski<sup>16</sup>.

## Results

The brainstem major subdivisions (pons, midbrain, medulla oblongata) were not well delimited (Figures 1A e 1B). The midbrain is the short, constricted portion which connects the pons and cerebellum with the thalamencephalon and the cerebral hemispheres. It is directed upward and forward and was constituted by: a ventrolateral portion, composed of a pair of cylindrical bodies, named the cerebral peduncles. The depressed area between the cerebral peduncles is termed the interpeduncular fossa; a dorsal portion, consisting of four rounded eminences, named the corpora quadrigemina (Superior colliculus and

Inferior colliculus); an intervening passage or tunnel known as the cerebral aqueduct, which represents the original cavity of the midbrain and connects the third with the fourth ventricle.

The pons was situated in front of the cerebellum (Figure 1A). From its superior surface the middle cerebellar peduncle emerged from either side of the middle line. Its dorsal or posterior surface (pars dorsalis pontis), triangular in shape, was hidden by the cerebellum, and was bounded laterally by the superior cerebellar peduncle; forming the upper part of the rhomboid fossa (Figure 1B). The medulla oblongata extended from the lower margin of the pons to a

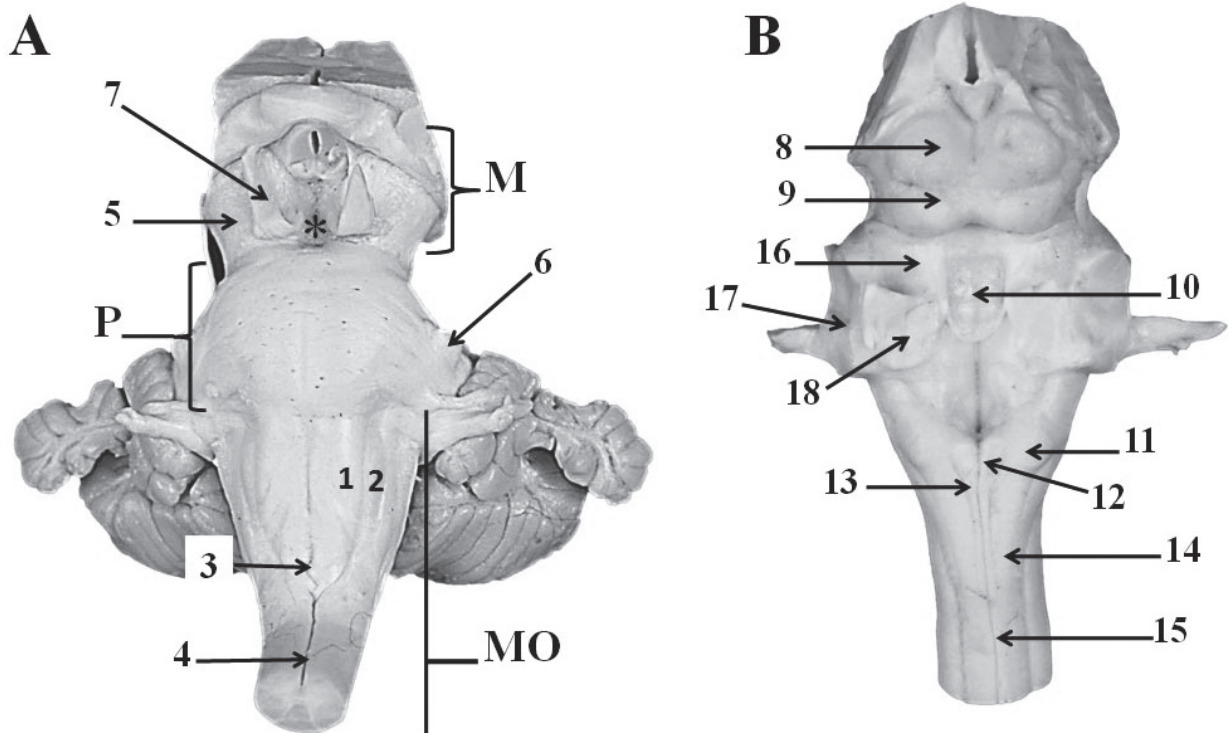


Figure 1 A - Ventral view of the brainstem , B-Dorsal view of the brainstem : 1) pyramids; 2) olive; 3) pyramidal decussation; 4) anterior median fissure; 5) cerebral peduncles; 6) trigeminal nerve; 7) oculomotor nerve; 8) Superior colliculus; 9) Inferior colliculus; 10) superior medullary velum;11) cuneate tubercle; 12) gracilis tubercle; 13) fasciculus gracilis; 14) fasciculus cuneatus; 15) posterior median sulcus; 16) Superior cerebellar peduncle; 17) Middle cerebellar peduncle; 18) Inferior cerebellar peduncle; \* Interpeduncular fossa; M = midbrain, P = pons; MO = medulla oblongata

region passing transversely below the pyramidal decussation and above the first pair of cervical nerves. Its anterior surface was separated from the anterior median fissure, termed the foramen cecum. Its lower part was interrupted by bundles of fibers which crossed obliquely from one side to the other, and constituted the pyramidal decussation. Its anterior surface was separated from the posterior median sulcus. The olive (oliva; olivary body) was situated lateral to the pyramid, from which it was separated by the antero-lateral sulcus, and the fibers of the hypoglossal nerve (Figure 1A). The superior medullary velum was a thin, transparent lamina of white substance, on the dorsal surface, which stretches between the superior cerebellar peduncle. In the dorsal surface, two fasciculi were apparent - a medial, named fasciculus gracilis; and a lateral, named fasciculus cuneatus, which ended, in the nucleus gracilis and nucleus cuneatus respectively. In the dorsal view of the brainstem we could distinguish the inferior cerebellar peduncle,

which connects the medulla oblongata to the cerebellum (Figure 1B).

All transverse sections at three different levels of the medulla oblongata were analyzed. At the three different levels the structure of the medulla oblongata changed gradually. The medulla oblongata presented a central channel; which became wider as it approximates to the lateral recess. In the bulbo-pontine junction, nearly the lateral recess we could distinguish the dorsal cochlear nerve nucleus. The medial and lateral vestibular nuclei could also be observed at this level. In this region three of the cranial nerve nucleus could be noted: the abducens nerve, vestibular nerve, cochlear nerve and the facial nerve nuclei. Concerning the trigeminal nerve, the spinal tract nucleus and the motor nucleus were present. The nucleus of the glossopharyngeal nerve was positioned nearly the inferior olivary complex. The inferior cerebellar peduncle was situated in the inferior part of the bulb. Others nuclei and medulla oblongata structures are depicted in figures 2A and 2B.

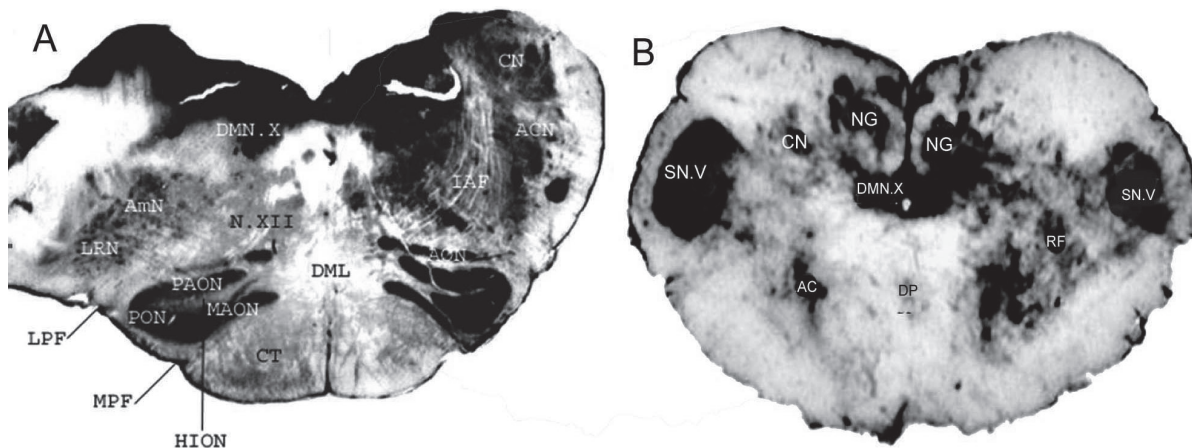


Figure 2 A - Transverse section of the medulla oblongata at the area postrema and the inferior olive level. Cuneate nucleus (CN); Accessory cuneate nucleus (ACN); Internal arcuate fibers (IAF); Accessory olivary nucleus (AON); Decussation of the medial lemniscus (DML); Corticospinal tract (CT); Dorsal motor nucleus of the vagus nerve (DMN.X); Ambiguous nucleus (AmN); Lateral reticular nucleus (LRN); Hypoglossal nerve (N.XII); Posterior accessory olivary nucleus (PAON); Principal olivary nucleus (PON); Medial accessory olivary nucleus (MAON); Hilus of the inferior olivary nucleus (HION); Lateral paraolivary fissure (LPF); Medial paraolivary fissure (MPF). B) Cross section of the medulla oblongata at the level of the decussation of the pyramids. Spinal nucleus of the trigeminal nerve (SN.V); Cuneate nucleus (CN); *Nucleus gracilis* (NG); Dorsal motor nucleus of the vagus nerve (DMN.X); Accessory nucleus (AC); Decussation of the pyramids (DP); Reticular formation (RF)

For the study of the internal morphology of the pons, transverse sections were done at two different levels according to the apparent origin of the trigeminal nerve. The medulla oblongata's reticular formation was continuous in the pons. In the basilar position irregular masses of grey matter could be observed, they corresponded to the pontine nuclei, which was intermingled by longitudinal and transverse bundles of fibers of white matter. The trapezoid body was localized in the central portion of the reticular formation. In the pons the trigeminal motor nucleus, the raphes pontine nuclei, and the superior olivary nucleus could be distinguished (Figure 3).

For the study of the internal morphology of the midbrain, transverse sections were done at two different levels according to the superior and inferior colliculi (Figure 4). The lamina quadrigemina of the midbrain was occupied by four small swellings or eminences, the anterior and posterior corpora quadrigemina, or the superior and the inferior colliculi. On transverse section, each peduncle seemed to consist of a dorsal and a ventral part, separated by a deeply pigmented lamina of gray substance, termed the substantia nigra. On the ventral surface of the midbrain, two large, lon-

gitudinally running bundles of fibers could be found. These were the cerebral peduncles. The nucleus of the oculomotor nerve was situated near the longitudinal medial fascicle. The lateral lemniscus (*lemniscus lateralis*) passes through the midbrain's surface along its lateral sulcus, and ends at the inferior colliculus. The cerebral aqueduct was circunded by a thick layer of grey matter, intermingled by layers of white matter, which represents the *stratum griseum* and the *stratum profundus*. The red nucleus was situated in the anterior part of the tegmentum, and the interpeduncular nucleus was localized near the median raphes of the tegmentum.

## Discussion

The brainstem of *Cebus apella* is well developed, similar to the human structure. When compared to *Tarsius*<sup>8</sup>, *Tupaia*<sup>16</sup> and *Macaca mulatta*<sup>17</sup>, the *Cebus*' Brainstem structures are more evident and well defined. Although, monkeys from Genus *Saimiri* and *Ateles* have well developed pontine nuclei. We didn't perform comparative measurements, however it is possible to observe that the brainstem of the *Cebus*

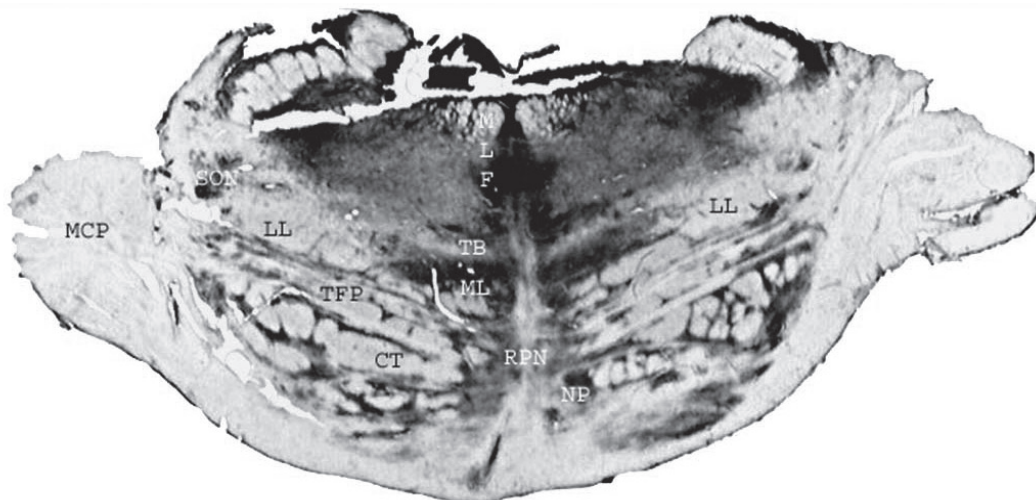


Figure 3 - Cross section of the pons at the level of the trigeminal nerve. Middle cerebellar peduncle (MCP); Superior olivary nucleus (SON); Lateral lemniscus (LL); Transverse fibers of the pons (TFP); Corticospinal tract (CT); Medial longitudinal fasciculus (MLF); Trapezoid body (TB); Medial lemniscus (ML); Raphes pontine nuclei (RPN); pontine nuclei (NP)

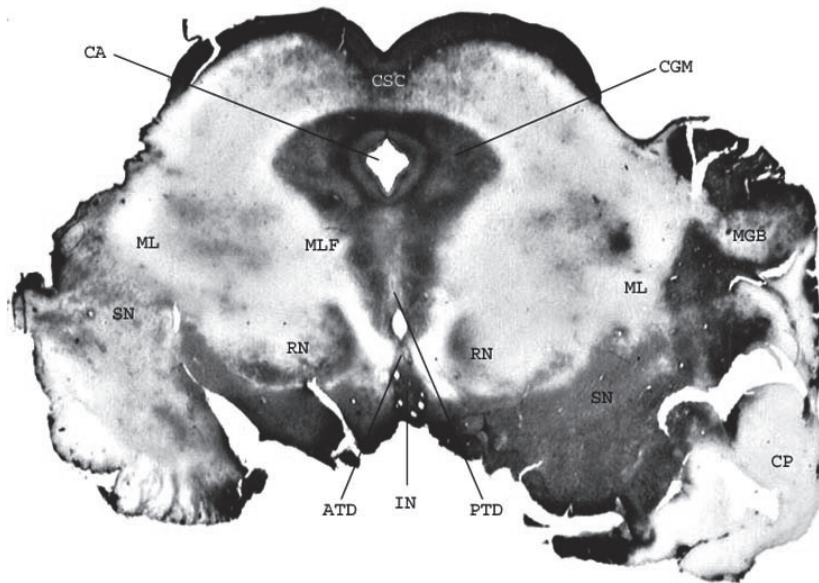


Figure 4 - Cross section of the midbrain at the level of the superior colliculi. Commissure of the superior colliculus (CSC); Cerebral aqueduct (CA); Central gray matter (CGM); Medial lemniscus (ML); Substantia nigra (SN); Medial longitudinal fascicle (MLF); Red nucleus (RN); Anterior tegmental decussation (ATD); Posterior tegmental decussation (PTD); Interpeduncular nucleus (IN); Medial geniculate body (MGB); Cerebral peduncle (CP)

*apella* exhibits larger amount of gray matter in relation to the descriptions for other primates, although in less extent than in man.

We observed that in *Cebus apella*, the brainstem has a large latero-lateral diameter; this condition is similar to humans and other superior primates. Our analysis on the internal structure of the Brainstem indicated that this increased diameter is due to more developed olives and emergent roots of the cranial nerves and to the absence of the trapezoid body, as observed by Gerhard and Olszewski<sup>16</sup> in other primates. The olives are elongated and evidents in the medulla oblongata of the *Cebus apella*; Hill<sup>18</sup> also described this feature in *Alouatta*. The olives are separated from the piramides by the antero-lateral sulcus and postero-lateral sulcus. As described by Reis<sup>17</sup> in marmosets (*Sagui*) the antero-lateral sulcus in *Cebus* is evident. Olives of the *Cebus apella* are well marked structures, although they exhibit a lesser development when compared to the human olives. The level of development of the olivar components are correlated to the

motor abilities of the species<sup>19</sup>. The ventrolateral dislocation of structures primary located in ventral position was first noted in *Cercocebus* and *Papio* becoming more evident in Anthropoid and in humans.

Gerhard and Olszewski<sup>16</sup> proposed that the enlargement of the brainstem, particularly of the medulla oblongata, with displacement of internal structures for lateral positions seems to represent an indicative sign of evolution of the species. Gerhard and Olszewski<sup>16</sup> also observed that the pyramidal decussation in *Tarsius* and *Lemur catta* could be easily identified, as well as we verified in *Cebus apella*. But in other groups such as *Tupaia* it is not visible. Comparing *Macaca mullata* (old world monkey) to *Atelles* (new world monkey), Gerhard and Olszewski<sup>16</sup> noted that in *Macaca* the pyramidal decussation was more extensive. And in *Gorilla* when compared to *Pan* the pyramidal decussation was more marked<sup>16</sup>. Certainly, these variations are associated to functional aspects linked to the motricity.

The trapezoid body of *Cebus apella* is also a well developed structure. Reis<sup>17</sup> verified in marmoset (*Callithrix*) and Tilney<sup>4</sup> in *Tupaia*, that these species also present marked trapezoid bodies. In the comparative study of Watanabe<sup>20</sup>, he found that the trapezoid body of *Cebus apella* was larger than that of *Callithrix*. It is known that the trapezoid body presents considerable morphologic variability among different species<sup>4,16</sup>. Our evaluation of the trapezoid body, as well as other structures of the brainstem of *Cebus apella* is based on observations of thick slices colored by a modified Mulligam method, differing from previous methodologies<sup>2,16,21</sup>.

Comparing our data to the study of Carpenter<sup>21</sup>, the pyramidal tract of *Cebus paella* seems to be very similar to the humane's. Gerhard and Olszewski<sup>16</sup> described that the pyramidal tract of Potto (*Perodicticus potto*), is robust when compared to *Macaca mullata* and *Cercopithecus*. In other genus like *Tarsius* and *Tupaia* the pyramidal tract was visible, although very small. Considering these observations, we could note that the pyramidal tract of the *Cebus apella* is anatomically closer to the human than to those of inferior primates. Hill<sup>22</sup> and other authors<sup>16,17,23</sup> have described a well developed pyramidal tract in other Haplorhine (marmosets) and in Catarrhine. The internal arcuate fibers are separated and distinct in the *Cebus apella*, similar as in Man as described by Crosby and Woodburne<sup>2</sup> and Carpenter<sup>21</sup>. Gerhard and Olszewski<sup>16</sup> describe that the internal arcuate fibers in *Tupaia* could not be seen, although in *Lorisiformes*, *Lemur* and *Callithrix*, they were more evident. In *Perodicticus potto* the internal arcuate fibers are also evident.

The medial longitudinal fascicle of internal arcuate fibers in *Cebus apella* is clearly visible as in humans<sup>2,21</sup> and in other primates such as *Tarsius*, *Lemur*, *Marmoset*, *Mycetes*, *Monkeys*, *Baboon*, *Gibon*, *Orangutan*, *Chimpanzee*, *Gorilla*<sup>16</sup>.

The posterior longitudinal fasciculus was equally developed in the *Cebus apella* as in human<sup>2</sup>.

In *Cebus* as in many species of primates the cuneate nucleus, the gracile nucleus, the accessory and principal nucleus of the trigeminal nerve were well developed and localized in the medulla oblongata as previous described in human<sup>2</sup>, *Cebus*<sup>20</sup> and *Gorilla*<sup>3</sup>.

However, some minor differences can occur in the level of development of some nuclei, such as the cuneate and gracile nuclei. In *Tupaia*<sup>16</sup> they were very small.

The olivary complex of the *Cebus apella* is well developed, being constituted by a main olivar nucleus, a posterior and a medial accessory olivar nucleus similar to humans<sup>2,21</sup> and marmosets<sup>16</sup>, and these similarities may be explained by the fact that all have fine motor abilities.

In *Cebus apella*, the pontine nucleus was localized between numerous longitudinal and transverse fibers of the pons, similar to the description given for human<sup>21</sup>. Reis<sup>17</sup> pointed that in marmosets the traverse fiber of the pons are scarce. The superior olivary nucleus of the *Cebus apella* presents similar localization and characteristics to humans<sup>2,21</sup>.

The internal morphology of the midbrain in *Cebus apella* was also very similar to previous description for other species, including human<sup>2,21</sup> and marmosets<sup>16</sup>. Hines<sup>24</sup> affirmed that the corpora quadrigemina of *Macaca mulatta* were proportionally smaller than the human corpora quadrigemina.

The lamina quadrigemina of the midbrain in *Cebus apella* is occupied by four small swellings or eminences, the anterior and posterior corpora quadrigemina, or the superior and the inferior colliculi. Tilney<sup>4</sup> affirms that the corpora quadrigemina of *Tarsius* are larger than in other primates such as *Lemur*, *Marmoset*, *Mycetes*, *Monkeys*, *Baboon*, *Gibon*, *Orangutan*, *Chimpanzee*, *Gorilla* and the Man. Hill<sup>18</sup> pointed out that in superior species of primates the corpora quadrigemina are larger than in *Strepsirhini*. Tilney<sup>4</sup> and Hill<sup>22</sup> mentioned that great colliculus were present in *Tarsius* and *Hapalae*. In *Cebus* we observed that the colliculi were not prominent structures as in *Tarsius*, although they are easily evenciated.

The disposition and organization of substantia nigra of the *Cebus apella* was similar to the humans brain<sup>2,21</sup>. The substantia nigra belongs to the complex motor circuits, so not surprisingly, we found a well developed substantia nigra in this species that exhibit elaborated manual abilities. The other visible structures in the midbrain of *Cebus apella* maintained the same similarities with the descriptions done for humans<sup>2,21</sup> and for other primates<sup>1,4,16</sup>.

In the *Cebus apella* we could identify the nuclei of the following cranial nerves: hypoglossal nucleus, nucleus of the solitary tract, dorsal motor nucleus of the vagus, glossopharyngeal nucleus, spinal tract nucleus of the trigeminal nerve, vestibular nuclei, abducens nucleus, vagus nucleus and facial nucleus. These nuclei were also described in *Macaca mulatta*<sup>1</sup>, in *Gorilla*<sup>3</sup>, *Pan*, *Hylobates*, *Papio*, *Cercocebus*, *Cercopithecus*, *Perodicticus potto*, *Lemur* and *Tupaia*<sup>16</sup>. The pattern of cranial nerves nuclei distribution and localization seems to follow a general primate model.

## Conclusion

In summary, the brainstem of *Cebus apella* has structures which dispositions, characteristics and level of development are indicators of evolution, such as the presence of the bulbopontine sulcus; enlargement of the brainstem (particularly of the medulla oblongata) with consequent laterization of the trapezoid body, presence of inferior olivary complex, apparent origin of cranial nerves distant from the pyramids and of its decussation; presence of the antero-lateral sulcus separating the pyramids of the olives; expressive development of the trapezoid body, of the pons, nuclei of the pons and of the cerebral peduncle. These results are consistent with previous descriptions for other primates and suggest that the organization and development of the brainstem structures share similarities with superior primates including humans which reflect the motor abilities of the studied species.

## References

- CHRISTENSEN, K. The cranial nerves. In \_\_\_\_\_. **The anatomy of the rhesus monkey (*Macaca mulatta*)**. New York: Hafner Publishing CO, 1933. chap. 15, p. 290-306.
- CROSBY, E. C.; WOODBURN, R. T. The nuclear pattern of the non-tectal portions of the midbrain and isthmus in primates. **The Journal of Comparative Neurology**, v. 78. n. 3, p. 441-520, 1943.
- NOBACK, C. R. Brain of a gorilla. II. Brain Stem Nuclei. **The Journal of Comparative Neurology**, v. 111, n. 2, p. 345-373, 1959
- TILNEY F. The brainstem of tarsius. A critical comparison with other primates. **The Journal of Comparative Neurology**, v. 43, n. 3, p. 371-432, 1927.
- EMMONS, L. **Neotropical rainforest mammals**. Chicago and London: The University of Chicago Press, 1990.
- FORBES, P. B.; MACKETH, R. P. **All The World's animals: primates**. New York, Toronto: Torstar Books, 1984.
- KINZEY, W. **New world primates: ecology, evolution, and behavior**. New York: Aldine De Gruyter, 1989.
- NOWAK, R. **Walker's mammals of the world**. 5. ed. Baltimore: The Johns Hopkins University Press, 1991.
- ROWE, N. **The pictorial guide to the living primates**. New York: Pogonias Press, 1996.
- DEFLER, T. R. On the ecology and behavior of *Cebus albifrons* in eastern Colombia. **Primates**, v. 20, p. 475-502, 1979.
- DEFLER, T. R. **Primates of Colombia**. Bogotá: Conservation International, 2004. p. 550.
- FRESE, C. H.; OPPENHEIMER, J. R. The capuchin monkeys, genus *Cebus*. In: COIMBRA FILHO, A. F.; MITTERMEIER, R. A. **Ecology and behavior of neotropical primates**. Rio de Janeiro: Academia Brasileira de Ciência, 1981. 496 p.
- AURICHIO, P. **Primates do Brasil**. São Paulo: Terra Brasilis, 1995. p. 35.
- SUSSMAN, R. W. **Primate ecology and social structure: new world monkeys**. Needham Heights: Pearson Custom Publishing, 2000. 207 p.
- \_\_\_\_\_. **Terminologia anatomia internacional**. 1. ed. São Paulo: Manole, 2001. p. 131-134.
- GERHARD, L.; OLSZEWSKI J. Medulla oblongata and pons. In: \_\_\_\_\_. **Primatologia, handbuch der primatenkunde**. New York: [s.n.]. 1969. p. 3-209.
- REIS, F. P. **Considerações macro e microscópicas sobre o encéfalo de Sagüi (*Callithrix jacchus* - Linnaeus, 1758)**. 1975. 67 f. Dissertação (Mestrado) - Escola Paulista de Medicina de São Paulo, São Paulo, 1975.
- HILL, W. C. O. **Primates: comparative anatomy and taxonomy**. New York: Interscience Publishers. 1962. 439 p.
- RESENDE, B. D.; OTTONI, E. B. Play and tool use learning in tufted capuchin monkeys (*Cebus apella*). **Estudos de Psicologia (Natal)**, v. 7, n. 1, 2002. Disponível em: <<http://www.scielo.br/pdf/epsic/v7n1/10965.pdf>>. Acesso em: 20 May 2008.



20. WATANABE, I. Comparative study of the medulla oblongata, pons, midbrain and cerebellum of the tufted capuchin, *Cebus apella* (Linnaeus, 1758). **Revista de Odontologia da UNESP**, v. 11, n. 1/2, p. 13-25, 1982.
21. CARPENTER, M. B. **Neuroanatomia humana**. Rio de Janeiro: Intramericana, 1978. 700 p.
22. HILL, W. C. O. **Primates: comparative anatomy and taxonomy**. II Haplorhini Tarsoidea. Edinburgh: University Press, 1955. 78 p.
23. HILL, W. C. O. **Primates: comparative anatomy and taxonomy**. VI Catarrhini Cercopithecoidea Cercopithecus. Edinburgh: University Press. 1966. 106 p.
24. HINES, M. The external morphology of the brain and the spinal cord. In: \_\_\_\_\_. **The anatomy of the rhesus monkey (*Macaca mulatta*)**. New York: Hafner Publishing CO, 1993. chap 14, p. 275-287.