

EXCRETORY UROGRAPHY IN DOGS AND CATS. III. ABDOMINAL DISORDERS

MASAO IWASAKI
Professor Associado
Faculdade de Medicina Veterinária e
Zootecnia da USP

BENEDICTO WLADEMIR DE MARTIN
Professor Titular
Faculdade de Medicina Veterinária e
Zootecnia da USP

IWASAKI, M. & DE MARTIN, B.W. Excretory urography in dogs and cats. III. Abdominal disorders. *Braz. J. vet. Res. anim. Sci.*, São Paulo, 27(1):83-89, 1990.

SUMMARY: Excretory urography was performed in 256 dogs and 21 cats clinically suspected of having abdominal disorders, except for the urinary system. The enlargements of the liver, spleen, uterus, prostate gland as well as the presence of intrabdominal masses appear with an increased radiographic density due to the sodium diatrizoate contrast medium. The best visualizations of these alterations were found in a higher frequency after 15 minutes following the injection of the contrast medium. These findings considerably widened the diagnostic possibilities.

UNITERMS: Abdominal diseases; Radiograph, excretory urography; Contrast medium, sodium diatrizoate; Dogs; Cats

INTRODUCTION

The radiographic examination of the abdominal cavity in animals often presents difficulties during interpretation, mainly due to superimposition of organs and anatomic structures, besides the digestive contents, sometimes present.

In order to widen the spectrum of anatomic and physiologic radiographic observations, several non-contrast and contrast techniques were developed.

From our experience using excretory urography in dogs and cats, changes in density in organs such as the spleen and the liver were observed.

These findings have motivated us to extend the application of this technique when in the presence of clinical evidences of disorders located in the

abdominal cavity involving organs not belonging to the urinary system.

More specifically, we tried to produce densifications of enlarged organs such as the liver, spleen, uterus or prostate due to several pathologies or in cases of abdominal tumors when the initial clinical evaluation could not determine their origin.

The time needed for the best visualization of the radiographic alterations, following the injection of the contrast medium, was also analysed in this work.

LITERATURE

A great number of researchers have dedicated their work to contrast techniques in the study of the organs of the abdominal cavity.

Techniques employed in the study of the digestive system were extensively reported. In order to study other abdominal organs several techniques were preconized, among them, the pneumoperitoneography has been the most reported one. This technique enables the evaluation of the silhouette of the liver, spleen, kidneys, pelvic viscera and abdominal masses⁴. However, its application presents some limitations, mainly due to its risks and contra-indications⁵.

The hysterosalpingography was developed to study uterine alterations, however, its application is not frequently indicated due to technical difficulties during execution².

The excretory urography, widely reported was proposed almost exclusively to the study of the urinary system. IWASAKI & DE MARTIN³ (1986) reported some density increase in the liver and spleen, besides urinary organs, when performing this technique, and the best visualization of these organs occurred after 15 minutes following the injection of the contrast medium.

DE MARTIN et alii¹ (1984) when studying the distribution of the contrast media (sodium diatrizoate) marked with I^{131} , observed that the levels of this contrast, after 15 minutes of the injection, were stable in the hepatic and splenic parenchima while they gradually decreasing in the blood.

MATERIAL AND METHOD

ANIMALS

In the present study 277 animals were grouped, 256 dogs and 21 cats, males and females of different breeds and ages. This number represents all animals brought to the Veterinary Hospital of the Faculty of

Veterinary Medicine of the University of São Paulo, in a 8 - year period.

The animals were selected among those clinically considered suspects of having any abnormality in the abdominal cavity, represented by enlargements in the liver, spleen, uterus or prostate and also by masses which specific origin could not be determined by the initial clinical evaluation.

The animals were then submitted to survey radiographs followed by excretory urography in order to reach an accurate diagnosis.

RADIOGRAPHIC EXAMINATION

Radiographic Equipment

An X-Ray machine, Tridoros 4*, with 1000 mA maximum capability equipped with a Potter-Bucky grid was employed.

The X-Ray films were RP X-OMAT** and an automatic processing (RP-OMAT Processor***) was employed.

Preparation of Patient

The animals were given only water during the 24 hours prior to the contrast study. The colon and rectum were emptied using a contact laxative**** administrated 12 hours prior to the examination, and followed by a flushing enema*****, when necessary.

Radiographic Technique

A technique chart relating milliamperage-second and kilovoltage to the thickness of the abdomen was employed. The radiographs were taken in ventro-dorsal and left lateral views.

Contrast Technique

After survey radiographic examination, the animals were submitted to excretory urography, according to IWASAKI & DE MARTIN³ (1986), using sodium diatrizoate***** contrast medium in a dosage of 2 ml/Kg/B.W. and radiographs were taken after 5, 15 and 30 minute intervals, following the injection of the contrast medium.

** Siemens S.A.
*** Kodak Brasileira Com. e Ind. Ltda.
**** Eastman Kodak Company
***** Laxonalin - Laboratório Organon do Brasil Ltda.
***** Fleet enema - Laboratório Ayerst Ltda
***** Hypaque 50% - The Sydney Ross Co.

Radiographic Evaluation

A comparative study of all radiographs from each animal was made in order to determine when the best visualization of the radiographic alterations occurred, making possible the diagnosis of these pathologies.

Statistical Analysis

The results obtained in the present study are expressed in frequencies and its respective percentages.

RESULTS

The observations related to the dogs and cats were grouped and are shown in Tab. 1 and 2, respectively.

When comparing survey and contrast radiographs, in all cases, the radiographic alterations in the abdominal cavity, despite the underlying pathology, were better visualized during the contrast examination.

Also, the higher frequencies of the best visualizations of these alterations, in both species, occurred in radiographs taken after 15 minutes following the injection of the contrast medium.

DISCUSSION AND CONCLUSIONS

The information obtained in previous publications^{1,3} led us to study excretory urography as a diagnostic aid to the diagnosis of pathologies in abdominal organs, excluding the urinary system. The utilization of excretory urography with this purpose has not been studied by other authors.

Excretory urography does not show technical difficulties and in contrast to other techniques such as pneumoperitoneography⁴ and hysterography², accidents and contra-indications are rare³.

The sodium diatrizoate contrast medium in the dosage of 2 ml/Kg/B.W. promotes density increase in abdominal organs affected by different pathologies. This fact greatly contributes to radiographic interpretation.

The utilization of excretory urography enabled or facilitated the radiographic diagnosis of uterine, prostatic, splenic and hepatic enlargements as well as abdominal tumors. The affected organs or anatomic structures, despite the disorders showed to be equally dense.

The higher frequencies of the best visualizations

of the alterations, in both species, occurred after 15 minutes following the injection of the contrast medium.

These results confirm that the contrast medium have the property of being retained in various tissues, probably keeping constant levels after some time following the injection, while blood levels gradually decrease¹. This fact might be responsible for the differences in density observed in the abdominal cavity during this time, making more evident the morphologic aspects of the organs, very important in radiographic diagnosis.

It was not the purpose of the present study to correlate the radiographic findings with the pathologies. So, the uterine enlargements found in the radiographs were caused by different pathological or even physiological conditions, but in both cases the uterine horns appeared to be dense. The usefulness of this technique may be demonstrated, for example, in cases of uterine pathologies when survey radiographs do not reveal details and the excretory urography, by increasing the density of uterine walls, provides radiographic images that enables the diagnosis. (Fig. 1 and 2)

Concerning tumors developed in the abdominal cavity, neoplastic or not, it is possible to observe increased density in these masses and in organs such as liver, spleen, kidneys, ureters and urinary bladder, giving a panoramic abdominal pattern with a wide range of diagnostic possibilities, and also

revealing eventual complications in adjacent organs or structures. (Fig. 3 and 4)

IWASAKI, M. & DE MARTIN, B.W. Urografia excretora em cães e gatos. III. Patologias da cavidade abdominal. *Braz. J. vet. Res. anim. Sci.*, São Paulo, 27(1):83-89, 1990.

RESUMO: Empregou-se a urografia excretora em 256 cães e 21 gatos, clinicamente suspeitos de apresentarem patologias em órgãos abdominais, excetuando os do sistema urinário. Verificou-se que os aumentos de volume de fígado, baço, útero, próstata e as tumorações da cavidade abdominal, mostraram-se densificados pelo contraste à base de diatrizoato de sódio, sendo que as maiores frequências de melhores evidências destas alterações, ocorreram após 15 minutos da injeção. Estas observações ampliaram consideravelmente as possibilidades diagnósticas.

UNITERMOS: Abdome, doenças; Radiografia, urografia excretora; Meio de contraste, diatrizoato de sódio; Cães; Gatos

TABLE 1 - Frequencies (F) and respective percentages of the best visualization of radiographic images (R.I.) that enabled the diagnosis of abdominal disorders in 256 male and female dogs, of different breeds and ages, taken after 5, 15 and 30 minute intervals following the injection of sodium diatrizoate contrast medium (Hypaque 50%). São Paulo, 1989.

RADIOGRAPHIC ALTERATIONS	TIME		5 MIN		15 MIN		30 MIN		TOTAL
	R.I.	F	%	F	%	F	%		
Uterine enlargement		0	0	152	95.00	8	5.00	160	
Tumor in the abdominal cavity		0	0	49	94.23	3	5.77	52	
Prostate enlargement		0	0	23	92.00	2	8.00	25	
Hepatic enlargement		0	0	14	100.00	0	0	14	
Splenic enlargement		0	0	5	100.00	0	0	5	
		TOTAL							256

TABLE 2 – Frequencies (F) and respective percentages of the best visualization of radiographic images (R.I.) that enabled the diagnosis of abdominal disorders in 21 male and female cats, of different breeds and ages, taken after 5, 15 and 30 minute intervals following the injection of sodium diatrizoate contrast medium (Hypaque 50%). São Paulo, 1989.

RADIOGRAPHIC ALTERATIONS	TIME		5 MIN		15 MIN		30 MIN		TOTAL
	R.I.	F	%	F	%	F	%		
Uterine enlargement		0	0	16	94.12	1	5.88	17	
Tumor in the abdominal cavity		0	0	4	100.00	0	0	4	
TOTAL								21	

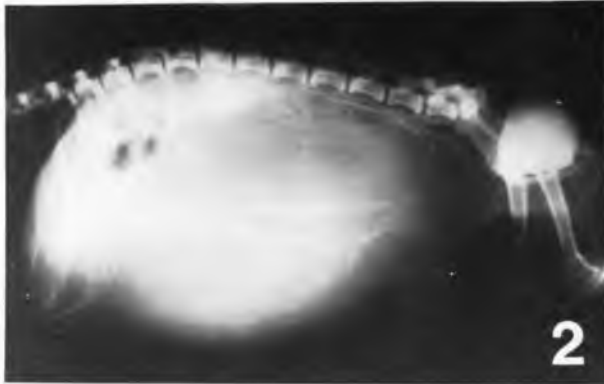
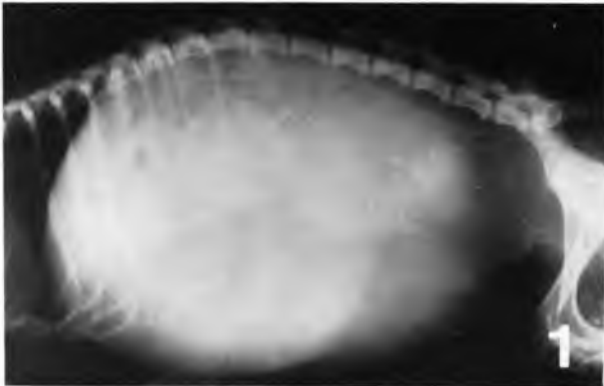


FIGURE 1 - Left lateral view of a dog showing homogenous opacity of the abdominal cavity.

FIGURE 2 - Same dog as illustrated in Fig.1. Excretory urography showing increased density in the wall of the mass involving almost the entire abdominal cavity (Pyometra).

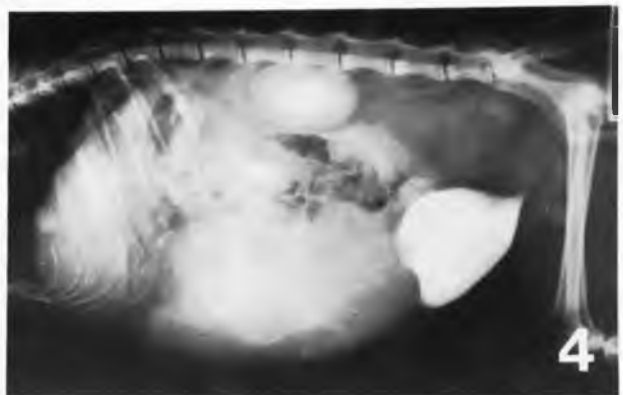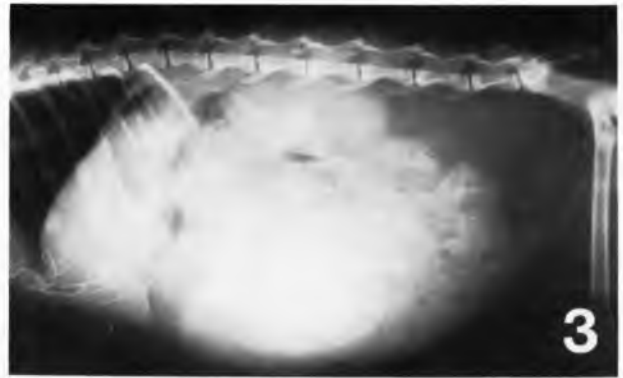


FIGURE 3 - Left lateral view of a cat showing a central abdominal mass with poorly defined margins.

FIGURE 4 - Same cat as illustrated in Fig.3. Excretory urography showing increased density of the mass and other viscera of the abdominal cavity (lymphosarcoma of the spleen).

REFERENCES

- 01-DE MARTIN, B.W.; IWASAKI, M.; FERNANDES NETO, J.M. Study of the distribution of sodium diatrizoate labelled with I^{131} , on blood, liver and spleen of dogs. *Rev. Fac. Med. Vet. Zootec. Univ. S. Paulo*, 27:107-111, 1984.
- 02-FUNKQUIST, B.; LAGERSTEDT, A.S.; LINDE, C.; OBEL, N. Hystero-graphy in the bitch. *Vet. Radiol.*, 26:12-18, 1985.
- 03-IWASAKI, M. & DE MARTIN, B.W. Urografia excretora em cães e gatos. I. Técnica. *Rev. Fac. Med. Vet. Zootec. Univ. S. Paulo*, 23:151-159, 1986.
- 04-MORGAN, J.P.; SILVERMAN, S.; ZONTINE, W.J. *Techniques of veterinary radiography*. 2.ed. Davis, Veterinary Radiology Associate, 1977. p.362-365.
- 05-O'BRIEN, T.R. *Radiographic diagnosis of abdominal disorder in the dog and cat: radiographic interpretation, clinical signs, pathophysiology*. Philadelphia, W.B. Saunders, 1978. p.48-84.

Recebido para publicação em 11/10/89
Aprovado para publicação em 13/02/90