

# Origin and distribution of the ischiatic nerve in mixed-breed sheep

## *Origem e distribuição do nervo isquiático em ovinos sem raça definida*

Bruno Gomes VASCONCELOS<sup>1</sup>; Márcia Carolina Domingues SANTOS<sup>2</sup>;  
Amilton Cesar dos SANTOS<sup>3</sup>; Diego Carvalho VIANA<sup>3</sup>; Angelita das Graças de Oliveira HONORATO<sup>2</sup>;  
Cheston César Honorato PEREIRA<sup>4</sup>; Vicente BORELLI<sup>3</sup>; Frederico Ozanam Carneiro e SILVA<sup>2</sup>

<sup>1</sup> Universidade Federal do Mato Grosso, Instituto de Ciências da Saúde, Sinop – MT, Brasil

<sup>2</sup> Universidade Federal de Uberlândia, Faculdade de Medicina Veterinária, Uberlândia – MG, Brasil

<sup>3</sup> Universidade de São Paulo, Faculdade de Medicina Veterinária e Zootecnia, São Paulo – SP, Brasil

<sup>4</sup> Universidade de Rio Verde, Rio Verde – GO, Brasil

### Abstract

Current research studied, by dissection, the origin and distribution of the ischiatic nerve in 30 fetuses of mixed-breed male or female sheep (*Ovis aries*), obtained from abortions, stillborns and natural deaths of pregnant females on farms in the Triângulo Mineiro region, state of Minas Gerais, Brazil. Formaldehyde 10% was injected through the cannulation of descending thoracic aorta and the material was kept immersed in the solution for at least 48 hours before dissection. The ischiatic nerve originated from the ventral branch of the last lumbar spinal nerve, either from the sixth lumbar spinal nerve (L6) or from the seventh (L7), when present, and from the ventral branches of first and second sacral spinal nerves (S1 and S2, respectively), and possibly from the ventral branch of third sacral spinal nerve (S3). The ischiatic nerve provided branches to the superficial gluteal, middle gluteal, accessory gluteal, deep gluteal, gemelli, quadratus femoris, adductor, biceps femoris, semitendinosus and semimembranosus muscles. The tibial and common peroneal nerves were the terminal branches of the ischiatic nerve, originating distally towards the greater trochanter of the femur bone. Wilcoxon's test (0.05) showed that statistically there were no significant differences between the frequencies of the muscular branches of the ischiatic nerve and the antimeres, regardless of the number of muscular branches.

**Keywords:** Anatomy. Innervation. Lumbosacral plexus. Small ruminants.

### Resumo

O presente trabalho estudou, por meio de dissecações, a origem e distribuição do nervo isquiático em 30 fetos de ovinos (*Ovis aries*) sem raça definida, machos ou fêmeas, obtidos de abortos, natimortos e mortes naturais de fêmeas gestantes de núcleos criatórios na região do Triângulo Mineiro, estado de Minas Gerais, Brasil. Injetou-se formaldeído a 10% por meio de canulação da aorta descendente torácica e, posteriormente, o material foi mantido submerso na referida solução por um período mínimo de 48 horas antes do início das dissecações. O nervo isquiático originou-se do ramo ventral do último nervo espinhal lombar, ora do sexto nervo espinhal lombar (L6), ora do sétimo (L7), quando presente, e dos ramos ventrais dos primeiro e segundo nervos espinais sacrais (S1 e S2, respectivamente), podendo apresentar a contribuição do ramo ventral do terceiro nervo espinhal sacral (S3). O nervo isquiático cedeu ramos aos músculos: glúteo superficial, glúteo médio, glúteo acessório, glúteo profundo, gêmeo, quadrado femoral, adutor, bíceps femoral, semitendinoso e semimembranoso. Os ramos terminais do nervo isquiático foram os nervos tibial e fibular comum, tendo suas origens distalmente ao trocânter maior do fêmur. Estatisticamente, através da aplicação do teste de Wilcoxon (0,05), não houve diferenças significativas entre as frequências dos ramos musculares do nervo isquiático e os antímeros, independentemente do número de ramos musculares.

**Palavras-chave:** Anatomia. Inervação. Plexo lombossacral. Pequenos ruminantes.

### Introduction

Although several traditional authors (SCHWARZE; SCHRÖDER, 1970; SEIFERLE, 1975; BRUNI; ZIMMERL, 1977; NICKEL; SCHUMMER; SEIFERLE, 1984; ELLENBERGER; BAUM, 1987; FRANDSON; WILKE; FAILS, 2005; DYCE; SACK; WENSING, 2010; KÖNING; LIEBICH, 2011) have highlighted the importance of the ischiatic nerve, they only

made general observations on the body's largest nerve for domestic species. However, other authors

#### Correspondence to:

Bruno Gomes Vasconcelos  
Av. Alexandre Ferronato, 1200, Setor Industrial  
CEP 78557-267, Sinop, MT, Brasil  
e-mail: vasconcelosufmt@gmail.com

Received: 27/02/2014  
Approved: 25/03/2014

described its anatomy in the dog (GHOSHAL, 1986a; EVANS, 1993; EVANS; DELAHUNTA, 2001), cat (GHOSHAL, 1986a; GUIMARÃES et al., 2005), equines (GHOSHAL, 1986b; BUDRAS; SACK; RÖCK, 2009), swine (GHOSHAL, 1986c; SANTOS et al., 2013), wild boar (IGLESIAS; SILVA; BRITO, 2011), rock cavy (LACERDA et al., 2006), galea (OLIVEIRA et al., 2010), raccoon (PEREIRA et al., 2011), *Cebus apella* (BARROS et al., 2003; AVERSI-FERREIRA et al., 2011), *Macaca mulatta* (KRECHOWIECKI; GOSCICKA, 1972), chimpanzee and *Cynocephalus anubis* (CHAMPNEYS, 1975).

Godinho, Cardoso and Nascimento (1987) reported that the ischiatic nerve in ruminants was not only the largest of the lumbosacral plexus nerves, but it originated from the L6, S1 and S2 ventral branches. Ghoshal (1986d) reported that ischiatic nerve fibers in ruminants were mainly derived from the ventral branches of the last lumbar nerve and from the first and second sacral components. However, the number may vary and depends on the number of lumbar vertebrae present. Consequently, Linzell (1959) remarked that in sheep the L7 ventral branch, when present, corroborated in the formation of the ischiatic nerve, instead of L6.

In more specific research work on crossbreed zebu cattle, Campos et al. (2003) and Ferraz et al. (2006) registered that the ischiatic nerve originated from the ventral branches of L5, L6, S1, S2 and S3, albeit with peculiar arrangements in the different papers. Further, Lima et al. (2008) reported that in 93.3% of Saanen goats, the nerve was formed by the ventral branches of L6, S1 and S2 and they even mentioned the contribution of the ventral branch of S3 in 6.7% of the specimens. Godinho, Cardoso and Nascimento (1987) analyzed the ischiatic nerve's anatomical behavior in ruminants and found that it provided branches to the biceps femoris, gemelli, quadratus femoris, adductor, semitendinosus, semimembranosus, internal obturator, external obturator and tensor fasciae latae muscles. Ghoshal (1986d) stated that, close to its emergence

from the pelvic cavity, the ischiatic nerve in ruminants innervated the gluteobiceps, semitendinosus and semimembranosus muscles.

In specific studies respectively on goats and sheep, crossbreed zebu cattle and Saanen goats, Ghoshal and Getty (1970, 1971), Campos et al. (2003) and Lima et al. (2008) informed that the ischiatic nerve provided branches to the middle gluteal, deep gluteal, gluteobiceps, gemelli, semitendinosus and semimembranosus muscles. Furthermore, Ghoshal and Getty (1970, 1971) and Campos et al. (2003) observed the innervation of the adductor muscle, whereas Ghoshal and Getty (1970, 1971) reported the presence of branches of the ischiatic nerve for the internal obturator, external obturator and quadratus femoris muscles.

Current paper analyzes the ischiatic nerve's behavior, or rather, its origin, distribution, and frequency of muscular branches as a contribution towards the study of sheep anatomy, mainly the peripheral nervous system and the spinal nerves. It may also provide data for the systematic study in comparative anatomy. In fact, the textbooks consulted restricted their descriptions to ruminants only and the scientific articles were based on cattle and goats.

## Materials and Methods

Thirty mixed-breed male and female sheep (*Ovis aries*) fetuses were used. They were obtained from abortions, stillborns and natural deaths of pregnant females on farms in the Triângulo Mineiro region, state of Minas Gerais, Brazil. Fetuses were conserved in a freezer and then thawed at room temperature. They were fixed in 10% formaldehyde aqueous solution by cannulation of descending thoracic aorta. The material was kept immersed in the formaldehyde solution for at least 48 hours prior to dissections.

So that the origin of the ischiatic nerve could be visualized, a longitudinal incision was made along the median ventral line, from the xiphoid process of the xiphoid cartilage of the sternum bone up to the caudal

border of the pelvic symphysis. Two other vertical incisions, one at each antimer, were also made up to the median dorsal line. The pelvic symphysis was cut up to the pelvic cavity and all adjacent organs were removed. A horizontal incision in the skin of the gluteal region and a vertical one in the skin of the femoral region were performed to analyze the distribution of the muscular branches. Dissections were performed in these areas and the insertions of the superficial gluteal, middle gluteal, accessory gluteal and biceps femoris muscles were sectioned to have a better view of the muscular branches of the ischiatic nerve.

The terminology for current analysis is based on the International Committee on Veterinary Gross Anatomical Nomenclature (2012). Dissection data may be found in Tables 1 and 2, by relative frequency, and in photographs (Figures 1A, B and C). Results were analyzed by Action 2.6<sup>®</sup> program and data were analyzed by Wilcoxon's paired nonparametric test at 0.05 significance level, comparing frequencies between muscular branches and antimeres, regardless to the number of branches.

## Results

Sheep revealed a variation in the number of lumbar vertebrae, or rather, 6 vertebrae in 26 specimens (86.6%) and 7 vertebrae in 4 specimens (13.3%). The ischiatic nerve in sheep originated at the ventral branch of the last lumbar spinal nerve, either at L6 or at L7, if present, and at the ventral branches of S1 and S2, with possible contribution of the ventral branch of S3. Specific arrangements were observed for each specimen with symmetry between the antimeres, right and left, in all the animals analyzed. Thus, in sheep with 6 lumbar vertebrae, the ischiatic nerve originated from the ventral branches of L6, S1 and S2 in 22 cases (73.3%) and from L6, S1, S2 and S3 in 4 cases (13.3%) (Figure 1A). In sheep with 7 lumbar vertebrae, the ischiatic nerve originated from the ventral branches of L7, S1 and S2 in 3 cases (10%) and from L7, S1, S2

and S3 in 1 case (3.3%).

The ischiatic nerve proceeded from its source and went through the greater ischiatic foramen, passed over the sacrotuberous ligament, from which the cranial and caudal gluteal arose. The cranial gluteal nerve branched to the tensor fasciae latae, accessory gluteal and deep gluteal muscles in all the sheep, but supplied branches to the middle gluteal muscle in only 10% into the right antimer (RA) and 13.3% into the left antimer (LA) (Figures 1 B and C) (Table 1). The caudal gluteal nerve supplied branches to the superficial gluteal muscle in all animal under analysis (figures 1B and C) (Table 1).

Further, running distally in the thigh, the ischiatic nerve directly supplied branches to the middle gluteal, deep gluteal, gemelli, quadratus femoris, biceps femoris, semitendinosus and semimembranosus muscles in all the specimens analyzed; adductor in 93.3% in RA and 86.6% in LA; superficial gluteal in 76.6% in RA and 60% in LA; and accessory gluteal in 43.3% in RA and 63.3% in LA (Figures 1B and C) (Table 2).

The tibial and common peroneal nerves were the terminal branches of the ischiatic nerve, derived distally from the greater trochanter of the femur bone, on the two antimeres (Figure 1C).

According to Wilcoxon's test at 0.95 confidence level, there was no significant difference between the frequency of muscular branches and antimeres, regardless of the number of muscular branches, with P-value between 0.67 and 1 (Tables 1 and 2).

## Discussion

Due to the great number of research publication on the ischiatic nerve in several animals, results of current investigation were compared and contrasted to reports of species which most resemble sheep and ruminants, especially cattle and goats.

Following the generic remarks by Godinho, Cardoso and Nascimento (1987), the ischiatic nerve in ruminants originates from the ventral branches of L6,

Table 1 – Representative table of relative frequencies (%) of the distribution in mixed-breed sheep on the right antimer (RA) and left antimer (LA); of the branches of the cranial gluteal nerve (N. gluteus cranialis) to the tensor fasciae latae (TFL), accessory gluteal (AG), deep gluteal (DG) and middle gluteal (MG) muscles; and of the branches of the caudal gluteal nerve (N. gluteus caudalis) to the superficial gluteal muscle (SG); P-value for each muscle by Wilcoxon's test (0.05) – Uberlândia, MG, Brazil – 2014

Number of branches	N. gluteus cranialis								N. gluteus caudalis	
	TFL		AG		DG		MG		SG	
	RA	LA	RA	LA	RA	LA	RA	LA	RA	LA
0	-	-	-	-	-	-	90	86.6	-	-
1	-	3.3	6.6	6.6	3.3	-	-	3.3	-	-
2	90	66.6	13.3	16.6	3.3	-	-	6.6	-	-
3	10	26.6	33.3	53.3	23.3	20	6.6	-	-	3.3
4	-	3.3	30	20	33.3	36.6	3.3	-	13.3	16.6
5	-	-	13.3	3.3	23.3	23.3	-	3.3	26.6	23.3
6	-	-	3.3	-	10	3.3	-	-	26.6	26.6
7	-	-	-	-	-	13.3	-	-	20	10
8	-	-	-	-	-	3.3	-	-	6.6	13.3
9	-	-	-	-	-	-	-	-	3.3	-
10	-	-	-	-	3.3	-	-	-	3.3	6.6
<b>P-value</b>	<b>0.85</b>		<b>0.89</b>		<b>0.71</b>		<b>1</b>		<b>0.93</b>	

Table 2 – Representative table of relative frequencies (%) of the distribution in mixed-breed sheep, on the right (RA) and left (LA) antimer, of the branches of the ischiatic nerve (N. ischiadicus) to the middle gluteal (MG), deep gluteal (DG), gemelli (GE), quadratus femoris (QF), biceps femoris (BF), semitendinosus (ST), semimembranosus (SM), adductor (AD), superficial gluteal (SG) and accessory gluteal (AG) muscles; P-value, for each muscle, by Wilcoxon's test (0.05) – Uberlândia, MG, Brazil – 2014

Number of branches	N. ischiadicus																				
	MG		DG		GE		QF		BF		ST		SM		AD		SG		AG		
	RA	LA	RA	LA	RA	LA	RA	LA	RA	LA	RA	LA	RA	LA	RA	LA	RA	LA	RA	LA	
0	-	-	-	-	-	-	-	-	-	-	-	-	-	-	-	6.6	13.3	23.3	40	56.6	36.6
1	-	-	-	-	70	60	100	100	-	-	-	-	-	-	-	43.3	53.3	13.3	23.3	10	20
2	-	3.3	3.3	-	20	36.6	-	-	-	-	-	-	-	-	-	40	33.3	40	16.6	23.3	36.6
3	-	-	26.6	23.3	10	3.3	-	-	-	-	-	-	-	-	-	10	-	16.6	16.6	10	6.6
4	3.3	-	33.3	36.6	-	-	-	-	-	-	3.3	3.3	-	-	-	-	-	6.6	3.3	-	-
5	6.6	3.3	16.6	33.3	-	-	-	-	-	-	13.3	6.6	-	-	-	-	-	-	-	-	-
6	13.3	-	20	3.3	-	-	-	-	-	3.3	10	16.6	-	6.6	-	-	-	-	-	-	-
7	6.6	26.6	-	3.3	-	-	-	-	3.3	3.3	10	6.6	10	10	-	-	-	-	-	-	-
8	16.6	23.3	-	-	-	-	-	-	6.6	-	16.6	16.6	6.6	3.3	-	-	-	-	-	-	-
9	26.6	16.6	-	-	-	-	-	-	6.6	10	20	40	23.3	13.3	-	-	-	-	-	-	-
10	13.3	16.6	-	-	-	-	-	-	6.6	13.3	13.3	3.3	20	23.3	-	-	-	-	-	-	-
11	6.6	6.6	-	-	-	-	-	-	26.6	16.6	6.6	3.3	20	20	-	-	-	-	-	-	-
12	6.6	-	-	-	-	-	-	-	26.6	13.3	3.3	-	13.3	3.3	-	-	-	-	-	-	-
13	-	3.3	-	-	-	-	-	-	10	13.3	-	-	3.3	6.6	-	-	-	-	-	-	-
14	-	-	-	-	-	-	-	-	10	13.3	3.3	-	3.3	3.3	-	-	-	-	-	-	-
15	-	-	-	-	-	-	-	-	-	10	-	-	-	6.6	-	-	-	-	-	-	-
16	-	-	-	-	-	-	-	-	3.3	-	-	3.3	-	3.3	-	-	-	-	-	-	-
17	-	-	-	-	-	-	-	-	-	3.3	-	-	-	-	-	-	-	-	-	-	-
<b>P-value</b>	<b>0.87</b>		<b>1</b>		<b>1</b>		<b>1</b>		<b>0.92</b>		<b>0.67</b>		<b>1</b>		<b>1</b>		<b>1</b>		<b>1</b>		

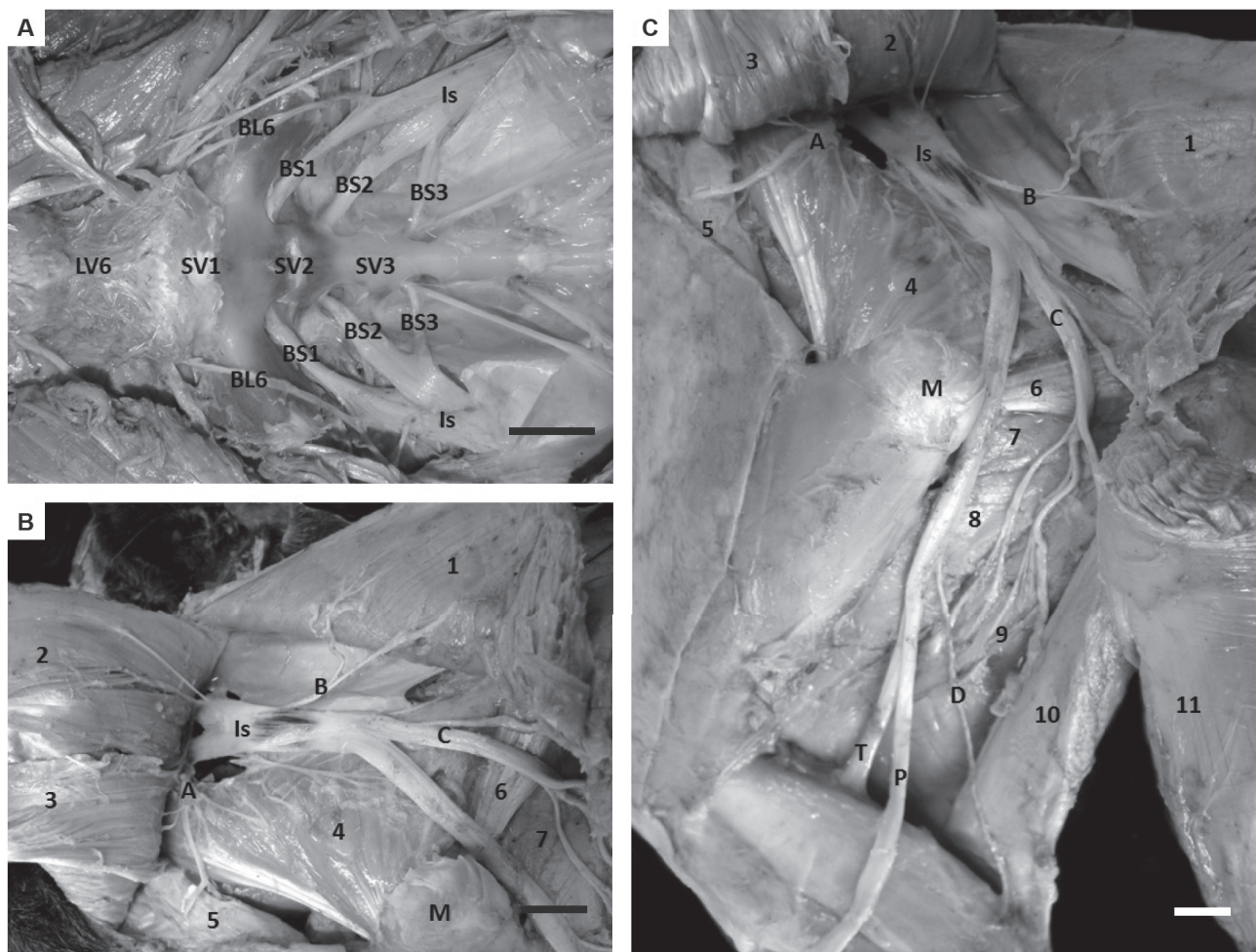


Figure 1 – (A) Photograph of the pelvic cavity of mixed-breed sheep, visualizing the sixth lumbar vertebra (LV6), the first, second and third sacral vertebrae (SV1, SV2 and SV3, respectively) and the intervertebral foramen from which are derived the ventral branch of the sixth lumbar spinal nerve (BL6) and the ventral branches of the first, second and third sacral spinal nerves (BS1, BS2 and BS3, respectively), giving origin to the ischiatic nerve (Is). (B and C) Photograph of the gluteal region (B) and of the gluteal, thigh and leg regions (C), of the left pelvic member, showing the greater trochanter of the femur bone (M) and the ischiatic nerve (Is) forwarding the cranial gluteal nerve (A), the caudal gluteal nerve (B), the muscular branches (C) to the biceps femoris, semitendinosus and semimembranosus muscles, and the lateral cutaneous sural nerve (D), and finally, launching the tibial (T) and common peroneal (P) nerves. Further, the superficial gluteal (1), middle gluteal (2), accessory gluteal (3), deep gluteal (4), tensor fasciae latae (5), gemelli (6), quadratus femoris (7), adductor (8), semimembranosus (9), semitendinosus (10) and biceps femoris (11) muscles can be also identified; Scale bar: 2cm

Source: (VASCONCELOS et al., 2014)

S1 and S2. Whereas reports on ruminants by Ghoshal (1986d) underscore that the ischiatic nerve derived mainly from the ventral branches of the last lumbar spinal nerve and from the first and second sacral spinal nerves, the number of lumbar spinal nerve may vary and depends on the number of the lumbar vertebrae present. Linzell (1959) supplemented the above information and remarked that when the ventral branch of the L7 is present in sheep, it also

forms the ischiatic nerve, replacing L6. These reports corroborated results in 73.3% of mixed-breed sheep specimens. In fact, there was a similarity in the origin and general arrangement between the ischiatic nerves, with symmetry between the antimeres, sometimes originating from the ventral branches of L6, S1 and S2, as described in domestic ruminants (GODINHO; CARDOSO; NASCIMENTO, 1987), mainly crossbred zebu cattle (CAMPOS et al., 2003) and

in Saanen goats (LIMA et al., 2008), and sometimes from the ventral branches of the last lumbar spinal nerve and from first and second sacral spinal nerves, or rather, a characteristic of all domestic ruminants (GHOSHAL, 1986d) including sheep. Instability between the contributions of the ventral branches of L6 or L7, verified in the formation of sheep's ischiatic nerve, is due to the variation, between 6 (86.6%) and 7 (13.3%), in the number of lumbar vertebrae. The above information differed from that in other ruminants, especially in cattle and goats.

In specific reports on crossbreed zebu cattle, Ferraz et al. (2006) informed the origin of the ischiatic nerve from the ventral branches of L6, S1 and S2, in all cases. The nerve received the contribution of L5 in 39.4% of animals and the contribution of S3 in 12.1%. Similar data were also registered by Campos et al. (2003) for crossbreed zebu cattle. These authors also reported the origin of the ischiatic nerve from the ventral branches of L6, S1 and S2 (63.3% of specimens), but also underscored the contributions of the ventral branches of L5 (16.6%) and S3 (20%). In the case of Saanen goats, Lima et al. (2008) described the formation of the ischiatic nerve from contributions of the ventral branches of L6, S1 and S2, with the further sporadic contributions of the ventral branch of S3 in 6.7% of dissections. Data from this study do not match reports by Campos et al. (2003) and Ferraz et al. (2006) on the contribution of the ventral branch of L5 in the formation of ischiatic nerve in crossbreed zebu cattle. Although there was a high contribution of L5 in 39.4% of crossbreed zebu cattle studied by Ferraz et al. (2006) and in 16.6% by Campos et al. (2003), the information was not corroborated by Lima et al. (2008) in Saanen goats. According to Campos et al. (2003) and Ferraz et al. (2006), the collaboration of the ventral branch of L5 in the formation of the ischiatic nerve is due to a specific variation of cattle breeds, especially their European origin in this case. On the other hand, reports on the contribution of the ventral branch of S3 proposed by Campos et al.

(2003) and by Ferraz et al. (2006) for crossbreed zebu cattle, and by Lima et al. (2008) for Saanen goats matched findings on mixed-breed sheep in 16.6% of cases. Current authors would like to emphasize the importance of using the generic information on the contribution of the ventral branch of the last lumbar spinal nerve to describe the formation of the ischiatic nerve in sheep and in other ruminants owing to the variation of the number of lumbar vertebrae.

With regard to the distribution of the ischiatic nerve's muscular branches, Campos et al. (2003) on crossbred zebu cattle, and Lima et al. (2008) on Saanen goats, mentioned generically the supply of muscular branches to the gluteal and thigh regions. This report also matched data on mixed-breed sheep.

Corroborating reports by Ghoshal (1986d) and Godinho, Cardoso and Nascimento (1987), the formation of two nerves, namely the cranial gluteal nerve and the caudal gluteal nerve, were identified close to the origin of ruminant's ischiatic nerve. When dealing with the cranial gluteal nerve, Godinho, Cardoso and Nascimento (1987) reported generically the innervation of the gluteal muscles, whereas Ghoshal (1986d) described branches towards the middle gluteal, deep gluteal and tensor fasciae latae muscles. Results in mixed-breed sheep confirmed reports by Ghoshal (1986d). Nerve branches to accessory gluteal muscle in all sheep were also verified. The above data may be due to the close relationship of the accessory gluteal muscle with the deep section of the middle gluteal muscle.

Ghoshal (1986d) and Godinho, Cardoso and Nascimento (1987) registered the innervations of the middle gluteal and gluteobiceps muscles. Contrastingly, current analysis failed to detect these branches, but rather the specific innervation towards the superficial gluteal muscle. The need for the specific verification of the superficial gluteal and biceps femoris muscles should be highlighted but not as a muscular group as the International Committee on Veterinary Gross Anatomical Nomenclature (2012) warrants.

Corroborating information by Ghoshal and Getty (1970, 1971) for goats and sheep, respectively; by Campos et al. (2003) on crossbred zebu cattle; and by Lima et al. (2008) on Saanen goats, current analysis also identified the supply of ischiatic nerve's muscle branches to the middle gluteal and deep gluteal muscles. The supply of ischiatic nerve branches to the accessory gluteal muscle in approximately half the specimens was also identified. The above reveals the intense participation of the ischiatic nerve to the gluteal nerves for the innervation of the gluteal region's muscles.

Further, in its transition from the gluteal to the thigh region, the ischiatic nerve sent branches to the gemelli (GHOSHAL; GETTY, 1970, 1971; GODINHO; CARDOSO; NASCIMENTO, 1987; CAMPOS et al., 2003; LIMA et al., 2008), quadratus femoris (GHOSHAL; GETTY, 1970, 1971; GODINHO; CARDOSO; NASCIMENTO, 1987), and adductor muscles (GHOSHAL; GETTY, 1970, 1971; GODINHO; CARDOSO; NASCIMENTO, 1987; CAMPOS et al., 2003). The above data agreed with findings on mixed-breed sheep on the ischiatic nerve branches towards the above muscles. Moreover, variations registered by Campos et al. (2003) on the frequency of the innervation of adductor muscle, with regard to 80% in LA to 86.6% in RA, also corroborated current results, with innervation between 86.6% in LA and 93.3% in RA. Ghoshal and Getty (1970, 1971) and Godinho, Cardoso and Nascimento (1987) reported branches to the internal and external obturators and the tensor fasciae latae muscles in this area. Current study failed to identify specific branches of the ischiatic nerve for these muscles in the animals under analysis. However, branches to the tensor fasciae latae muscle were reported exclusively from of the cranial gluteal nerve, as previously discussed. The variation may have been due to the proximity of the cranial gluteal nerve with the muscular branches of ischiatic nerve, with special difficulty in being distinguished.

According to Ghoshal and Getty (1970, 1971) for goats and sheep, respectively; Ghoshal (1986d)

and Godinho, Cardoso and Nascimento (1987) for ruminants; Campos et al. (2003) for crossbred zebu cattle; Lima et al. (2008) for Saanen goats, the ischiatic nerve supplied branches to the gluteobiceps, semimembranosus and semitendinosus muscles, corroborating results in current study. The authors would like to underscore that despite the different fusion degrees of the superficial gluteal and biceps femoris muscles observed in domestic animals, particularly in ruminants, sometimes completely fused in cattle and sometimes partially fused in sheep and goats, the muscles may be called gluteobiceps muscles, as the International Committee on Veterinary Gross Anatomical Nomenclature (2012) suggested. However, current authors would prefer specific nomenclature (superficial gluteal and biceps femoris muscles) for these muscles in current paper to highlight the great amount of information supplied. The abrupt prevalence of innervation of the biceps femoris in all animals, ranging between 6 and 17 branches is also registered. Further, the innervation of superficial gluteal muscle in most sheep studied, 76.6% in RA and 60% in LA, ranging between 1 and 4 branches, should also be underscored. When specific results on sheep are compared with generic results in other studies, there were discrepant rates to data on Saanen goats (LIMA et al., 2008) and crossbred zebu cattle (CAMPOS et al., 2003). Reports in the literature ran counter to those expected, since current authors believed that variation on the supply of muscular branches between the superficial gluteal and biceps femoris muscles in ruminants, particularly between large and small ruminants, should be extant. In fact, the innervations level of the ischiatic nerve should necessarily comply with the degree of muscle fusion in ruminants. Therefore, supply of the ischiatic nerve would probably be higher in cattle than in goats and sheep, which failed to occur. The authors believe that evaluations by the muscle group may have masked this hypothesis. Further investigations on ruminants,

especially in goats and cattle and in the Hindu and European origins of cattle, are required for a better anatomical understanding of these data.

With respect to the tibial and common peroneal nerves in mixed-breed sheep, Ghoshal (1986d), Godinho, Cardoso and Nascimento (1987), Campos et al. (2003) and Lima et al. (2008) reported that they are the terminal branches of the ischiatic nerve, originating distally from the greater trochanter of the femur bone.

According to the statistical analysis, results of current investigation revealed that there was no significant difference between the frequency of the muscular branches and the antimeres, regardless of the number of muscular branches, with P-value between 0.67 and 1. Taking into account the data on the distribution of the ischiatic nerve in mixed-breed sheep, it may be remarked that its distribution is done similarly on the right and left antimeres. Further, frequency of muscular branches may undergo some interference, probably caused by the absence of a specific racial factor. Detailed investigations on the ischiatic nerve and on all nerves that comprise the lumbosacral plexus in sheep with specific racial patterns, are required.

## Conclusions

Results show that the ischiatic nerve in mixed-breed sheep originates from the ventral branch of last lumbar spinal nerve, either of the sixth lumbar spinal nerve or of the seventh, when extant, and from the ventral branches of first and second sacral spinal nerves, with possible contributions from the ventral branch of third sacral spinal nerve. The ischiatic nerve branched towards the superficial gluteal, middle gluteal, accessory gluteal, deep gluteal, gemelli, quadratus femoris, adductor, biceps femoris, semitendinosus and semimembranosus muscles. Tibial and common peroneal nerves, originating distally from the greater trochanter of femur bone, are the terminal branches of the ischiatic nerve. There are no statistically significant differences between the frequencies of the muscular branches of the ischiatic nerve and the antimeres, regardless of the number of muscular branches, with P-value between 0.67 and 1.

## Acknowledgements

The authors would like to thank Prof. Dr. Ednaldo Carvalho Guimarães for the statistics provided in current research.



## References

- AVERSI-FERREIRA, R. A. G. M. F.; MARIN, K. A.; SILVA, F. O. C. e; AVERSI-FERREIRA, T. A. Comparative anatomy of the thigh nerves of *Cebus libidinosus*. **Pesquisa Veterinária Brasileira**, v. 31, n. 3, 2011. Available from: <[http://www.scielo.br/scielo.php?script=sci\\_arttext&pid=S0100-736X2011000300013&lng=en&nrm=iso&tlng=en](http://www.scielo.br/scielo.php?script=sci_arttext&pid=S0100-736X2011000300013&lng=en&nrm=iso&tlng=en)>. Viewed: 24 Jan. 2014. doi: <http://dx.doi.org/10.1590/S0100-736X2011000300013>.
- BARROS, R. A. C.; PRADA, I. L. S.; SILVA, Z.; RIBEIRO, A. R.; SILVA, D. C. O. Constituição do plexo lombar do macaco *Cebus apella*. **Brazilian Journal of Veterinary Research and Animal Science**, v. 40, n. 5, p. 373-381, 2003.
- BRUNI, A. C.; ZIMMERL, V. **Anatomia degli animali domestici**. 2. ed. Milano: Casa Editrice Dr Francesco Vallardi, 1977. 736 p.
- BUDRAS, K. D.; SACK, W. O.; RÖCK, S. **Anatomy of horse**. 5th ed. Hannover: Schlütersche Verlagsgesellschaft GmbH & Co. KG, 2009. p. 23.
- CAMPOS, D. B.; SILVA, F. O. C.; SEVERINO, R. S.; DRUMMOND, S. S.; LIMA, E. M. M.; BOMBONATO, P. P.; SANTANA, M. I. S. Origem e distribuição dos nervos isquiáticos em fetos de bovinos azebuados. **Ars Veterinaria**, v. 19, n. 3, p. 219-223, 2003.
- CHAMPNEYS, F. On the muscles and nerves of a Chimpanzee (*Troglodytes niger*) and a *Cynocephalus anubis*. **Journal of Anatomy and Physiology**, v. 6, n. 1, p. 176-211, 1975.
- DYCE, K. M.; SACK, W. O.; WENSING, C. J. G. **Tratado de anatomia veterinária**. 4. ed. Rio de Janeiro: Elsevier, 2010. p. 323-325.
- ELLENBERGER, W.; BAUM, H. **Handbuch der vergleichenden anatomie der haustiere**. Berlin: Springer Verlag, 1987. p. 12.
- EVANS, H. E. **Miller's anatomy of the dog**. 3rd ed. Philadelphia: W.B. Saunders Company, 1993. p. 865-892.
- EVANS, H. E.; DELAHUNTA, A. **Guia para a dissecação do cão**. 5. ed. Rio de Janeiro: Guanabara Koogan, 2001. p. 154-174.
- FERRAZ, R. H. S.; LOPES, G. R.; MELO, A. P. F.; PRADA, I. L. S. Estudo anatômico da porção intrapélvica do nervo isquiático em fetos de bovinos azebuados. **Brazilian Journal of Veterinary Research and Animal Science**, v. 43, n. 3, p. 302-308, 2006.
- FRANDSON, R. D.; WILKE, W. L.; FAILS, A. D. **Anatomia e fisiologia dos animais da fazenda**. 6th ed. Rio de Janeiro: Guanabara Koogan, 2005. p. 135-145.
- GHOSHAL, N. G. Nervos espinhais. In: GETTY, R. **Sisson/Grossman anatomia dos animais domésticos**. 5. ed. Rio de Janeiro: Guanabara Koogan, 1986a. v. 2, cap. 57, p. 1595-1617. pt. 1-2.
- GHOSHAL, N. G. Nervos espinhais. In: GETTY, R. **Sisson/Grossman anatomia dos animais domésticos**. 5th ed. Rio de Janeiro: Guanabara Koogan, 1986b. v. 1, cap. 24, p. 620-641.
- GHOSHAL, N. G. Nervos espinhais. In: GETTY, R. **Sisson/Grossman anatomia dos animais domésticos**. 5th ed. Rio de Janeiro: Guanabara Koogan, 1986c. v. 2, cap. 46, p. 1294-1307.
- GHOSHAL, N. G. Sistema espinhais. In: GETTY, R. **Sisson/Grossman anatomia dos animais domésticos**. 5th ed. Rio de Janeiro: Guanabara Koogan, 1986d. v. 1, cap. 35, p. 1052-1077.
- GHOSHAL, N. G.; GETTY, R. The lumbosacral plexus (*plexus lumbosacralis*) of the goat (*Capra hircus*). **Iowa State Journal of Science**, v. 45, n. 2, p. 283-296, 1970.
- GHOSHAL, N. G.; GETTY, R. The lumbosacral plexus (*plexus lumbosacralis*) of the sheep (*Ovis aries*). **New Zealand Veterinary Journal**, v. 19, n. 5, p. 85-90, 1971. Available from: <<http://www.tandfonline.com/doi/abs/10.1080/00480169.1971.33939#U-UCH-NdXMA>>. Viewed: 13 Dec. 2013. doi: <http://www.tandfonline.com/doi/abs/10.1080/00480169.1971.33939#U-UCH-NdXMA>.
- GODINHO, H. P.; CARDOSO, F. M.; NASCIMENTO, J. F. **Anatomia dos ruminantes domésticos**. Belo Horizonte: Universidade Federal de Minas Gerais, 1987. 438 p.
- GUIMARÃES, G. C.; MACHADO, M. R. F.; SANTOS, A. L. Q.; VIEIRA, L. G.; SOUZA, A. G. de; SILVA, J. M. M.; KAMINISHI, A. P. S. Origem e distribuição do nervo isquiático no gato doméstico (*Felis catus domesticus*, Linnaeus, 1758). **Bioscience Journal**, v. 21, p. 189-195, 2005.
- IGLESIAS, L. P.; SILVA, F. O. C.; BRITO, T. R. Origem e distribuição do nervo isquiático em fetos de javalis (*Sus sus scrofa*). **Biotemas**, v. 24, n. 4, p. 139-143, 2011. Available from: <<https://periodicos.ufsc.br/index.php/biotemas/article/view/2175-7925.2011v24n4p141>>. Viewed: 5 Jan. 2014. doi: <http://www.tandfonline.com/doi/abs/10.5007/2175-7925.2011v24n4p141>.
- INTERNATIONAL COMMITTEE ON VETERINARY GROSS ANATOMICAL NOMENCLATURE. **Nomina anatomica veterinaria**. 5th ed. Hannover, Columbia, Gent, Sapporo: Editorial Committee, 2012. 139 p.
- KÖNING, H. E.; LIEBICH, H. G. **Anatomia dos animais domésticos: texto e atlas colorido**. 4th ed. Porto Alegre: Artmed, 2011. p. 572-576.
- KRECHOWIECKI, A.; GOSCICKA, D. The lumbosacral plexus and lumbar enlargement in *Macaca mulatta*. **Folia Morphologica**, v. 31, p. 11-19, 1972.
- LACERDA, P. M. O.; MOURA, C. E. B.; MIGLINO, M. A.; OLIVEIRA, M. F.; ALBUQUERQUE, J. F. G. Origem do plexo lombosacral de mocó (*Kerodon rupestris*). **Brazilian Journal of Veterinary Research and Animal Science**, v. 43, n. 5, p. 620-628, 2006.
- LIMA, E. M. M.; SILVA, F. O. C.; SEVERINO, R. S.; DRUMMOND, S. S.; CAMPOS, D. B.; SANTANA, M. I. S.; MORAES, D. D. A. Origem e distribuição dos nervos isquiáticos em caprinos da raça Saanen. **Ciência Rural**, v. 38, n. 2, p. 372-377, 2008. Available from: <[http://www.scielo.br/scielo.php?script=sci\\_arttext&pid=S0103-84782008000200012](http://www.scielo.br/scielo.php?script=sci_arttext&pid=S0103-84782008000200012)>. Viewed: 24 Jan. 2014. doi: <http://dx.doi.org/10.1590/S0103-84782008000200012>.
- LINZELL, J. L. The innervation of the mammary glands in the sheep and goat with observations on the lumbosacral autonomic nerves. **Quarterly Journal of Experimental Physiology and Cognate Medical Sciences**, v. 44, n. 2, p. 160-176, 1959.
- NICKEL, R.; SCHUMMER, A.; SEIFERLE, E. **Lehrbuch der anatomie der haustiere**. Berlin: Paul Parey, 1984. Band IV, p. 235-249.
- OLIVEIRA, G. B.; RODRIGUES, M. N.; SOUSA, E. S.; ALBUQUERQUE, J. F. G. de; MOURA, C. E. B. de; AMBRÓSIO, C. E.; MIGLINO, M. A.; OLIVEIRA, M. F. de. Origem e distribuição dos nervos isquiático do preá. **Ciência Rural**, v. 40, p. 1741-1745, 2010.
- PEREIRA, K. F.; PARANAIBA, J. F. F. S.; HELRIGLE, C.; ARAÚJO, E. G. Origem e distribuição anatômica do nervo isquiático de mão-pelada (*Procyon cancrivorus*). **Pesquisa Veterinária Brasileira**, v. 31, p. 74-78, 2011. Supplement 1.
- SANTOS, L. A.; SILVA, F. O. C.; ROSA, L. A.; MENEZES, L. T.; CANABRAVA, A. C. M. N.; LIZARDO, F. B.; SILVA, D. C. O.; SOUSA, G. C. Origem e distribuição do nervo isquiático em fetos de suínos (*Sus scrofa domesticus*, Linnaeus, 1758) da linhagem Pen Ar Lan. **Biotemas**, v. 26, n. 1, p. 147-157, 2013. Available from: <<https://periodicos.ufsc.br/index.php/biotemas/article/view/2175-7925.2013v26n1p147>>. Viewed: 16 Jan. 2014. doi: <http://dx.doi.org/10.5007/2175-7925.2013v26n1p147>.
- SCHWARZE, E.; SCHRÖDER, L. Sistema nervoso cerebrospinal. In: SCHWARZE, E.; SCHRÖDER, L. **Compendio de anatomia veterinaria: sistema nervoso y organos de los sentidos**. Zaragoza: Acribia, 1970. v. 4. p. 61-90.
- SEIFERLE, E. **Nervensystem sinnesorgane endocrine drüsen**. Berlin: Paul Parey, 1975. p. 240.