

## BASIC RESEARCH

# The impact of previous para-areolar incision in the upper outer quadrant of the breast on the localization of the sentinel lymph node in a canine model

Paulo Henrique Diógenes Vasques,<sup>I</sup> Luiz Gonzaga Porto Pinheiro,<sup>I,II,III</sup> João Marcos de Meneses e Silva,<sup>II</sup> José Ricardo de Moura Torres-de-Melo,<sup>II</sup> Karine Bessa Porto Pinheiro,<sup>III</sup> João Ivo Xavier Rocha<sup>II,III</sup>

<sup>I</sup> Department of Surgery, Federal University of Ceará, Fortaleza, Ceará, Brazil. <sup>II</sup> Saul Goldenberg Experimental Surgery Laboratory, Fortaleza, Ceará, Brazil.

<sup>III</sup> Group Study and Education in Oncology, Department of Surgery, Federal University of Ceará, Fortaleza, Ceará, Brazil.

**OBJECTIVES:** This paper discusses the influence of a para-areolar incision in the upper outer quadrant of the breast on the location of the sentinel lymph node in a canine model.

**METHODS:** The sentinel lymph node was marked with technetium-99, which was injected into the subareolar skin of the cranial breast. After the marker had migrated to the axilla, an arcuate para-areolar incision was performed 2 cm from the nipple in the upper outer quadrant. Patent blue dye was then injected above the upper border of the incision. At the marked site, an axillary incision was made, and the sentinel lymph node was identified by gamma probe and/or by direct visualization of the dye. The agreement between the two injection sites and the two sentinel lymph node identification methods was determined. Our sample group consisted of 40 cranial breasts of 23 adult females of the species *Canis familiaris*. The data were analyzed by using the McNemar test and by determining the kappa agreement coefficient.

**RESULT:** Our findings showed that in 95% of the breasts, the sentinel lymph node was identified by the injection of technetium-99 m into the subareolar region, and in 82% of the cases, the sentinel lymph node was identified by the injection of patent blue dye above the upper border of the incision. The methods agreed 82% of the time.

**CONCLUSIONS:** Previous para-areolar incisions in the upper outer quadrant did not interfere significantly with the biopsy when the dye was injected above the upper border of the incision.

**KEYWORDS:** Breast cancer; Gamma probe; Sentinel node; Animal model; Oncologic surgery.

Vasques PHD, Pinheiro LGP, Silva JMM, Torres-de-Melo JRM, Pinheiro KBP, Rocha JIX. The impact of previous para-areolar incision in the upper outer quadrant of the breast on the localization of the sentinel lymph node in a canine model. Clinics. 2011;66(8):1413-1418.

Received for publication on February 11, 2011; First review completed on March 25, 2011; Accepted for publication on April 24, 2011

E-mail: luizgporto@uol.com.br

Tel.: 55 85 3283-5700

## INTRODUCTION

In 1977, Cabanas<sup>1</sup> reported the identification of nodal drainage pathways and a sentinel node from penile cancer. Sentinel lymph node (SLN) biopsy, introduced in the mid-1990s, has revolutionized the management of breast cancer patients.<sup>2,3</sup> The use of this method has significantly reduced the need for extensive axillary dissection to establish a reliable prognosis in breast cancer treatment.

Using isosulfan blue dye, Morton et al.<sup>4</sup> demonstrated the accuracy of sentinel node biopsy for nodal staging and the management of patients with primary cutaneous melanoma. The authors determined that if the sentinel node tumor was

not yet committed to the tumor state, then the other nodes in the lymphatic network would also be healthy. They reported a 1% rate of false negatives, opening prospects for research throughout the world.<sup>5-7</sup>

In 1993, Alex et al.<sup>8</sup> injected technetium and introduced the technique of gamma probe-guided surgery to identify the sentinel node. In the same year, Krag et al.<sup>9</sup> published a study on the sentinel node using technetium-99 (Tc99) with probes used for the detection of gamma rays in breast cancer. They concluded that the radiolocation and selective resection of the sentinel lymph node was feasible and could be used to determine the status of the axillary lymph node.

The initial techniques of SLN injection in breast cancer were intended to aid in the location of the drainage route of tumor metastasis; the dye or radiopharmaceuticals were injected into the peritumoral region. Following the increased understanding of the lymphatic drainage of the breast, superficial injection techniques have been implemented.<sup>10,11</sup>

**Copyright** © 2011 CLINICS – This is an Open Access article distributed under the terms of the Creative Commons Attribution Non-Commercial License (<http://creativecommons.org/licenses/by-nc/3.0/>) which permits unrestricted non-commercial use, distribution, and reproduction in any medium, provided the original work is properly cited.

Based on this knowledge, most centers have adopted the following superficial injection techniques: subdermal, intradermal, subareolar, or periareolar. These techniques have been chosen because they are technically easy, highly reproducible and provide a higher rate of identification and lower false-negative rates than does peritumoral injection.<sup>12</sup>

In daily practice, the surgeon often uses the arcuate-areolar incision for access to nodes or foci of microcalcifications in the upper breast quadrant. In cases of previously diagnosed, biopsied cancer patients where the histopathological diagnosis pointed to additional surgical procedures, some authors claim that the SLN identification should be performed by injecting markers immediately above the incision.<sup>13</sup> In this case, it is questionable if the node identified by this technique is the same as the one identified with the marker injected into the subpapular space following a skin incision. Therefore, this study aimed to evaluate, in an experimental model, whether para-areolar incisions in the upper outer quadrant of the paired cranial thoracic breasts of bitches interfere with the identification of the SLN.

## MATERIALS AND METHODS

All studies were conducted according to the rules of the Brazilian College of Animal Experimentation (COBEA). The use of the radioactive tracer Tc99 was approved by the National Nuclear Energy Commission (CNEN) and the Institute for Energy and Nuclear Research (IPEN). Approval for the experimental use of laboratory animals was obtained from the Committee of Ethics in Animal Research of the Federal University of Ceará.

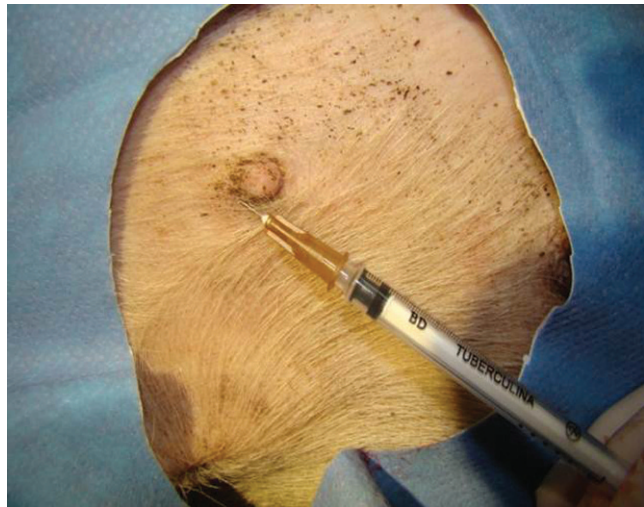*Sample group* - The sample group consisted of 40 breasts obtained from 23 healthy bitches of undefined breeds of the species *Canis familiaris*, housed in the Zoonosis Control Center Kennel of the City of Fortaleza.

*Inclusion criteria* - Inclusion in the study required clinically healthy bitches, who showed well-defined cranial thoracic breasts and nipples.

*Exclusion criteria* - The animals weren't included if they were under six months old, weighed either less than 5 kg or more than 15 kg and presented with cranial thoracic breast atrophy, previous surgery and/or scars. As a radiotracer, we used 0.2 mL Tc99 phytate (Conselho Nacional de Energia Nuclear - CNEN, Brazil).

## Surgical procedure

After immobilization on the operating table with the legs abducted, the animals were anesthetized subcutaneously with 0.05 mg/kg atropine (Centralvet®, Brazil) followed by 15 mg/kg ketamine hydrochloride (Syntec®, Brazil) and 1.5 mg/kg xylazine hydrochloride (Syntec®, Brazil) intramuscularly. The level of anesthesia was monitored continuously by clinical parameters, such as movements of the nostrils and other muscle groups and respiratory and cardiac rates. Additional anesthesia was provided as required. Venipuncture in an upper paw with a 9- or 21-gauge "scalp" needle was performed for the administration of 0.9% saline to secure adequate venous access. The surgical areas of the breast and axilla were shaved to remove excess hair. Subsequently, 0.2 ml Tc99 phytate was injected intradermally using a fine-gauge insulin needle in the subareolar region of both cranial thoracic breasts (Figure 1). Two-minute bidigital massage was provided to



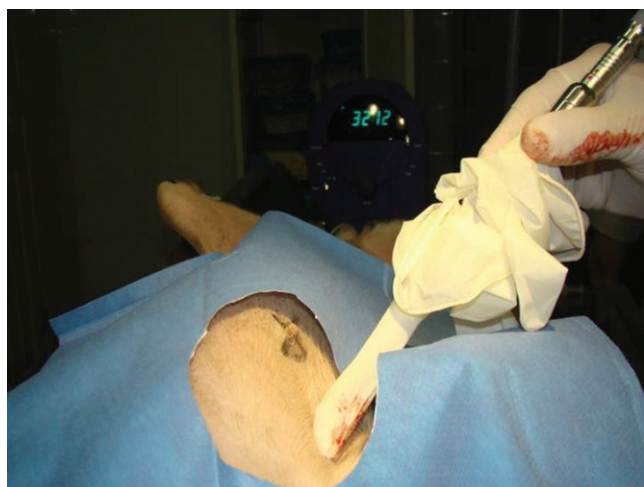**Figure 1** - Intradermal injection of 99mTc into the subareolar region of cranial thoracic breasts using a fine-gauge insulin needle.

promote the migration and transport of the radiocolloid particles to the lymphatic system.

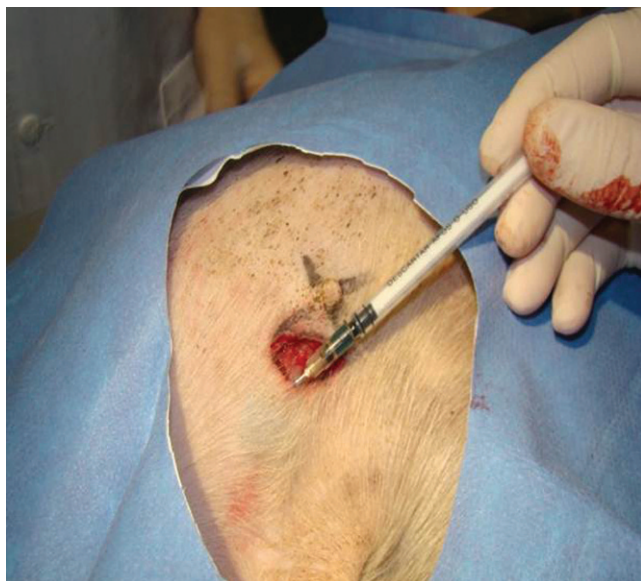Five minutes after the Tc-99 subareolar injection, axillary mapping was performed using a gamma probe that was covered with a surgical glove (Figure 2) to identify the location of the point of maximum uptake of the gamma radiation in the axilla, which represents the projection of the sentinel node.

The upper breast quadrants were outlined with a dermatographic pen, using the nipple as the center point. The quadrants delineated segments with axes that were 2 cm distant from the center of the nipple and formed a 90-degree angle at the junction point. The arcuate incision position and extent were determined by linking the two distal ends of the axes. Therefore, the incisions were placed between 12 – 15 h (left breast) and 9 – 12 h (right breast), 2 cm from the nipple.

After incision and hemostasis by compression of the wound, 0.5 ml blue dye (bleu patenté V Guerbet 2.5%) was injected just above the midpoint of the arcuate top edge of



**Figure 2** - Performing axillary mapping using a gamma probe to identify the location of the projection of the sentinel node in the axilla.



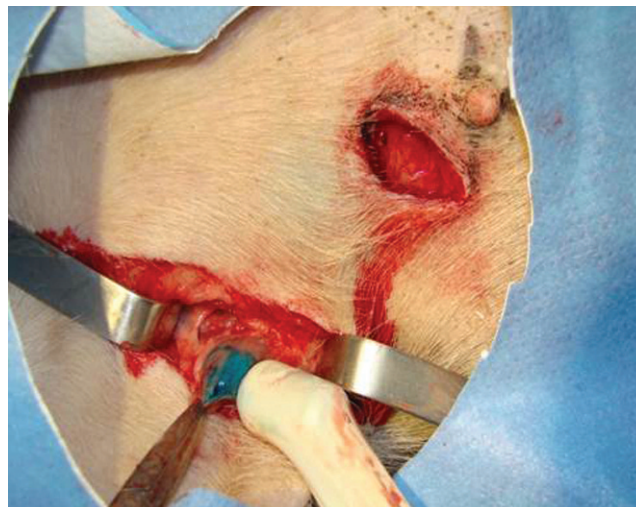
**Figure 3** - Injection of blue dye (bleu patenté V Guerbet 2.5%) just above the midpoint of the arcuate top edge of the incision in the subdermal region.

the incision in the subdermal region (Figure 3). Local compression and gentle massage at the site of injection were applied to prevent the contrast from spreading farther and to allow it to be transported by the lymphatic network of the area to the sentinel node.

After five minutes, the axillary point of the highest radiation uptake was identified with the gamma probe NuclearLab-DGC-8. A 3-cm-long axillary incision was made at this point, followed by a careful dissection that was guided by the visualization of a bluish afferent lymphatic system that pointed to the SLN(s). When the afferent lymphatic vessels were difficult to identify, the location of the SLN with the gamma probe was necessary to guide the incision site.

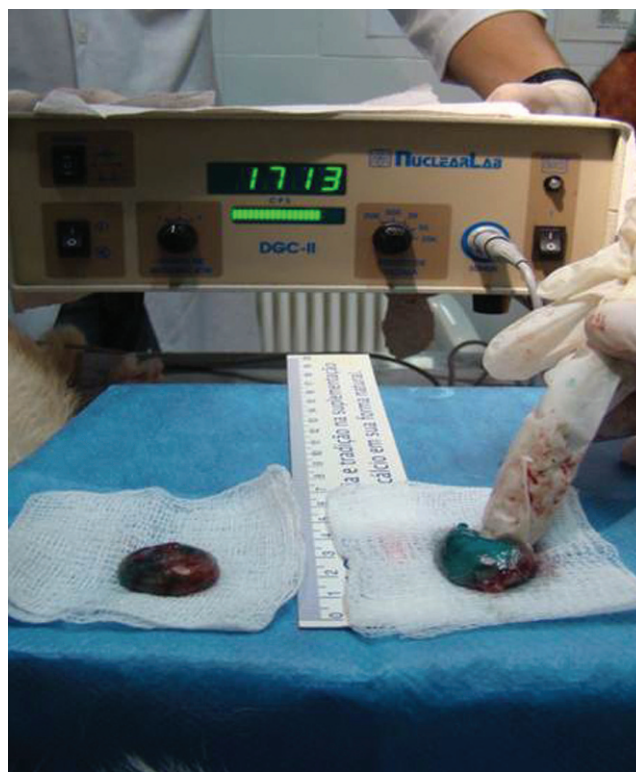A significant radioisotope uptake should be at least five-fold higher than the background radioactivity in the armpit. The background radioactivity represents the count that was obtained in four axillary equidistant points from the point of injection or the location of the sentinel node.

Upon complete exposure of the identified SLN, the radiocolloid uptake was measured *in vivo* and *ex vivo* after the removal of the SLN (Figures 4-5). The values obtained were registered for subsequent analysis. The position of the sentinel lymph node, as identified by the blue dye, was compared with the location identified by the gamma probe to check whether there was agreement between the two methods. Radiation was also measured in the surgical bed to identify any remaining hot lymph nodes. If positive, the lymph node was removed, and its radiation and dye uptake characteristics were recorded. The area ratio of the greatest uptake/background radiation of the surgical bed should be greater than or equal to ten. Verification of the radioactivity of the SLN after removal from the surgical field (*ex-vivo* counting) and comparison with the radioactivity from the surgical bed confirmed that the SLN was actually removed and that there was no other source of radiation that could justify the continuation of a search for another node.



**Figure 4** - Complete exposure of the identified SLN and measurement of the radiocolloid uptake *in vivo* before the removal of the SLN.

We recorded all radiation rates at the injection site before the incision was made in the armpit, the sentinel lymph node radioactivity *in vivo* and *ex vivo* and the radioactivity from the central bed where the sentinel bed was located. The parameter used was the background radioactivity (radiation control). The tabulated data quantified the intersection between the two markings and the correlation between the methods.



**Figure 5** - Measurement the radiocolloid uptake *ex vivo* after the removal of the SLN.

**Table 1** - Kappa coefficient of concordance when comparing isolated patent blue dye with a combination of Tc99 and patent blue dye in SLN identification.

|                 |     | Tc99 + Patent Blue Dye |   |    |
|-----------------|-----|------------------------|---|----|
| Patent Blue Dye | Yes | 32                     | 1 | 33 |
|                 | No  | 1                      | 6 | 7  |
| Total           |     | 33                     | 7 | 40 |

Tc99: technetium99 SLN: Sentinel lymph node  
 Kappa = 0.827/Observed agreements: 95%

The animals were sacrificed after the experiment with the rapid intravenous injection of 10% potassium chloride, stored in a suitable plastic bag, placed in refrigeration for at least two hours, and subsequently sent to the Zoonosis Control Center Kennel.

**Statistical methods**

The Graphpad software (<http://www.graphpad.com/quickcalcs/index.cfm>) was used for computation and statistical analysis. The data were evaluated by a McNemar test and the kappa coefficient of concordance. P-values were determined using Fisher’s exact test. A p-value <0.05 was considered to be statistically significant.

**RESULTS**

From a sample group of 23 bitches (46 breasts), only 40 fulfilled the inclusion/exclusion criteria; 95% of the breasts studied had an SLN that was identified within the axillary site by using the gamma probe after an injection of Tc99 phytate into the subareolar region (Table 1). After the injection of patent blue into the dermis of the upper edge of the arcuate incision in the upper quadrant of the left breast, 82% (33/40) of the isolated lymph nodes were stained (Table 2). In the cases studied, there was agreement among the methods evaluated in 82% (28/43) of cases (Table 3).

Table 4 shows the results that were obtained using Tc99 and patent blue dye (sentinel nodes from the left and right cranial thoracic bitch breasts). The McNemar test resulted in p=0.1306 (IC: 95%). The kappa coefficient of concordance when comparing Tc99 isolated with a combination of Tc99 and patent blue in a sentinel node assay was 0.157 (82% observed agreements) (Table 5). The kappa coefficient of concordance when comparing the single use of patent blue dye with a combination of Tc99 and patent blue was 0.827 (95% observed agreements) (Table 6).

**DISCUSSION**

Sentinel node biopsy has evolved with the publication of the many studies since Cabanas’ original paper in 1977.<sup>1</sup> Morton et al.<sup>4</sup> identified the SLN in cases of melanoma using

**Table 2** - Identification of the SLN in the bitch axilla using the sub-areolar injection of Tc99 into that region of the right and left breasts.

|                    |          | N  | %   |
|--------------------|----------|----|-----|
| SLN identification | Positive | 38 | 95% |
|                    | Negative | 2  | 5%  |

Tc99: technetium99 SLN: Sentinel lymph node

**Table 3** - Identification of the SLN in the bitch axilla using blue dye injection into the dermal region of the upper edge of the arcuate incision in the left superior quadrant of the right and left breasts.

|                    |          | N  | %   |
|--------------------|----------|----|-----|
| SLN identification | Positive | 32 | 82% |
|                    | Negative | 7  | 18% |

SLN: Sentinel lymph node

dye, while Krag et al.<sup>9</sup> used radiopharmaceuticals and a gamma detector during surgery and identified the SLN in 82% of cases with a 100% accuracy rate. Using the blue dye, Giuliano et al.<sup>14</sup> obtained rates of 66% for node identification and 96% for accuracy. Albertini et al.<sup>3</sup> used the combination of dye+Tc99, attaining positive SLN identification 92% of the time with 100% accuracy. For the past 20 years, SLN biopsy, which is considered to be a minimally invasive procedure, has replaced axillary dissection with high accuracy (97 to 99%) in predicting the axillary lymph node status.

Since then, the SLN biopsy has become a standard tool for addressing the axilla in early breast cancer in many medical centers worldwide.<sup>12-16</sup> The release of the SLN biopsy method and increased knowledge of breast anatomy have resulted in many questions about the technical peculiarities of the method, the best site of injection, the best method, the best contrast and radiotracers, injection techniques, combinations of methods, the learning curve, tumor characteristics, and the morbidity associated with the method. In short, many variables are still under evaluation.

One of the important points that is being discussed concerns the role that surgery and previous breast biopsies play in identifying the SLN. Many authors exclude from their studies patients who were previously diagnosed by incisional biopsy or by formal excisional resections based on the assumption that these procedures could interfere in the identification of the SLN, increase the rates of false negatives and derail the method.<sup>3,17-25</sup> More recently, some researchers have suggested that previous excisional biopsies are no impediment to identifying the SLN.<sup>26,27</sup> In 2005, the American Society of Clinical Oncology released some information based on current data with limited levels of evidence, suggesting that SLN biopsy was not contraindicated in patients with previous diagnoses and excisional biopsies of the breast.<sup>12</sup>

Because of the importance of this topic, our study aimed to assess the influence of the para-areolar incision in the upper quadrant of the breasts of bitches, considering that this incision is a common practice of breast clinics when they are faced with patients with previous surgeries or biopsies. In these circumstances, the contrast has been injected into the edges and into the region overlying the scar without a previous SLN biopsy. The initial use of subareolar

**Table 4** - Comparison of the intersection of the methods discussed in this research to identify the SLN in the axilla (right and left breasts).

|                    |          | N  | %   |
|--------------------|----------|----|-----|
| SLN identification | Positive | 33 | 82% |
|                    | Negative | 7  | 18% |

SLN: Sentinel lymph node

**Table 5 - Identification of the SLN in the right and left cranial thoracic breasts of bitches when using technetium and patent blue (McNemar test).**

|                 |       | Tc99 |    | Total |
|-----------------|-------|------|----|-------|
|                 |       | Yes  | No |       |
| Patent Blue Dye | Yes   | 32   | 1  | 33    |
|                 | No    | 6    | 1  | 7     |
|                 | Total | 38   | 2  | 40    |

Tc99: technetium99 SLN: Sentinel lymph node  
 $p=0.1306/IC$  of 95% (McNemar Test)

Tc99 injection, with identification of the local projection of the SNL in the armpit after five minutes and the subsequent use of patent blue dye injected into the upper edge of the incision, as a method capable of identifying the SLN was purposely performed in that order because the distance between the areola and the axilla in the bitch is relatively small.

It is known that the greater the distance between the injection of the radio tracer and the uptake area of the radioactive material by the SLN, the better the lymph node identification by radio-guided surgery because interference is avoided between the markings of the injection site and the uptake site. This phenomenon was observed in this study because the SLN was identified in 95% of cases (38/40) with a sub-areolar Tc99 injection. Based on the anatomical-physiological similarity of the drainages of the human and bitch breast, we identified the sentinel node by injecting Tc99 into the subareolar region, and then, after identifying the presence of radiation in the projection in the axillary SLN, we performed the para-areolar incision for the left breast along with the injection of patent blue dye in the upper edge of the incision. The experiment demonstrated an SLN identification rate with blue dye and Tc99 of 95% (32/33) (Table 5-6).

In 33 of the 40 cases, there was agreement (82%) between the two methods of the SLN identification, i.e., between the percentage of lymph nodes that captured the Tc99 radioisotope and were stained with patent blue or that did not capture the Tc99 radioisotope and were not stained with the blue dye. The lymph nodes were not identified in 5% of breasts with the Tc99 subareolar injection method and in 17.5% using blue dye on the edge of the para-areolar incision. These findings indicate that the injection of contrast at the upper edge of the incision, involving the entire left upper quadrant of the bitch breast, presents a greater failure rate in identifying the SLN compared to injection of Tc99 into the breast. This fact can be explained by injury to the lymphatic drainage pathways that was caused by the para-areolar incision. The incision was

**Table 6 - Kappa coefficient of concordance when comparing technetium isolated with a combination of Tc99 and Patent blue dye in the identification of the SLN.**

|      |       | Tc99 + Patent Blue Dye |    | Total |
|------|-------|------------------------|----|-------|
|      |       | Yes                    | No |       |
| Tc99 | Yes   | 32                     | 6  | 38    |
|      | No    | 1                      | 1  | 2     |
|      | Total | 33                     | 7  | 40    |

Tc99: technetium99 SLN: Sentinel lymph node  
 Kappa = 0.157/Observed agreements: 82%

placed between the subareolar plexus and the lymphatic system that drains the upper left quadrant of the breast, in particular the section of the main collecting duct, so as not to allow part of the lymph nodes to capture the blue patent dye, as was shown in this model. In our study, due to the injection of the contrast in the upper edge of the incision, a positive SLN identification in 82% of cases (32/40) was obtained.

These results corroborate some of the findings that the most recent publications have emphasized; namely, there has been an emphasis on the recommendation of, not a contraindication to, SLN biopsy in patients with a previous excisional biopsy because a significant percentage of those patients may benefit from this method.<sup>26,27</sup> The hypothesis that the breast skin and underlying parenchyma drain into the same lymph nodes at the base of the axilla is based upon their common embryological origin<sup>28,29</sup>, justifying the injection of the tracer into the skin above the incision. Our experimental results reinforce this hypothesis.

**CONCLUSION**

In this study, 95% (38/40) of all lymph nodes captured 82% (33/40) of the Tc99 radioisotope and were stained with the blue dye. With one exception, all nodes were labeled as sentinel nodes (95%). In 82% of the cases (33/40), concordance between the methods was verified (Table 5). These findings may explain why many researchers initially exclude patients with previous breast biopsies from their studies because there is a decrease in the rate of identification of the SLN in cases where the lymphatic network of the upper quadrant of the left breast has been damaged by previous surgery. One fact that must be considered is that the canine experimental model we created does not evaluate time interference in the mapping of the sentinel node.

This study shows that lymph nodes found from injection at the upper edge of a recent incision correspond to the sentinel node in bitch breasts in 95% of cases (32/33). The rates of identification of the SLN by the subareolar injection of Tc99 and the injection of patent blue in the para-areolar incision were 95% (38/40) and 82% (32/40), respectively. A previous para-areolar incision in the upper outer breast quadrants of cranial thoracic bitch breasts does not interfere significantly in the identification of the sentinel lymph node when the dye is injected into the upper edge of a recent incision.

**REFERENCES**

1. Cabanas RM. An approach for the treatment of penile carcinoma. *Cancer*. 2000;39:456-466, doi: 10.1002/1097-0142(197702)39:2<456::AID-CNCR2820390214>3.0.CO;2-I.
2. Giuliano AE. Sentinel lymphadenectomy in primary breast carcinoma: an alternative to routine axillary dissection. *J Surg Oncol*. 1996;62:75-77, doi: 10.1002/(SICI)1096-9098(199606)62:2<75::AID-JSO1>3.0.CO;2-N.
3. Albertini JJ, Lyman GH, Cox C, Yeatman T, Balducci L, Ku N, et al. Lymphatic mapping and sentinel node biopsy in the patient with breast cancer. *JAMA*. 1996;276:1818-22, doi: 10.1001/jama.276.22.1818.
4. Morton DL, Wen DR, Wong JH, Economou JS, Cagle LA, Storm FK, et al. Technical details of intraoperative lymphatic mapping for early stage melanoma. *Arch Surg*. 1992;127:392-9.
5. Oliveira Filho RS, Santos ID, Ferreira LM, de Almeida FA, Simões e Silvia Enokihara MM, et al. Is intra-operative gamma probe detection really necessary for inguinal sentinel lymph node biopsy? *Sao Paulo Med J*. 2000;118:165-8, doi: 10.1590/S1516-3180200000600003.
6. Udi C. Axillary node Sample to Evaluate the Axilla. *World J Surg*. 2001;25:773-9, doi: 10.1007/s00268-001-0004-9.

7. Oliveira Filho RS, Silva AM, Hochman B, Oliveira RL, Arcuschin L, Wagner J, et al. Vital dye is enough for inguinal sentinel lymph node biopsy in melanoma patients. *Acta Cir Bras.* 2006;21:12-5, doi: 10.1590/S0102-86502006000100004.
8. Alex JC, Weaver DL, Fairbank JT, Rankin BS, Krag DN. Gamma-probe-guided lymph node localization in malignant melanoma. *Surg Oncol.* 1993;2:303-8, doi: 10.1016/S0960-7404(06)80006-X.
9. Krag DN, Weaver DL, Alex JC, Fairbank JT. Surgical resection and radiolocalization of the sentinel lymph node in breast cancer using a gamma probe. *Surg Oncol.* 1993;3:35-9, doi: 10.1016/0960-7404(93)90064-6.
10. McMasters KM, Wong SL, Martin RC 2nd, Chao C, Tuttle TM, Noyes RD, et al. Dermal injection of radioactive colloid is superior to peritumoral injection for breast cancer sentinel lymph node biopsy: results of a multiinstitutional study. *Ann Surg.* 2001;233:676-87, doi: 10.1097/0000658-200105000-00012.
11. Chagpar A, Martin RC, 3rd, Chao C, Wong SL, Edwards MJ, Tuttle T, et al. Validation of subareolar and periareolar injection techniques for breast sentinel lymph node biopsy. *Arch Surg.* 2004;139:614-8, doi: 10.1001/archsurg.139.6.614.
12. Lyman GH, Giuliano AE, Somerfield MR, Benson AB3rd, Bodurka DC, Burstein HJ, et al. American Society of Clinical Oncology guideline recommendations for sentinel lymph node biopsy in early-stage breast cancer. *J Clin Oncol.* 2005;23:7703-20, doi: 10.1200/JCO.2005.08.001.
13. Krag DN, Harlow S, Weaver D, Ashikaga T. Radiolabeled sentinel node biopsy: collaborative trial with the National Cancer Institute. *World J Surg.* 2001;25:823-8, doi: 10.1007/s00268-001-0012-9.
14. Giuliano AE, Kirgan DM, Guenther JM, Morton DL. Lymphatic mapping and sentinel lymphadenectomy for breast cancer. *Ann Surg.* 1994;220:391-8, doi: 10.1097/0000658-199409000-00015.
15. Wilke LG, Mccall LM, Posther KE, Whitworth PW, Reintgen DS, Leitch AM, et al. Surgical complications associated with sentinel lymph node biopsy: results from a prospective international cooperative group trial. *Ann Surg Oncol.* 2006;13:491-500, doi: 10.1245/ASO.2006.05.013.
16. Mansel RE, Fallowfield L, Kissin M, Goyal A, Newcombe RG, Dixon J, et al. Randomized multicenter trial of sentinel node biopsy versus standard axillary treatment in operable breast cancer: the ALMANAC Trial. *J. Natl. Cancer Inst.* 2006;98:599-609, doi: 10.1093/jnci/djj158.
17. Giuliano AE, Jones RC, Brennan M, Statman R. Sentinel lymphadenectomy in breast cancer. *J Clin Oncol.* 1997;15:2345-50.
18. Krag DN. Minimal access surgery for staging regional lymph nodes: the sentinel-node concept. *Curr Probl Surg.* 1998;35:951-1016.
19. Borgstein PJ, Pijpers R, Comans EF, van Diest PJ, Boom RP, Meijer S. Sentinel lymph node biopsy in breast cancer: guidelines and pitfalls of lymphoscintigraphy and gamma probe detection. *J Am Coll Surg* 1998;186:275-83, doi: 10.1016/S1072-7515(98)00011-8.
20. Veronesi U, Paganelli G, Viale G, Galimberti V, Luini A, Zurrada S, et al. Sentinel lymph node biopsy and axillary dissection in breast cancer: results in a large series. *J Natl Cancer Inst.* 1999;91:368-73, doi: 10.1093/jnci/91.4.368.
21. Rodier JF, Routiot T, Mignotte H, Janser JC, Bremond A, David E. Lymphatic mapping and sentinel node biopsy of operable breast cancer. *World J Surg.* 2000;24:1220-25, doi: 10.1007/s002680010240.
22. Giuliano AE, Haigh PI, Brennan MB, Hansen NM, Kelley MC, Ye W. Prospective observational study of sentinel lymphadenectomy without further axillary dissection in patients with sentinel node-negative breast cancer. *J Clin Oncol.* 2000;18:2553-9.
23. Mariani G, Moresco L, Viale G, Villa G, Bagnasco M, Canavese G. Radioguided sentinel lymph node biopsy in breast cancer surgery. *J Nucl Med.* 2001;42:1198-215.
24. D'Eredita G, Serio G, Mele M, Giardina C, Martellotta M, Ferrarese F. Effect of the use of vital dye, lymphoscintigraphy, or a combination for axillary lymphatic mapping and sentinel node biopsy in breast cancer. *World J Surg.* 2002;26:588-90, doi: 10.1007/s00268-001-0272-4.
25. Veronesi U, Paganelli G, Viale G, Luini A, Zurrada S, Galimberti V. A randomized comparison of sentinel-node biopsy with routine axillary dissection in breast cancer. *N Engl J Med.* 2003;349:546-53, doi: 10.1056/NEJMoa012782.
26. McMasters KM, Tuttle TM, Carlson DJ, Brown CM, Noyes RD, Glaser RL. Sentinel lymph node biopsy for breast cancer: a suitable alternative to routine axillary dissection in multiinstitutional practice when optimal technique is used. *J Clin Oncol.* 2000;18:2560-6.
27. Tafta L, Lannin DR, Swanson MS, Van Eyk JJ, Verbanac KM, Chua AN. Multicenter trial of sentinel node biopsy for breast cancer using both technetium sulfur colloid and isosulfan blue dye. *Ann Surg.* 2001;233:51-9, doi: 10.1097/0000658-200101000-00009.
28. Grant RN, Tabah J, Adair FE. The surgical significance of the subareolar lymph plexus in cancer of the breast. *Surgery.* 1953;33:71-78.
29. Turner-Warwick RT. The lymphatics of the breast. *Br J Surg.* 1959;574-82, doi: 10.1002/bjs.18004620004.