

CASE REPORT

Poststernotomy aspergillosis: successful treatment with voriconazole, surgical debridement and vacuum-assisted closure therapy

Rinaldo Focaccia Siciliano,^I Daniel Reis Waisberg,^{II} Marcos Naoyuki Samano,^{III} Paulo Ferreira Leite,^{III} Paulo Tuma Júnior,^{IV} Guilherme Cardinali Barreiro,^{IV} Tania Mara Varejão Strabelli^I

^IHospital das Clínicas (HCFMUSP), da Faculdade de Medicina da Universidade de São Paulo, Infection Control Team, Heart Institute (InCor), São Paulo/SP, Brazil. ^{II}Hospital das Clínicas (HCFMUSP), da Faculdade de Medicina da Universidade de São Paulo, Division of Thoracic Surgery, Heart Institute (InCor), São Paulo, Brazil. ^{III}Hospital das Clínicas (HCFMUSP), da Faculdade de Medicina da Universidade de São Paulo, Chronic Coronary Diseases Unit, Heart Institute (InCor), São Paulo, Brazil. ^{IV}Hospital das Clínicas (HCFMUSP), da Faculdade de Medicina da Universidade de São Paulo, Division of Plastic Surgery, São Paulo, Brazil.

Email: rinaldo_focaccia@uol.com.br
Tel.: 55 11 9891-6293

INTRODUCTION

Aspergillus spp. are ubiquitous in the environment, including the air, soil and decomposing material (1). Human invasive aspergillosis arises from the inhalation and contiguous spread of *Aspergillus* to adjacent sites (e.g., petrous bone, the sinuses, the palate). Occasionally, human invasive aspergillosis can be the result of the direct extension or hematogenous spread from pulmonary foci or of intravenous drug abuse (1). Invasive aspergillosis typically occurs in immunocompromised patients. Interestingly, some cases of surgical wound infection have been reported in immunocompetent individuals (1). The occurrence of post-operative aspergillosis can be associated with the dissemination of spores in the operating room through the ventilation system, which can lead to the contamination of exposed tissue, the surgical materials, the prosthesis or the wound dressing (1).

Deep bone wound infection is a severe complication of coronary artery bypass graft (CABG) surgery. Chronic osteomyelitis is unusual, reported in 1 to 4% of patients, and is most frequently caused by staphylococci (2,3). *Aspergillus* spp. are rare but recently recognized causes of nosocomial chronic sternal infections, including especially difficult-to-treat cases of osteomyelitis/costochondritis of the sternum (1).

The optimal treatment for invasive bone aspergillosis is a combination of surgical treatment and appropriate antifungal therapy. Currently, voriconazole is being advocated for the treatment of invasive aspergillosis (4,5). Herein, we report an unusual and very interesting case of chronic osteomyelitis and costochondritis caused by aspergillosis of the chest wall following cardiac surgery in an immunocompetent patient who was successfully treated with vacuum-assisted closure therapy following surgical debridement and voriconazole therapy.

CASE DESCRIPTION

A 59-year-old man with diabetes, hypertension, and hypercholesterolemia who had undergone coronary angioplasty three and a half years earlier underwent CABG in September 2008. The postoperative course was uneventful, and the patient was discharged nine days after the bypass surgery. The patient had been well until February 2009, when progressive and intense chest pain around the sternal wound and shoulders developed, followed by malaise and weight loss (approximately 7 kg). One week before admission, the patient experienced purulent discharge at the sternal wound. On evaluation, he appeared tired and restless; his blood pressure was 120 × 70 mmHg, his pulse was 100 beats per minute, his temperature was 36.9°C, and his respiratory rate was 18 breaths per minute. There was hyperemia limited to the sternal wound; the remainder of the examination was normal. Laboratory results at the time of admission revealed a robust increase in plasma C-reactive protein (181 mg/dL); hemoglobin 9.7 mg/dl; leukocytes 10800/mm³ (neutrophils 73%, lymphocytes 19%); platelets 633.000/mm³; urea 40 mg/dL; and creatinine 0.82 mg/dL. A chest tomography scan showed no bone abnormalities. All aerobic and anaerobic blood cultures (three samples) were sterile, and empiric intravenous therapy with vancomycin (1000 mg 12/12 hours) plus ciprofloxacin (400 mg 12/12 hours) was started. After four days, purulent wound discharge was observed. Technetium-99 m/Gallium-67 scintillography confirmed osteomyelitis in the region of the sternal wound.

The patient underwent aggressive surgical debridement by thoracic and plastic surgeons with the removal of steel stitches, which revealed bilateral infection in the 3rd to 8th costal cartilages (Figure 1A), which were partially removed (Figure 1B), and vacuum-assisted closure (VAC) was used. The subject remained on VAC until new surgical debridement was performed bilaterally on the 6th ribs four days later (Figure 1C). The VAC device was removed, a Portovac[®] tube was inserted, and the wound was closed primarily (Figure 1D). The patient had a favorable clinical evolution, without signs of systemic disseminated infection. Cartilaginous-bone tissue biopsies from the first and second

Copyright © 2012 CLINICS – This is an Open Access article distributed under the terms of the Creative Commons Attribution Non-Commercial License (<http://creativecommons.org/licenses/by-nc/3.0/>) which permits unrestricted non-commercial use, distribution, and reproduction in any medium, provided the original work is properly cited.

No potential conflict of interest was reported.

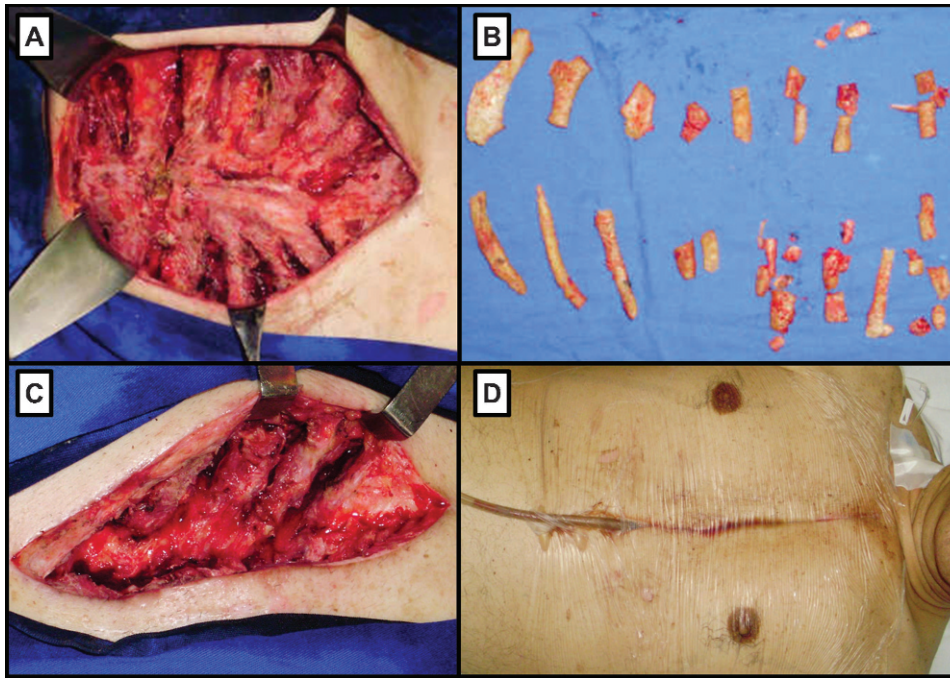


Figure 1 - A) Bilateral infection in the 3rd to 8th costal cartilages and ribs. **B)** 3rd to 8th bilateral costal cartilage removal. **C)** Second bilateral debridement of the 6th ribs on the 4th post-operative day. **D)** Final appearance of the wound with insertion of a Portovac® tube.

surgical procedures showed *Aspergillus* osteomyelitis. The culture from the surgically removed sternal bone demonstrated the presence of *Aspergillus* spp. Treatment with a combination of vancomycin and ciprofloxacin was discontinued, and intravenous voriconazole (4 mg/kg per dose twice daily) was started six days after the first surgery. The Portovac® tube was removed three days later, and the patient was discharged on the 18th day after the first surgical procedure. Intravenous voriconazole therapy was continued for a total of 42 days, when it was changed to oral capsules for 4 more months. After 3 months of voriconazole therapy, plasma C-reactive protein normalized, and Technetium-99 m/Gallium-67 scintillography showed no evidence of osteomyelitis. The patient currently remains very well, and the sternal wounds have healed completely.

DISCUSSION

Invasive aspergillosis affecting bone tissue is considered an unusual event, accounting for 1.8% to 5.6% of invasive aspergillosis cases (4,6), and has a high mortality rate (22.2% to 25%) (7,8). Vandecasteele et al. (7) reported that sternal wound infections developed at a median of 14 days after cardiac surgery in nine patients during an outbreak of *A. flavus*. In contrast, our patient had an incubation period of at least two months and experienced an insidious course with chest pain and weight loss diagnosed as osteomyelitis four months after the symptoms first appeared. The lack of fever, wound inflammation, and purulent or serous wound discharge delayed the suspicion of surgical-site infection. Similarly long incubation times were reported by Verghese et al. (9) (3 months) and Elahi et al. (2 months) in *Aspergillus* spp. osteomyelitis case reports (10).

Liposomal amphotericin B was considered the most suitable clinical treatment for invasive aspergillosis until recently (11). Another potential option is the new formulation of oral itraconazole solution, which penetrates bone tissue more effectively and can be used as a prolonged outpatient treatment. Vandecasteele et al. reported a 77.7% overall cure rate when combining itraconazole and surgical debridement, although 42.8% of the patients had multiple relapses that required multiple treatment courses (7). In the last few years, voriconazole emerged as the first-line antifungal agent for the treatment of invasive aspergillosis, based on its activity against *Aspergillus*, its acceptable side-effect profile, and the bioavailability of the oral formulation (12). The adverse effects reported include transient visual disturbances, hepatotoxicity, and severe photosensitivity rash (12), which must be taken into consideration when long courses of therapy are required, as in the case of osteomyelitis. Most studies have reported mild to moderate adverse effects, which did not lead to the discontinuation of therapy (4,8). In a case series of 12 patients with *Aspergillus* spp. osteomyelitis (8), 63.6% responded to antifungal combinations including voriconazole. Mouas et al. (4) reviewed the cases of 20 patients with bone aspergillosis treated with voriconazole (in 2 cases as first-line therapy and in 18 cases as salvage therapy because treatment had failed or the patient did not tolerate the previous antifungal therapy) and found that there was a satisfactory response in 55% of patients. In this study, when considering only immunocompetent patients, the response to therapy increased to 83.3% (5/6). The optimal duration of treatment for *Aspergillus* osteomyelitis is not known; however, a duration of several months is typically recommended (8,10).

The treatment for invasive bone aspergillosis is based on the combination of surgical and medical approaches.

Regardless of the antifungal drug used, most studies acknowledge the importance of surgical treatment. Stratov et al's review (5) indicates that the rate of successful cure among patients treated with amphotericin B was higher when treatment was used in combination with surgery (75% versus 14%). Aggressive surgical debridement may be required, as shown in the current and previous reports (10). In Elahi et al's case (10), a similar patient underwent four debridements, which briefly consisted of partial resection of the sternum and the 6th, 7th, 8th, 9th, and 10th ribs; reinforcement of the bilateral pectoralis major flaps with omentum; and the creation of a lateral myocutaneous flap and a triangular skin flap in combination with use of the vacuum-assisted curative system for wound closure. In our case, the collaboration of thoracic and plastic surgeons was required to assure that well-vascularized defect coverage could be achieved through reconstruction. The retention of small foci of osteomyelitis and costochondritis may be considered the main reasons for the failure of surgical debridement given the extreme vulnerability of costal cartilage to infection, especially when denuded of perichondrium or devascularized due to the use of the internal mammary artery (10).

The use of vacuum-assisted closure therapy has dramatically changed the treatment of complex wounds (13). Regarding chest wounds, most algorithms recommend its use following surgical debridement, as it allows for wound drainage, granulation stimulation, increased tissue blood flow, chest wall stabilization, chest cavity isolation to prevent contamination, and the maintenance of a moist environment (13). Consequently, the rate of reinfection and the length of the patient's hospital stay are decreased (14). Soft-tissue flaps are usually used for the definitive closure of deep sternal wounds, after vacuum-assisted closure therapy has been employed for several days (14). In our case, however, it was possible to perform primary closure.

In conclusion, invasive bone aspergillosis should be considered when dealing with slowly progressive chest wall wound infections following cardiac surgery, even in immunocompetent patients. It is increasingly accepted that voriconazole may be the drug of choice for the treatment of *Aspergillus* osteomyelitis, and aggressive surgical debridement is recommended to improve the rate of treatment success.

AUTHOR CONTRIBUTIONS

Siciliano RF, Waisberg DR, Samano MN, Leite PF, Tuma Júnior P and Barreiro GC contributed to data collection and manuscript preparation. Strabelli TM performed critical revision of the manuscript.

REFERENCES

1. Pasqualotto A, Denning D. Post-operative aspergillosis. *Clin Microbiol Infect*. 2006;12:1060-76, <http://dx.doi.org/10.1111/j.1469-0691.2006.01512.x>.
2. Zacharias A, Habib RH. Factors predisposing to median sternotomy complications. Deep vs superficial infection. *Chest*. 1996;110:1173-8, <http://dx.doi.org/10.1378/chest.110.5.1173>.
3. Parisian Mediastinitis Study Group. Risk factor for deep sternal wound infection after sternotomy: a prospective, multicenter study. *J Thorac Cardiovasc Surg*. 1996;111:1200-7, [http://dx.doi.org/10.1016/S0022-5223\(96\)70222-2](http://dx.doi.org/10.1016/S0022-5223(96)70222-2).
4. Mouas H, Lutsar I, Dupont B, Fain O, Herbrecht R, Lescure F, et al. Voriconazole for invasive bone aspergillosis: a worldwide experience of 20 cases. *Clin Infect Dis*. 2005;40:1141-47, <http://dx.doi.org/10.1086/428734>.
5. Stratov I, Korman T, Johnson P. Management of *Aspergillus* osteomyelitis: report of failure of liposomal amphotericin B and response to voriconazole in an immunocompetent host and literature review. *Eur J Clin Microbiol Infect Dis*. 2003;22:277-83.
6. Denning D, Stevens D. Antifungal and surgical treatment of invasive aspergillosis: review of 2,121 published cases. *Rev Infect Dis* 1990;12:1147-201, <http://dx.doi.org/10.1093/clinids/12.6.1147>.
7. Vandecasteele S, Boelaert J, Verrelst P, Graulus E, Gordts B. Diagnosis and treatment of *Aspergillus flavus* sternal wound infections after cardiac surgery. *Clin Infect Dis*. 2002;35:887-90, <http://dx.doi.org/10.1086/342699>.
8. Horn D, Sae-Tia S, Neofytos D. *Aspergillus* osteomyelitis: review of 12 cases identified by the Prospective Antifungal Therapy Alliance registry. *Diagn Microbiol Infect Dis*. 2009;63:384-87, <http://dx.doi.org/10.1016/j.diagmicrobio.2008.12.005>.
9. Verghese S, Chellamma T, Cherian K. Osteomyelitis of the rib caused by *Aspergillus flavus* following cardiac surgery. *Mycoses*. 2009;52:91-93, <http://dx.doi.org/10.1111/j.1439-0507.2008.01541.x>.
10. Elahi M, Mitra A, Spears J, McClurken J. Recalcitrant chest wall *Aspergillus fumigatus* osteomyelitis after coronary artery bypass grafting: successful radical surgical and medical management. *Ann Thorac Surg*. 2005;79:1057-59, <http://dx.doi.org/10.1016/j.athoracsur.2003.09.119>.
11. Stevens D, Kan V, Judson M, Morrison V, Dummer S, Denning D, et al. Practice guidelines for diseases caused by *Aspergillus*. Infectious Diseases Society of America. *Clin Infect Dis*. 2000;30:696-709, <http://dx.doi.org/10.1086/313756>.
12. Walsh T, Anaissie E, Denning D, Herbrecht R, Kontoyiannis D, Marr K, et al. Treatment of aspergillosis: clinical practice guidelines of the Infectious Diseases Society of America. *Clin Infect Dis*. 2008;46:327-60, <http://dx.doi.org/10.1086/525258>.
13. Orgill DP, Bayer LR. Update on Negative-Pressure Wound Therapy. *Plast Reconstr Surg*. 2011;127:1055-1155, <http://dx.doi.org/10.1097/PRS.0b013e318200a427>.
14. Cowan KN, Teague L, Sue SC, Mahoney JL. Vacuum-assisted wound closure of deep sternal infections in high-risk patients after cardiac surgery. *Ann Thorac Surg*. 2005;80:2205-12, <http://dx.doi.org/10.1016/j.athoracsur.2005.04.005>.