

BASIC RESEARCH

The effects of alpha-tocopherol supplementation on fracture healing in a postmenopausal osteoporotic rat model

Sharlina Mohamad,^{I,VI} Ahmad Nazrun Shuid,^I Norazlina Mohamed,^I Fazalina Mohd Fadzilah,^{III} Sabarul Afian Mokhtar,^{IV} Shahrum Abdullah,^V Faizah Othman,^{II} Fariah Suhaimi,^{II} Norliza Muhammad,^I Ima Nirwana Soelaiman^I

^IUniversiti Kebangsaan Malaysia, Faculty of Medicine, Department of Pharmacology, Kuala Lumpur/ Malaysia. ^{II}Universiti Kebangsaan Malaysia, Faculty of Medicine, Department of Anatomy, Kuala Lumpur/ Malaysia. ^{III}Universiti Kebangsaan Malaysia Medical Centre, Department of Radiology, Kuala Lumpur/ Malaysia. ^{IV}Universiti Kebangsaan Malaysia Medical Centre, Department of Orthopedics Kuala Lumpur/ Malaysia. ^VUniversiti Kebangsaan Malaysia, Faculty of Engineering, Department of Mechanical and Materials Engineering, Kuala Lumpur/ Malaysia. ^{VI}Universiti Sains Malaysia, Cluster of Integrative Medicine, Advanced Medical and Dental Institute (AMDI), Kepala Batas, Pulau Pinang/ Malaysia.

OBJECTIVE: Osteoporosis increases the risk of bone fractures and may impair fracture healing. The aim of this study was to investigate whether alpha-tocopherol can improve the late-phase fracture healing of osteoporotic bones in ovariectomized rats.

METHOD: In total, 24 female Sprague-Dawley rats were divided into three groups. The first group was sham-operated, and the other two groups were ovariectomized. After two months, the right femora of the rats were fractured under anesthesia and internally repaired with K-wires. The sham-operated and ovariectomized control rat groups were administered olive oil (a vehicle), whereas 60 mg/kg of alpha-tocopherol was administered via oral gavage to the alpha-tocopherol group for six days per week over the course of 8 weeks. The rats were sacrificed, and the femora were dissected out. Computed tomography scans and X-rays were performed to assess fracture healing and callus staging, followed by the assessment of callus strengths through the biomechanical testing of the bones.

RESULTS: Significantly higher callus volume and callus staging were observed in the ovariectomized control group compared with the sham-operated and alpha-tocopherol groups. The ovariectomized control group also had significantly lower fracture healing scores than the sham-operated group. There were no differences between the alpha-tocopherol and sham-operated groups with respect to the above parameters. The healed femora of the ovariectomized control group demonstrated significantly lower load and strain parameters than the healed femora of the sham-operated group. Alpha-tocopherol supplementation was not able to restore these biomechanical properties.

CONCLUSION: Alpha-tocopherol supplementation appeared to promote bone fracture healing in osteoporotic rats but failed to restore the strength of the fractured bone.

KEYWORDS: Bone; Fracture; Osteoporosis; Vitamin E; Alpha-tocopherol.

Mohamad S, Shuid AN, Mohamed N, Fadzilah FM, Mokhtar SA, Abdullah S, et al. The effects of alpha-tocopherol supplementation on fracture healing in a postmenopausal osteoporotic rat model. *Clinics*. 2012;67(9):1077-1085.

Received for publication on February 21, 2012; First review completed on March 28, 2012; Accepted for publication on May 7, 2012

E-mail: anazrun@yahoo.com

Tel.: 60 39 2897284

INTRODUCTION

Osteoporosis is a condition of skeletal fragility that is characterized by decreased bone mass and the microarchitectural deterioration of bone tissue, which lead to an increased

risk of bone fractures (1). Several anti-osteoporotic agents, such as estrogen replacement and bisphosphonate, are currently available. However, poor compliance with osteoporosis medication regimens is a serious problem; this issue may be associated with patients of lower educational status (2).

Postmenopausal osteoporosis is the most common form of age-related bone loss (3). Fractures secondary to osteoporosis are more common in women than in men, occurring with a one in three incidence ratio in women and a one in five incidence ratio in men (4). These types of fractures are also more common in Caucasians and Asians than African Americans and Latinos (5).

Copyright © 2012 CLINICS – This is an Open Access article distributed under the terms of the Creative Commons Attribution Non-Commercial License (<http://creativecommons.org/licenses/by-nc/3.0/>) which permits unrestricted non-commercial use, distribution, and reproduction in any medium, provided the original work is properly cited.

No potential conflict of interest was reported.

Fracture healing is a natural process that occurs in both normal and osteoporotic fractured bones. It is a complex process with three distinct phases: the reactive phase, the reparative phase and the remodeling phase (6). The reactive phase, which occurs immediately after fracture, lasts for approximately one week and is characterized by inflammation of the injured region and the formation of granulation tissue. The reactive phase is followed by the reparative phase, which involves the formation of the fracture callus and the deposit of lamellar bone. The final phase is the remodeling phase, which occurs approximately two months after fracture and involves the reshaping of the fractured bone to an approximation of its original contours.

The fracture healing process is further complicated in osteoporotic fractures. Previously published studies have demonstrated that osteoporosis can delay callus maturation and thereby decelerate fracture healing (7). Osteoporotic bone may completely heal after fracture, even under conditions of low bone density, low estrogen and/or low calcium, but the healing process may require a more extended period of time (8).

During the healing process, free radicals are generated that may impair healing, especially in the post-menopausal state, which has been associated with increased oxidative stress. Antioxidants, such as vitamin E, may therefore facilitate fracture healing by scavenging these free radicals and relieving oxidative stress (9-11). *Piper sarmentosum*, which contains antioxidants, has been found to improve fracture healing in osteoporotic states, as evidenced by a reduction in callus volumes and callus scores (12). Vitamin E, a fat-soluble vitamin with chain-breaking ability, has been demonstrated to increase bone trabecular formation (13,15) and prevent bone calcium loss in ovariectomized rats (14). There have been few studies regarding the effects of α -tocopherol, the most abundant form of vitamin E, on the fracture healing of normal bones. Sarisozen et al. (15) showed that α -tocopherol supplementation did not accelerate the fracture healing process in normal rats. However, Durak et al. (16) found that α -tocopherol supplementation was able to promote bone fracture healing in normal rabbits. Both of these studies addressed the effect of α -tocopherol on the fracture healing of normal bones; however, neither study examined the fracture healing of osteoporotic bones. Previously, we performed a study on the effects of α -tocopherol on the early phase of osteoporotic fracture healing, and we found that α -tocopherol supplementation facilitated the activities of antioxidants within the fractured osteoporotic bones, allowing these antioxidants to overcome the excessive free radicals released during the early phase of fracture healing (17). Therefore, the aim of the current study was to use an ovariectomized rat model to determine the effects of α -tocopherol supplementation on the late-phase fracture healing of osteoporotic bones.

MATERIALS AND METHODS

Animals and treatment

This study used 24 female Sprague-Dawley rats, each of which weighed between 250 and 300 g. These rats were divided into three groups; the first group was sham operated (SO), and the other two groups were ovariectomized. After two months, which allowed for osteoporosis to develop in the ovariectomized rats, the right femora of all of the rats were fractured under anesthesia using a blunt

guillotine method in accordance with Vialle et al. (18). All of the procedures were performed aseptically. Briefly, the rats were anesthetized using ketamine and xylazil (in a 1:1 ratio), which were administered intramuscularly at a dose of 0.1 ml/100 g weight. Iodine was then applied, and a small incision was made at the right knee of each rat. The right patella of each rat was dislocated, and a Kirschner wire (K-wire) (1.0 mm in diameter) was inserted with a drill into the intramedullary canal of the right femur for internal fixation. The right patella was relocated, and the incision was closed with sutures (nylon 4.0). A fracturer device was then used to fracture the right femur. This device used the guillotine principle to fracture the femur, thereby ensuring that a closed and standardized fracture was consistently produced. In particular, for each fracture, a three-point system was employed in which a 500 g blunt steel bar was dropped on the mid-diaphysis of a femur that was supported by two metal bases. The fracturer device has three platforms, each measuring 12.5 cm by 45 cm. The height from the middle platform to the lowest platform is 30 cm, and this height difference represents the distance through which the 500 g bar falls to produce the fractures. The upper platform, which is located 10 cm above the middle platform, helps to stabilize the construct and the steel bar, and the trigger that releases the steel bar is found on this platform. Baytril was injected intramuscularly to achieve perioperative antibiotic prophylaxis. For analgesic purposes, the rats were subcutaneously injected every 12 hours with buprenorphine at a dose of 0.3 mg/1 kg rat weight. The right femora of the rats were immediately X-rayed using an X-ray machine (Proteus XR/a, GE Healthcare, North Grandview, Waukesha, USA) to ensure that fractures had occurred at mid-diaphysis and that the K-wires were correctly inserted (Figure 1A). The rats were allowed unrestricted weight-bearing activities after they recovered from the anesthesia.

The ovariectomized rats were then randomly divided into an ovariectomized control (OVXC) group and an α -tocopherol-treated (ATF) group. All of the rats were housed in individual cages at room temperature under natural day/night cycle conditions. They were fed rat chow (Gold Coin, Malaysia) and provided with deionized water *ad libitum*. The ATF-treated group was given α -tocopherol acetate (Sigma, USA) at a dose of 60 mg/kg rat weight. The SO and OVXC groups were given olive oil (Bertolli, Italy), which acted as a vehicle. Olive oil was also used as a diluent for the α -tocopherol. Both olive oil and α -tocopherol were administered via oral gavage for six days per week over the course of eight weeks (14). The rats were then euthanized, and the fractured femur was carefully removed to prevent any damage to the bone. Post-mortem examinations of the rats were performed to confirm their postmenopausal conditions, and the atrophy of the uterus in each rat was observed. The femur samples were evaluated for fracture healing and callus strength immediately after they were harvested. During the short period between the harvesting and the testing of the femora, they were kept at 4°C and wrapped in gauze that had been soaked with phosphate-buffered solution to minimize degradation and drying. This study was approved by the UKM Animal Ethics Committee (FP/FAR/2008/NAZRUN/13-FEB/217-FEB-2008-FEB2010).

Computed tomography scanning

The femora were scanned using a computed tomography (CT) system (Somatom Sensation 64, Germany), which uses

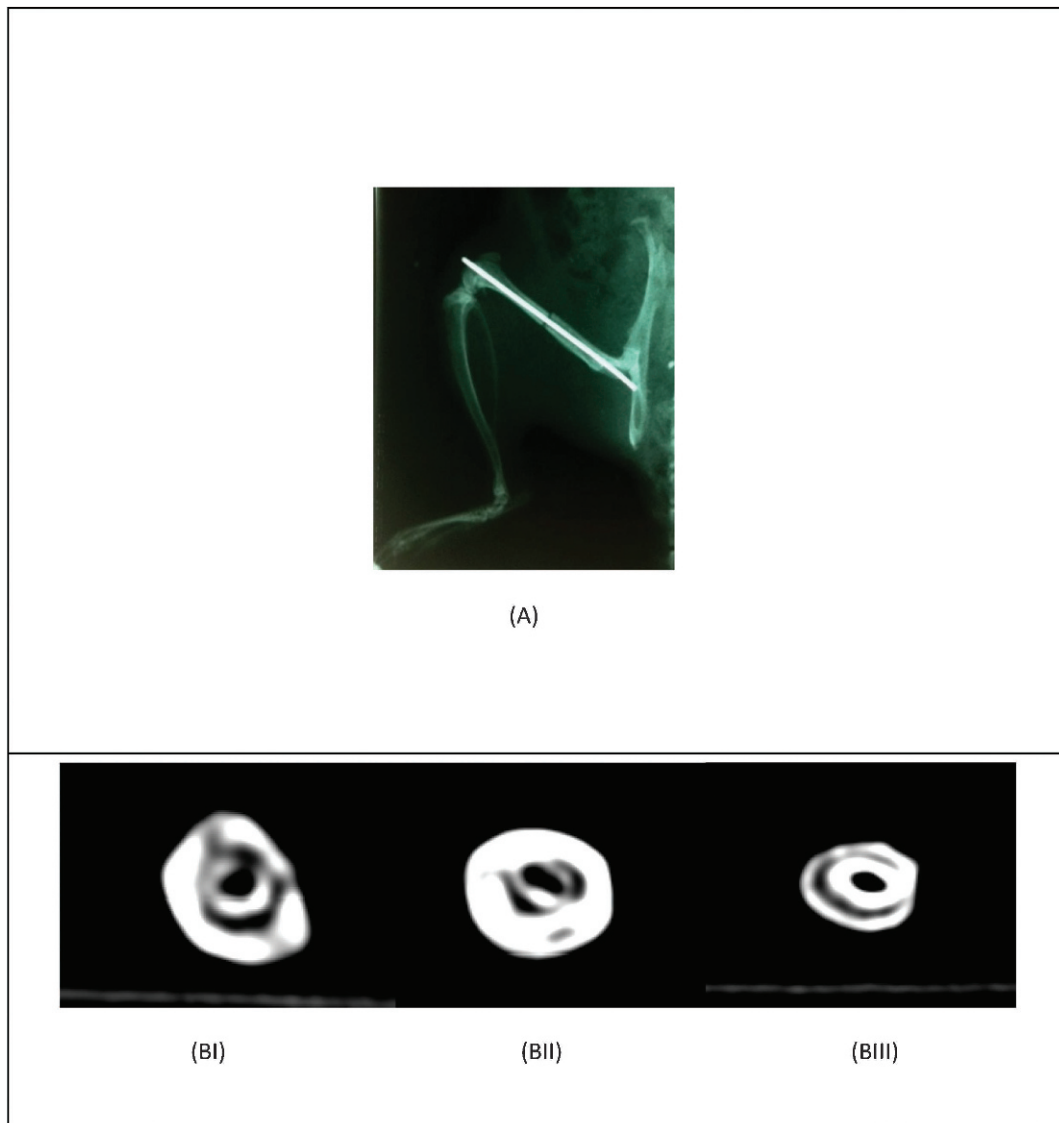


Figure 1 - (A) An representative X-ray image used to confirm successful K-wire insertion and that the fractures were in the mid-diaphyseal region. **(B)** Axial view of healed fractured femora from CT scan images. (I) SO group; (II) OVXC group; (III) ATF group.

an X-ray tube (120 kV; 40 mAs) to produce a narrow fan beam of X-rays. The CT scans were performed at a slice thickness of 0.6 mm, an in-plane voxel size of 0.234 mm, and a matrix size of 512×512 pixels. The manufacturer's software package (*ver. 2006A*) was used for image processing and data evaluation. The scanner was first calibrated using a water phantom with a radiodensity of 0 Hounsfield units (HUs) and a density of 1.0 g/cm³. The axial callus volume was then measured from the CT images that were obtained at 1 cm above and 1 cm below the diaphyseal fracture. The total callus volume was calculated in terms of mm³/cm³ (Figure 1: BI, BII and BIII).

X-ray imaging

The femora were then examined through X-ray imaging. Anteroposterior and lateral images were obtained using a high-resolution digital radiography system (Philips Digital Diagnost/Optimus 80 system) at 46 kV, 2.5 mAs and 10.6 ms of exposure. The stage of fracture healing was assessed by a radiologist and quantified using a 5-point

radiographic scoring system that was modified from Warden et al. (19) (Table 1A). The callus stage was also assessed by the same radiologist using a 5-point scoring system (Table 1B) based on visual assessments of the appearance of the callus on the healed bones in the X-ray images (20) (Figure 2: A, B and C).

Bone biomechanical testing

The harvested right femora were wrapped in gauze dipped in phosphate-buffered saline (PBS) to prevent them from drying out. The temperature was maintained at 4°C to slow bone degradation. The biomechanical strength of the calluses was assessed using an Instron machine (Instron Microtester 5848, Instron Corp, USA) with a Bluehill software package. Each femur was placed in a three-point bending configuration, and a load was applied at the speed of 5 mm/min on the mid-point of the femora diaphysis on the anterior surface, compressing the anterior surface and increasing the tension of the posterior surface until the bone re-fractured. The width between the two lower supports

Table 1 - The 5-point radiographic scoring system (modified from Warden et al. 2009) used to assess (A) the fracture healing stage and (B) the callus stage (Nazrun et al. 2010).

Score	Description
0	No evidence of healing
1	Callus formation evident but fracture gap not bridged
2	Callus formation evident with bridging of the fracture gap but fracture line evident
3	Callus formation evident with bridging of the fracture gap with only faint fracture line
4	Fracture union

Score	Description
0	No callus
1	Callus + (very minimal callus)
2	Callus ++ (minimal callus)
3	Callus +++ (moderate callus)
4	Callus ++++ (exuberant callus)

that held the femora was 10 mm. The load, stress, and strain parameters were recorded by the software. For each femur, a stress versus strain graph was plotted, and a Young's modulus value was derived from the gradient of the resulting curve. This procedure was performed in a blinded manner with respect to the test groups.

Statistical analyses

The results were expressed as the means ± the standard error of each mean (SEM). The data analysis was performed using the Statistical Package for Social Sciences software (SPSS version 16.0, USA). The data were tested for normality using the Kolmogorov-Smirnov test. The statistical tests performed were ANOVA followed by Tukey's HSD for normally distributed data; for data that were not normally distributed, the Kruskal-Wallis and Mann-Whitney tests were performed. The level of significance was $p < 0.05$.

RESULTS

CT scanning

After two months of treatment, CT scanning indicated that the fractured femora of the rats in the OVXC group had significantly higher callus volumes compared with the fractured femora of rats in the SO group (Figure 3A). The abundance of callus tissue in the OVXC group compared with the SO group indicated the impaired fracture healing of osteoporotic bones because by the late stages of fracture healing, most of the callus should have been resorbed and replaced with lamellar bone through the bone remodeling process. The callus volume of the α-tocopherol group was similar to the callus volume of the SO group. Therefore, α-tocopherol supplementation appeared to be able to improve the fracture healing of osteoporotic bone.

X-ray imaging

X-ray images of the healed fractured femur were examined, and the stages of the fracture healing and the callus were determined. The staging was assessed using the previously described 5-point scoring system (Table 1B). For fracture healing staging, all of the groups had average scores above 2, indicating that progress in fracture healing had occurred (Figure 3B). As expected, the OVXC group scored lower than the SO group with respect to fracture healing. The scores for the ATF group were not significantly different from either the SO or the OVXC group. The callus staging results were consistent with the CT scan results, as the SO and ATF groups had significantly lower callus stages than the OVXC group (Figure 3C). All of these data are presented in Table 2.

Bone biomechanical testing

The strengths of the healed mid-diaphyseal fractures were determined by conducting a biomechanical test on the calluses. There were no significant differences in the stress values for any of the groups (Figure 4A). Therefore, the

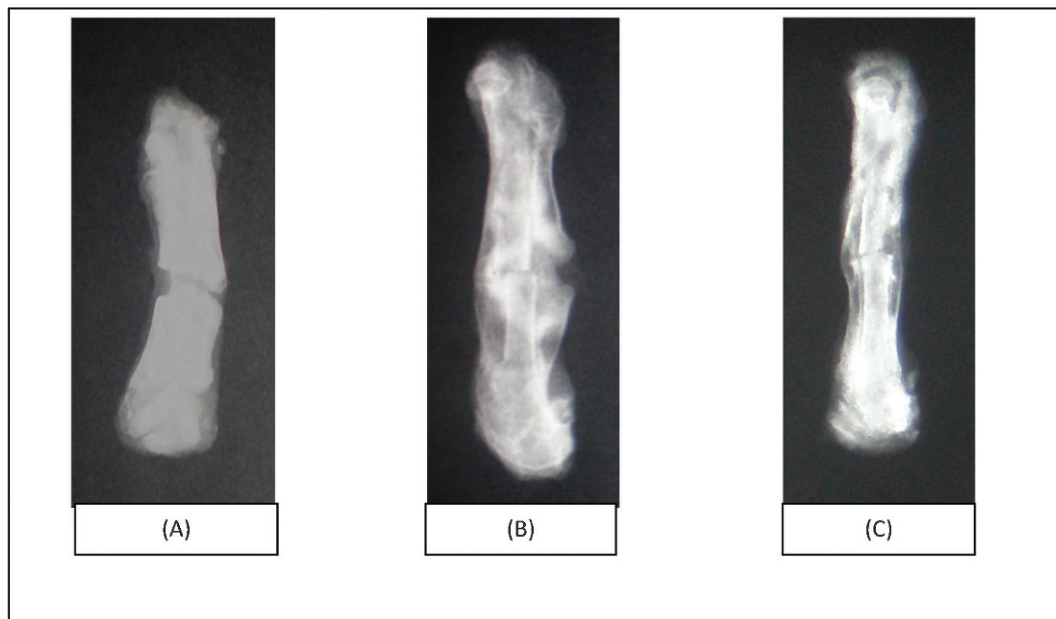
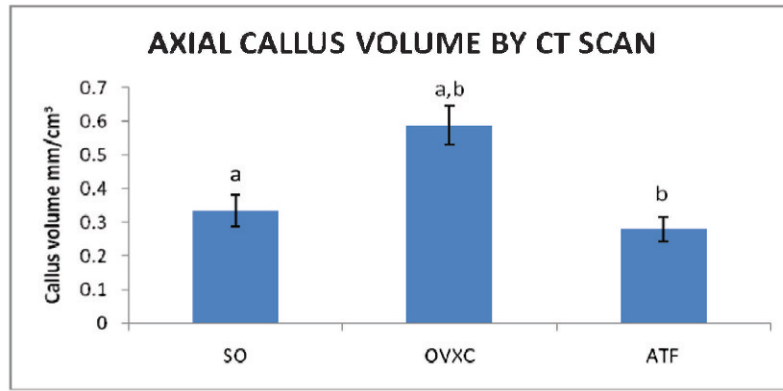
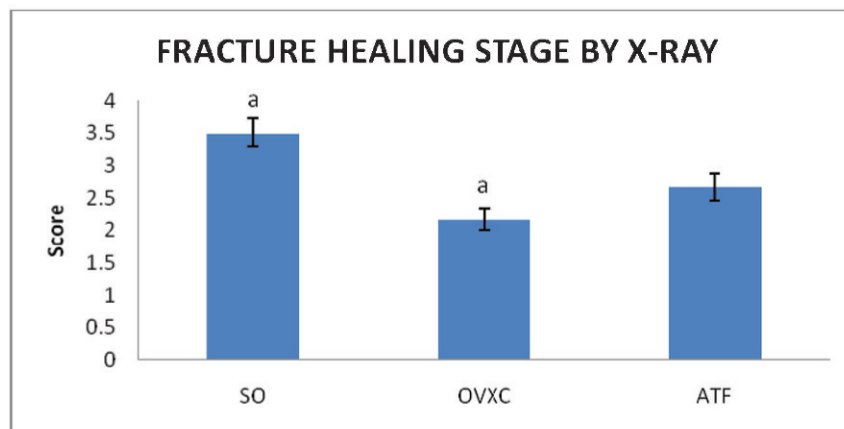


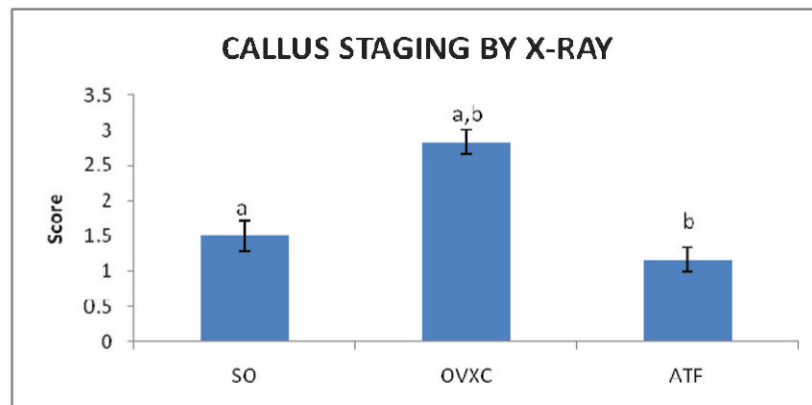
Figure 2 - X-ray images of a healed fractured femur from each group. (A) SO group; (B) OVXC group; (C) ATF group.



(A)



(B)



(C)

Figure 3 - (A) The bar chart indicates the axial callus volumes, which were measured and calculated using CT scanning. **(B)** The bar chart indicates the fracture healing stages obtained from the radiological scoring of X-ray images. **(C)** The bar chart indicates the callus staging scores obtained from the radiological scoring of X-ray images. SO: sham-operated group; OVXC: ovariectomized control group; ATF: ovariectomized + ATF-supplemented group; Values with the same alphabetical symbol are significantly different at $p < 0.05$.

Table 2 - The axial callus volume measured and calculated using CT scan, fracture healing stage based on radiological scoring assessed from X-ray images, and callus staging scores based on radiological scoring assessed from X-ray images.

CT Scan & X-ray	SO		OVXC		ATF	
	Mean	SD	Mean	SD	Mean	SD
Axial callus volume by CT scan (mm/cm ³)	0.34	±0.05	0.59*	±0.06	0.28 [#]	±0.04
Fracture healing stage by CT scan	3.5	±0.22	2.17*	±0.17	2.67	±0.21
Callus staging by X-ray	1.5	±0.22	2.83*	±0.17	1.17 [#]	±0.17

calluses of all of the groups were able to handle similar quantities of stress before they fractured. With respect to the strain value, the SO group was found to have a significantly higher strain value than either the OVXC group or the ATF group. There was no significant difference in the strain values observed for the OVXC and ATF groups (Figure 4B). The same pattern was observed for the load values, as the SO group had significantly higher load values than both the OVXC and ATF groups, whereas the OVXC and ATF groups did not differ significantly with respect to this metric (Figure 4C). This result indicates that the calluses of the

fractured femora of the SO group were able to handle the highest amount of strain and load, whereas the calluses of the OVX and ATF groups had similarly inferior capabilities. There were no significant differences in the Young’s modulus parameter for the three groups (Figure 4D). All of the data for bone biomechanical testing are presented in Table 3.

DISCUSSION

The main objective of this study was to evaluate the effects of vitamin E (specifically, α -tocopherol) supplementation on

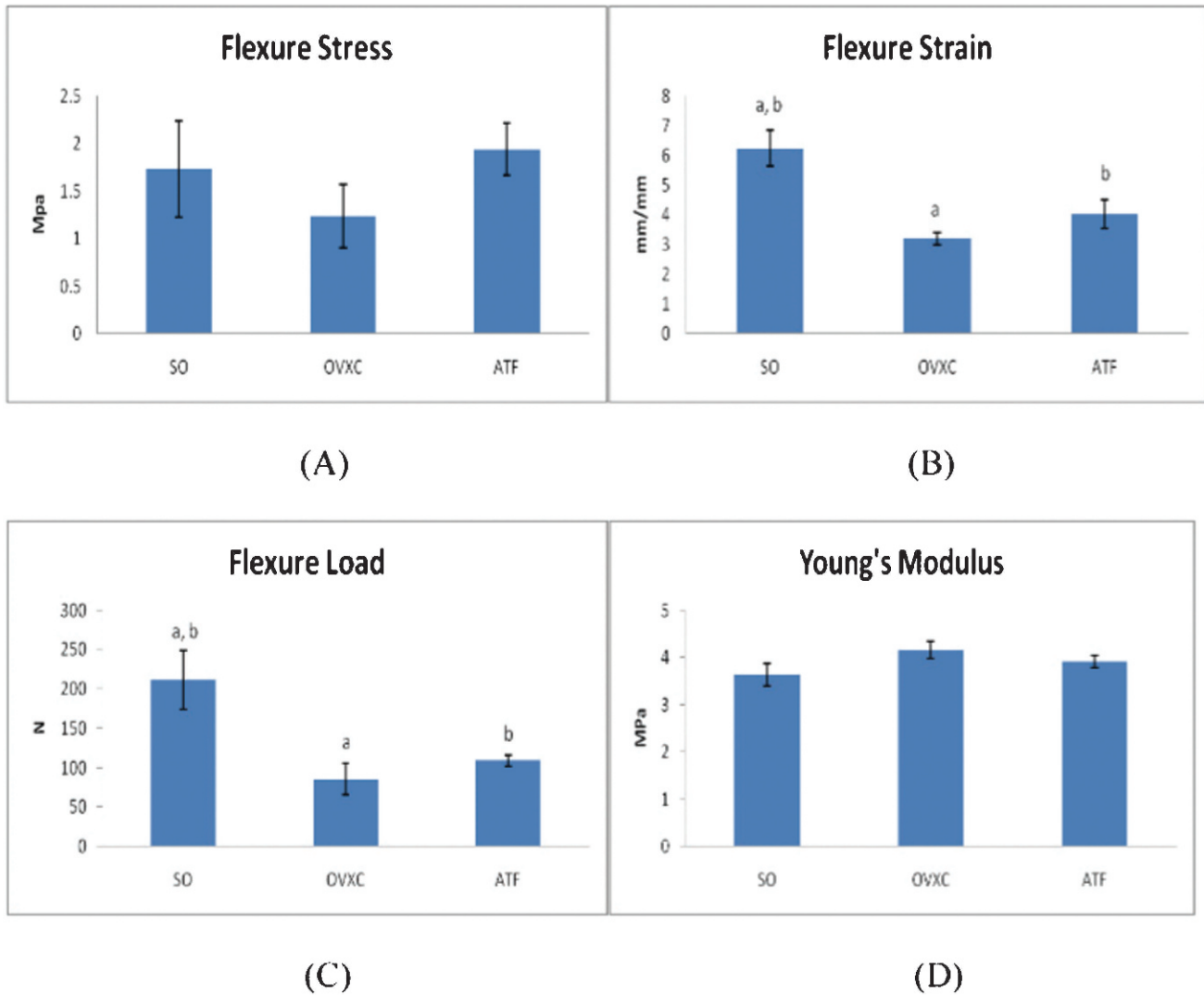


Figure 4 - (A) The bar chart illustrates the stress parameters derived from bone biomechanical testing. (B) The bar chart indicates the strain parameters derived from bone biomechanical testing. (C) The bar chart illustrates the load parameters derived from bone biomechanical testing. (D) The bar chart indicates the Young’s modulus values derived from bone biomechanical testing. SO: sham-operated group; OVXC: ovariectomized control group; ATF: ovariectomized + ATF-supplemented group; Values with the same alphabetical symbol are significantly different p<0.05.

Table 3 - The stress, strain, load, and Young’s modulus parameter derived from the bone biomechanical testing.

Biomechanical test	SO		C		ATF	
	Mean	SD	Mean	SD	Mean	SD
Flexure stress (MPa)	1.73	± 0.51	1.24	± 0.33	1.95	± 0.28
Flexure strain (mm/mm)	6.25	± 0.59	3.20*	± 0.21	4.03*	± 0.49
Flexure load (N)	212.23	± 37.56	85.90*	± 19.93	109.27*	± 7.02
Modulus (MPa)	3.64	± 0.24	4.17	± 0.19	3.92	± 0.13

SO: sham-operated group.
OVXC: ovariectomized control group.
ATF: ovariectomized + ATF-supplemented group.
p-values <0.05 were considered to be significant (*p<0.01 vs. SO group, #p<0.002 vs. OVXC group).

the late-phase fracture healing of osteoporotic bone. In this study, rat femora were fractured two months after rat ovariectomies, and a subset of the rats was supplemented with α-tocopherol for an additional two months before being sacrificed. Ovariectomized rats are an established model for the study of postmenopausal osteoporosis (21,22) and osteoporotic fractures (23,24). Previous studies have demonstrated that bone mineral densities are significantly lower in ovariectomized rats than in control rats at eight and 12 weeks after ovariectomy (11). A study by Estai et al. demonstrated that the expression of serum TGFβ-1 was reduced and the callus strength was compromised in rats at six weeks after ovariectomy (25). Of the fracture techniques available (26-29), we chose the guillotine method described by Vialle et al. in 2004 (18) because this method produces a consistent fracture of the femur with less trauma to the surrounding tissues. Thus, this method mimics the conditions of most osteoporotic fractures, which occur as a result of trivial force. Surgical fractures may cause vascular injuries that increase the incidence of either the delayed union or the non-union of fractures (30).

The duration of fracture healing was critical in this study. We allowed the fractured femur to heal for two months; this duration was expected to correspond to the late phase of the fracture healing process. In normal fracture healing, two months of healing would be sufficient to allow the callus formed earlier in the reparative phase to be mostly replaced by lamellar bone. A longer duration of healing might not allow us to detect any differences in the healing rate between the examined groups, given that complete fracture healing occurred at three months post-fracture in both ovariectomized and sham-operated rats (8).

Oxidative stress is believed to be the underlying pathology that causes bone loss in osteoporotic bones. This mechanism explains why vitamin E (an antioxidant) can protect osteoporotic bones against further bone loss (31) and improve the fracture healing process. In fact, a study by Maniam et al. (32) found that vitamin E both suppressed lipid peroxidation and increased glutathione peroxidase activity in the bone.

A recent study investigated the effects of α-tocopherol on the early phase of osteoporotic fracture healing (17). In that study, at two weeks after fracture (corresponding to the early phase of fracture healing), the healing of the ovariectomized control group was found to be inferior to the healing of the sham-operated group, whereas the

radiological scoring of fracture healing (as measured by fracture stages) was similar for the α-tocopherol and sham-operated groups. In the present study, which addresses late-phase fracture healing, similar findings were obtained. In particular, the OVXC group had lower fracture stage scores than the SO group. Callus staging indicated that α-tocopherol supplementation could recover the fracture healing ability of osteoporotic bone. In another study of the early phase of fracture healing, the calcium supplementation of rats improved the radiologically assessed fracture healing of osteoporotic bone but failed to restore the strength of the healed fractured bones (20). Several studies have demonstrated the beneficial effects of α-tocopherol on bone metabolism. Smith et al. (33) reported that α-tocopherol supplementation alters bone metabolism in mature animals and protects against bone loss in the hind limb of unloaded rats. Other studies have demonstrated similar osteoprotective properties of vitamin E in other animal models of bone loss, such as ovariectomized rats (34) and aged (24 months old) mice (35). A study by Turk et al. (36) reported that α-tocopherol has a positive effect on both the early and late phases of fracture healing. The radiological evaluation demonstrated that α-tocopherol supplementation improved the late-phase fracture healing (60 days) of normal rats. In our study, the α-tocopherol supplementation of ovariectomized rats did not produce any significant improvements in the fracture healing stage compared with unsupplemented ovariectomized rats. However, vitamin E treatment did significantly improve the fracture healing of ovariectomized rats with respect to callus volume and callus staging.

The rats supplemented with α-tocopherol did not show any signs or symptoms of toxicity throughout the eight weeks of the study. Previous toxicity studies of vitamin E by Ima et al. (37) showed that doses of palm vitamin E that were much greater than the effective dose used to treat or prevent osteoporosis (in particular, doses above 200 mg/kg) may cause bleeding tendencies and renal impairment but did not appear to produce liver toxicities.

In the rat model, the size of the fracture callus can be approximately 400% larger than the bone itself before this callus is resorbed to a bone-equivalent size during the remodeling phase of fracture healing. In humans, a fracture treated with a cast, splint or surgery is typically only approximately 25 to 100% larger than the bone. Our findings regarding callus volumes indicated that the SO and ATF groups had similar callus volumes, which were lower than the callus volumes of the OVXC group. At the second month of fracture healing, which corresponds to the remodeling phase, the excess callus should be actively resorbed. Therefore, the smaller calluses of the SO and ATF groups indicated that fracture healing was more advanced in those groups than in the OVXC group. This evidence has proven that α-tocopherol supplementation is able to promote the fracture healing of osteoporotic bones of rats in which osteoporosis had been induced through ovariectomies. This result was consistent with the callus staging parameter, which indicated that the SO and ATF groups had lower callus stages than the OVXC group.

Because the callus volumes and stages of the SO and ATF groups were similar, we would expect both of these groups to have similar but superior callus strength relative to the OVXC group. As expected, the ovariectomized rats had lower load and strain values compared with the sham

group. However, we found that the α -tocopherol supplementation of ovariectomized rats failed to improve the ability of their calluses to withstand loads and strains.

A study by Norazlina et al. demonstrated that α -tocopherol supplementation was unable to prevent the loss of bone calcium in ovariectomized rats (14). Because calcium is one of the main minerals in calluses, this previous study may provide an explanation for why the callus strength was not restored after α -tocopherol supplementation. In a study of the fracture healing of tibias from rats with osteoporosis induced by sciatic neurectomy, Nordsletten et al. (38) found that 25 days after fracture, callus formation and bone mineral density were higher in the sciatic neurectomized rats, but the callus strengths of the sciatic neurectomized rats and the normal control rats did not differ significantly. Several other studies have produced contrasting results regarding the strength of osteoporotic bones after fracture healing. Langeland (39) reported that the strength of fractured tibial bones at two weeks after fracture did not differ significantly between ovariectomized and normal control rats. Blythe and Buchsbaum (40) reported similar findings in the same model at five weeks after fracture.

In this study, although two months of α -tocopherol treatment was sufficient to produce accelerated healing in ovariectomized rats, this treatment did not appear to improve the strength of the healed bone. Therefore, the α -tocopherol treatment period may need to be increased to produce improved bone strength. Alternatively, the administration of a higher dose of α -tocopherol may improve the bone strength of osteoporotic rats.

We can conclude from this study that based on the X-ray and CT scan results, the α -tocopherol supplementation of osteoporotic rats appears to promote bone fracture healing; however, based on the results of the bone biomechanical testing, α -tocopherol supplementation does not appear to restore the strength of healed fractured bones.

ACKNOWLEDGMENTS

The study was conducted with funding from the UKM-SK-07-21-202 grant. We would like to thank Mrs. Mazliadriyana, Mrs. Sinar Suria, and Mrs. Azizah from the Department of Pharmacology; Mr. Faridz from the Department of Mechanical and Materials Engineering; and Miss Farhana from the Department of Imaging and Radiology for their technical assistance. We would also like to thank the Epidemiological Unit of the Pharmacology Department for its statistical assistance. This experiment complied with the current laws of Malaysia.

AUTHOR CONTRIBUTIONS

Mohamad S prepared the manuscript, treated the animals and performed the laboratory analysis. Shuid AN developed the concept and design of the study and reviewed the manuscript. Mohamed N, Othman F, Suhaimi F and Muhammad N reviewed the manuscript. Fadzilah FM reviewed the manuscript and interpreted the radiographic parameters of the study. Mokhtar SA reviewed the manuscript and the fracture methodology. Abdullah S reviewed the manuscript and the biomechanical testing parameters. Soelaiman IN developed the concept of the study and reviewed the final manuscript version.

REFERENCES

1. Consensus Development Conference. Prophylaxis and treatment of osteoporosis. *Am J Med.* 1991;90(1):107-10.
2. Cevikoi A, Umay E, Polat S, Ecerkale O, Cakci A. The relationship between bisphosphonate use and demographic characteristics of male

- osteoporosis patients. *Clinics.* 2011;66(4):579-82, <http://dx.doi.org/10.1590/S1807-59322011000400010>.
3. Albright F, Smith P, Richardson A. Postmenopausal osteoporosis: Its clinical features. *J Am Med Assoc.* 1947;116:2465-74, <http://dx.doi.org/10.1001/jama.1941.02820220007002>.
4. Kanis JA, Johnell O, Oden A, Sembo I, Redlund-Johnell I, Dawson A, et al. Long-term risk of osteoporotic fracture in Malmo. *Osteoporosis international: a journal established as result of cooperation between the European Foundation for Osteoporosis and the National Osteoporosis Foundation of the USA.* 2000;11(8):669-74, <http://dx.doi.org/10.1007/s001980070064>.
5. National Osteoporotic Foundation. 2025 osteoporosis prevalence figures: state by state report. January 1997. *Women's Health Matters* 1998; 2(30):1.
6. Cruess RL, Dumont J. Healing of bone, tendon, and ligament. In: Rockwood CA, Green DP, (eds): *Fractures.* JB Lippincott, Philadelphia 1975; p97.
7. Dai K, Hao Y. Quality of Healing Compared Between Osteoporotic Fracture and Normal Traumatic Fracture. In: Qin L, Genant HK., Griffith JF, Leung KS, editors. *Advanced Bioimaging Technologies in Assessment of the Quality of Bone and Scaffold Materials Techniques and Applications.* Springer, Berlin Heidelberg, 2007;p531-41.
8. Kubo T, Shiga T, Hashimoto J, Yoshioka M, Honjo H, Urabe M, et al. Osteoporosis influences the late period of fracture healing in a rat model prepared by ovariectomy and low calcium diet. *The Journal of steroid biochemistry and molecular biology.* 1999;68(5-6):197-202, [http://dx.doi.org/10.1016/S0960-0760\(99\)00032-1](http://dx.doi.org/10.1016/S0960-0760(99)00032-1).
9. Burton GW, Ingold KU. Vitamin E as an in vitro and in vivo antioxidant. *Ann N Y Acad Sci.* 1989;570:7-22, <http://dx.doi.org/10.1111/j.1749-6632.1989.tb14904.x>.
10. Burton GW, Traber MG. Vitamin E: antioxidant activity, biokinetics, and bioavailability. *Annu Rev Nutr.* 1990;10:357-82, <http://dx.doi.org/10.1146/annurev.nu.10.070190.002041>.
11. Van Acker SA, Koymans LM. Bast A: Molecular pharmacology of vitamin E: structural aspects of antioxidant activity. *Free Radic Biol Med.* 1993;15(3):311-28, [http://dx.doi.org/10.1016/0891-5849\(93\)90078-9](http://dx.doi.org/10.1016/0891-5849(93)90078-9).
12. Estai MA, Suhaimi FH, Das S, Fadzilah FM, Alhabshi SM, Shuid AN, et al. Piper sarmentosum enhances fracture healing in ovariectomized osteoporotic rats: a radiological study. *Clinics.* 2011;66(5):865-72, <http://dx.doi.org/10.1590/S1807-59322011000500025>.
13. Xu H, Watkins BA, Seifert MF. Vitamin E stimulates trabecular bone formation and alters epiphyseal cartilage morphometry. *Calcif Tissue Int.* 1995;57(4):293-300, <http://dx.doi.org/10.1016/BF00298885>.
14. Norazlina M, Ima-Nirwana S, Abdul Gapor MT, Abdul Kadir Khalid B. Tocotrienols are needed for normal bone calcification in growing female rats. *Asia Pac J Clin Nutr.* 2002;11(3):194-9, <http://dx.doi.org/10.1046/j.1440-6047.2002.00290.x>.
15. Sarisozen B, Durak K, Dincer G, Bilgen OF. The effects of vitamin E and C on fracture healing in rats. *J Int Med Res.* 2002;30(3):309-313.
16. Durak K, Sinmez G, Sarisozen B, Ozkan S, Kaya M, Ozturk C. Histological assessment of the effect of α -tocopherol on fracture healing in rabbits. *J Int Med Res.* 2003;31(1):26-30.
17. Nazrun AS, Sharlina M, Norliza M, Fazalina MF, Sabarul AM, Norazlina M, et al. Effects of α -Tocopherol on the early phase of osteoporotic Fracture Healing. *Journal of Orthopaedic Research.* 2011;29(11):1732-8.
18. Vialle E, Vialle LR, Boechat R. Producao de fractura padrinizada de femur em ratos. *Rev Bras Ortop.* 2004;39:323-329.
19. Warden SJ, Komatsu DE, Rydberg J, et al. Recombinant human parathyroid hormone (PTH 1-34) and low intensity pulsed ultrasound have contrasting additive effects during fracture healing. *Bone.* 2009;44(3):485-94, <http://dx.doi.org/10.1016/j.bone.2008.11.007>.
20. Shuid AN, Mohamad S, Mohamed N, Fadzilah FM, Mokhtar SA, Abdullah S, et al. Effects of calcium supplements on fracture healing in a rat osteoporotic model. *Journal of Orthopaedic Research.* 2010; 28(12):1651-6, <http://dx.doi.org/10.1002/jor.21180>.
21. Wimalawansa SJ. Therapeutic options in prevention and treatment of osteoporosis. *Exp Clin Endocrinol.* 1993;12:1-27.
22. Wronski TJ, Dann LM, Qi, Yen CF. Skeletal effects of withdrawal of estrogen and diphosphonate treatment in ovariectomized rats. *Calcif Tissue Int.* 1993;53(3):210-6, <http://dx.doi.org/10.1007/BF01321840>.
23. Hao Y, Dai K. An experimental study of vascular endothelial growth factor (VEGF) expression in fracture healing. *Chin J Orthop.* 2002;19:683-6.
24. Hao Y, Dai K. The design and establishment of a model of experimental osteoporotic fracture. *Orthop J Chin.* 2002;9:569-72.
25. Estai MA, Suhaimi FH, Das S, Fadzilah FM, Alhabshi SM, Shuid AN, Soelaiman IN. Piper sarmentosum enhances fracture healing in ovariectomized osteoporotic rats: a radiological study. *Clinics.* 2011;66(5):865-72, <http://dx.doi.org/10.1590/S1807-59322011000500025>.
26. Bonnarens F, Einhorn TA. Production of a standard closed fracture in laboratory animal bone. *J Orthop Res.* 1984;2(1):97-101, <http://dx.doi.org/10.1002/jor.1100020115>.

27. Goodship AE, Kenwright J. The influence of induced micromovement upon the healing of experimental tibial fractures. *J Bone Joint Surg Br.* 1985;67(4):650-5.
28. Claes L, Augat P, Suger G, Wilke HJ. Influence of size and stability of the osteotomy gap on the success of fracture healing. *J Orthop Res.* 1997;15(4):577-84, <http://dx.doi.org/10.1002/jor.1100150414>.
29. Duda GN, Sollmann M, Sporrer S, Hoffmann JE, Kassi JP, Khodadadyan C, et al. Interfragmentary motion in tibial osteotomies stabilized with ring fixators. *Clinical orthopaedics and related research.* 2002(396):163-72.
30. Hayda RA, Brighton CT, Esterhai JL Jr. Pathophysiology of delayed healing. *Clin Orthop.* 1998;355(Suppl):s124-s131.
31. Nazrun AS, Norazlina M, Norliza M, Ima Nirwana S. Comparison of the effects of tocopherol and tocotrienol on osteoporosis in animal models. *International Journal of Pharmacology.* 2010;6(5):561-8.
32. Maniam S, Mohamed N, Shuid A.N, Soelaiman I.N. Palm tocotrienol exerted better antioxidant activities in bone than α -tocopherol. *Basic Clin. Pharmacol. Toxicol.* 2008;103(1):55-60, <http://dx.doi.org/10.1111/j.1742-7843.2008.00241.x>.
33. Smith BJ, Lucas EA, Turner RT, Evans GL, Lerner MR, Brackett DJ, et al. Vitamin E provides protection for bone in mature hindlimb unloaded male rats. *Calcif Tissue Int.* 2005;76(4):222-79.
34. Arjmandi BH, Akhter MP, Chakkalakal D, Khalil DA, Lucas EA, Juma S, et al. Effects of isoflavones, vitamin E, and their combination on bone in an aged rat model of osteopenia. *J Bone Min Res.* 2001;16:S533.
35. Arjmandi BH, Juma S, Beharka AA, Bapna MS, Akhter M, Meydani SN. Vitamin E improves bone quality in the aged but not in young adult male mice. *J Nutr Biochem.* 2002;13(9):543-9, [http://dx.doi.org/10.1016/S0955-2863\(02\)00199-7](http://dx.doi.org/10.1016/S0955-2863(02)00199-7).
36. Turk CY, Halici M, Guney A, Akgun H, Sahin V, Muhtaroglu S. Promotion of fracture healing by vitamin E in rats. *The Journal of International medical Research.* 2004;32(5):507-12.
37. Ima Nirwana S, Nurshazwani Y, Nazrun AS, Norliza M, Norazlina M. Subacute and subchronic toxicity studies of palm vitamin E in mice. *Journal of Pharmacology & Toxicology.* 2011;6(2):166-73.
38. Nordsletten L, Madsen J.E, Almaas R, Rootwelt T, Italse J, Kontinen Y.T, et al. The neural regulation of fracture healing: effects of sciatic nerve resection in rat tibia. *Acta Orthop. Scand.* 1994;65(3):299-304.
39. Langeland N. Effects of oestradiol-17beta benzoate treatment on fracture healing and bone collagen synthesis in female rats. *Acta Endocrinol.* 1975;80(3):603-12.
40. Blythe JG, Buchsbaum HJ. Fracture healing in estrogen-treated and castrated rats. *Obstet. Gynecol.* 1976;48(3):351-2.