

# Antimicrobial photodynamic and photobiomodulation adjuvant therapies for medication-related osteonecrosis of the jaw – Report of two cases with long-term follow-up

• **Angela B. P. Paiva** Faculty of Dentistry, Universidade de São Paulo (USP), São Paulo, SP Brazil • **Beatriz C. Pereira** Faculty of Dentistry, Universidade de São Paulo (USP), São Paulo, SP Brazil • **Mariana A. Brozski** Oral Maxillofacial Surgeon • **Julia G. L. de Araújo** Universidade Federal do Maranhão (UFMA), São Luís, MA, Brazil • **Maria Cristina Zindel Deboni** Faculty of Dentistry, Universidade de São Paulo (USP), São Paulo, SP Brazil

**ABSTRACT** | Medication-related osteonecrosis of the jaw (MRONJ) is a relatively rare condition with high morbidity. In this study, we report the management of two recalcitrant cases of MRONJ in the mandibles of two older women who received treatment with alendronate for osteoporosis. Sequestrectomies, combined with antimicrobial photodynamic therapy (aPDT) and photobiomodulation (PBMT), were performed in both patients. During perioperative and weekly postoperative aPDT sessions, a diode laser treated three anatomical points by emitting a continuous gallium-aluminum-arsenide wave at 660 nm (red laser), 0.028 cm<sup>2</sup>, 0.1 W, 3.57 W/cm<sup>2</sup> for 90 s per point, 9 J per point, 321 J/cm<sup>2</sup>, and a total energy of 27 J. PBMT was applied weekly after surgery at 808 nm wavelength (other parameters being equal) for wound healing and pain relief. Both patients were followed-up for two years without any report of recurrence. Thus, aPDT and PBMT can be considered non-invasive adjuvant therapies for MRONJ without any adverse effects.

**DESCRIPTORS** | Osteonecrosis; Photobiomodulation; Photodynamic Therapy.

**RESUMO** | **Terapias adjuvantes fotodinâmicas e fotobiomoduladoras antimicrobianas para osteonecrose maxilar relacionada a medicamentos – Relato de dois casos com acompanhamento de longo prazo** • A osteonecrose maxilar associada a medicamentos (OMAM) é uma doença relativamente rara com alta morbidade. Nesse estudo, relatamos o tratamento de dois casos recalcitrantes de OMAM nas mandíbulas de duas idosas cujo tratamento para osteoporose foi feito com alendronato. Ambas as pacientes receberam sequestrectomia combinada com terapia fotodinâmica antimicrobiana (TFA) e fotobiomodulação (FBM). Durante o perioperatório e em atendimentos semanais pós-operatórios TFA tratou três pontos anatômicos através de um laser de diodo emitindo uma onda contínua de arseneto de gálio-alumínio a 660 nm (laser vermelho), 0,028 cm<sup>2</sup>, 0,1 W, 3,57 W/cm<sup>2</sup> por 90 s por ponto, 9 J por ponto, 321 J/cm<sup>2</sup> e uma energia total de 27 J. O tratamento com FBM foi aplicado em sessões pós-operatórias semanais, consistindo em ondas com 808 nm de comprimento e os demais parâmetros idênticos. Ambas as pacientes foram acompanhadas por dois anos e não relataram a recorrência de OMAM. Logo, TFA e FBM podem ser consideradas terapias adjuvantes não-invasivas para OMAM sem efeitos adversos.

**DESCRITORES** | Osteonecrose; Fotobiomodulação; Terapia Fotodinâmica.

**CORRESPONDING AUTHOR** | **Maria Cristina Zindel Deboni** Faculty of Dentistry, Universidade de São Paulo  
• Avenida Professor Lineu Prestes, 2227 Butantã, São Paulo, SP, Brasil  
• 05508-000 E-mail: mczdebon@usp.br

• Received 27 01, 2022 • Accepted 02 02, 2022

• DOI <http://dx.doi.org/10.11606/issn.2357-8041.clrd.2019.194433>

## INTRODUCTION

Osteonecrosis of the jaw associated with the use of medications is a relatively rare condition. It was first described in 2003 by Marx.<sup>1</sup> This condition is currently called medication-related osteonecrosis of the jaw (MRONJ). The lesion may or may not present bone exposure in the maxillomandibular region, persisting for more than eight weeks in patients who are receiving or have received antiresorptive drugs and are yet to undergo radiotherapy. It may be characterized by an intraoral or extraoral fistula, pathological fractures, and large areas of bone exposure. Since its emergence, many diagnostic and treatment criteria have been suggested.<sup>2</sup>

Current treatment strategies aim to eliminate pain, infection, and progression of the lesion, and they may differ depending on the clinical stage of the condition. Initial management is usually more conservative, with hygiene guidance and elimination of local factors and deleterious habits. In the advanced stages of the disease, treatment becomes less conservative, and patients may have to undergo surgical debridement and local resection.<sup>2,3</sup>

Antimicrobial photodynamic therapy (aPDT) has been presented as a viable and safe practice. Experimental studies have elicited good results in the treatment and prevention of MRONJ lesions.<sup>4</sup> The aPDT protocol comprises red laser irradiation preceded by the application of a photosensitizer agent.<sup>4,5</sup> The interaction between light and stained exogenous photoreceptors produces reactive oxygen species that are highly toxic to bacteria without inducing bacterial resistance. Photobiomodulation (PBMT) employs a low-power laser in the infrared wavelength. It exerts a deeper action on tissues and has been widely used, as it has improved tissue repair processes, modulation of inflammatory processes, and angiogenesis.<sup>4,5</sup>

Although the literature has described many treatment protocols,<sup>5-7</sup> there is still no evidence that one treatment may be better than the other. In this

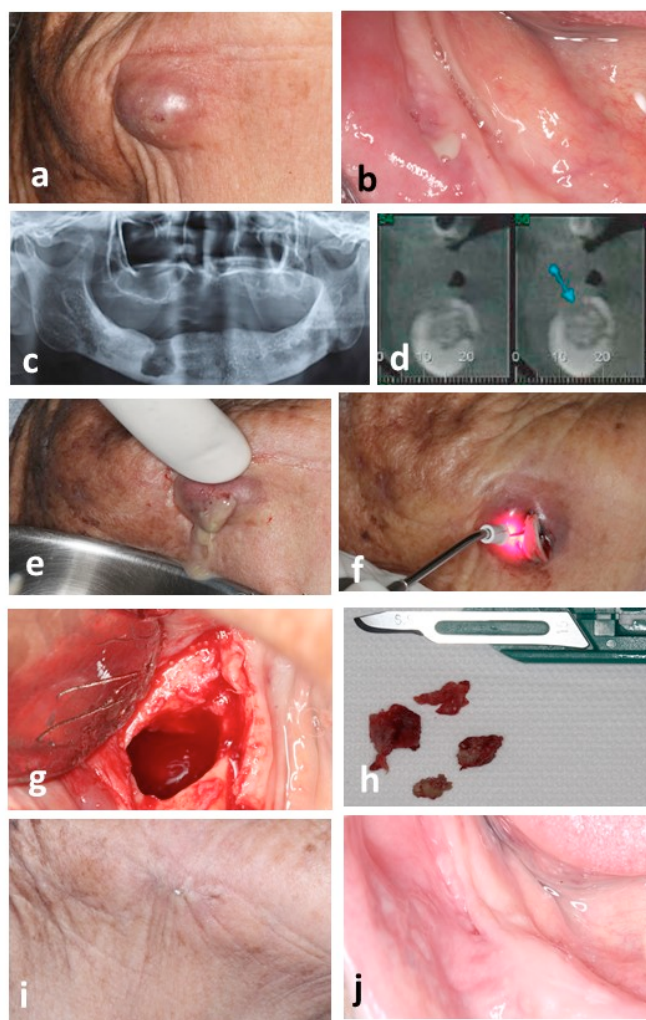
study, we describe two recalcitrant cases in which aPDT and PBMT were applied in the management of osteonecrotic lesions and the control of their symptomatology, with a two-year follow-up.

## CASE 1

A 77-year-old Asian woman visited our oral surgery clinic in March 2013 complaining of a wound, bitter taste in her mouth, and a swelling under her chin. She had a history of hypertension, osteoporosis, and labyrinthitis. She was a former smoker, and she reported using 25 mg of cinnarizine and 25 mg of hydrochlorothiazide daily, and 70 mg of alendronate once a week for osteoporosis for over 10 years. Clinical examination showed an extraoral abscess in the right submandibular region with a morular appearance and several spontaneous fistulas and floating points (Figure 1a). Intraoral examination of the inferior right alveolar edge (43 and 44 teeth region) revealed a fistula with productive purulent secretion (Figure 1b). A plain radiograph showed an extensive radiolucent area in her right jaw (Figure 1c), whereas tomographic sections showed a hyperdense lesion with a surrounding hypodense area, characteristic of bone sequestration (Figure 1d). Urgent extraoral drainage of the abscess (Figure 1e) was performed, followed by aPDT with the following parameters: 660 nm, 0.028 cm<sup>2</sup>, 0.1 W, 3.57 W/cm<sup>2</sup> for 90 s, 9 J per point, and 321 J/cm<sup>2</sup>, applied to at least three points surrounding the wound five minutes after the application of the photosensitized agent methylene blue 0.01% (Figure 1e). Clindamycin 600 mg was administered every eight hours for seven days. Weekly aPDT sessions, following the same procedure, were applied to three points, one central and two equidistant, in the vestibular and lingual intraoral fistulas to reduce infection. After 30 days, the intraoral lesion was debrided, and the necrotic bone, removed (Figures 1g-1h). Perioperative aPDT was applied to the bone defect with 27 J of total energy, and an extraoral fistulectomy was performed.

Further aPDT sessions, complemented with weekly postoperative PBMT using infrared laser with the following parameters: 808 nm 0.028 cm<sup>2</sup>, 0.1 W, 3.57 W/cm<sup>2</sup> for 30 s, 107 J/cm<sup>2</sup>, and 12 J total

energy, were performed until complete healing was achieved. The patient was followed-up every six months and no recurrences were reported after two years (Figures 1i and j).



**FIGURE 1** | (a) Extraoral abscess in the submandibular region; (b) Intraoral fistula with active secretion; (c) Panoramic radiograph showing extensive radiolucent area; (d) Representative tomographic sections showing a hyperdense lesion with surrounding hypodense areas indicating bone sequestration; (e) Extraoral drainage of the abscess; (f) Application of aPDT (red laser) in the extraoral wound after abscess debridement and 0.01% methylene blue photosensitizing action; (g) Bone condition after debridement of (h) the necrotic bone; (i) Extraoral and (j) intraoral aspects showing no recurrences after two years.

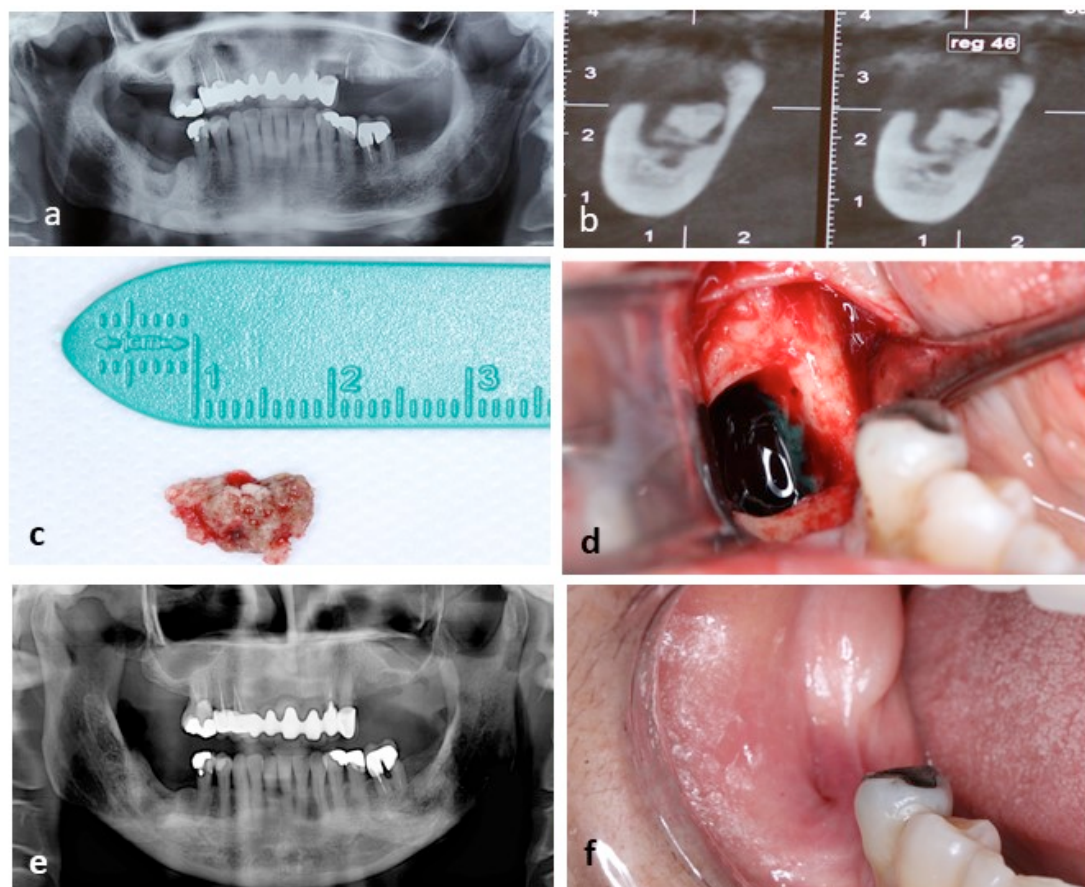
## CASE 2

A 67-year-old Asian woman visited our oral surgery clinic in September 2017 complaining of pain in her lower right jaw, a region in which she had a tooth extracted six months before. Extraoral examination showed slight swelling in the right mandibular

region and inflammatory lymph adenomegaly. Intraorally, a lingual fistula was observed in the 46th and 47th teeth region. The patient reported that she was prescribed 500 mg amoxicillin every eight hours for over a month at the previous clinic she visited, but her symptoms had not improved.

She showed hypertension, hypercholesterolemia, and hypothyroidism in her medical history. She was taking 50 mg losartan potassium every 12 h, 5 mg amlodipine every 12 h, and 100 mg levothyroxine sodium once a day. Furthermore, she took 100 mg nimesulide for acute arthrosis pain and 70 mg alendronate sodium weekly for approximately 15 years for her osteoporosis treatment. She stated that her dentist had suspended alendronate about a month prior because of her oral lesion. Panoramic radiograph showed a radiolucent area and a radiopaque mass in her right mandible (Figure 2a). Tomographic sections elicited bone sequestration (Figure 2b). She was prescribed 500 mg amoxicillin for seven days

combined with weekly aPDT sessions (following the previously described protocol) after 0.01% methylene blue photosensitization of the intraoral fistula for five minutes. APDT was repeated until the purulent secretion decreased. After four weeks, the surgical necrotic bone tissue was removed (Figure 2c), and the bone defect, photosensitized (Figure 2d) before trans-operative aPDT irradiation. Additional weekly aPDT sessions, along with PBMT, were performed until total healing was achieved. After two months, the patient returned with a completely recovered mucosa without any sign of infection (Figures 2e and f). The patient was followed-up every six months, and there were no complaints or recurrences after two years.



**FIGURE 2** | (a) Panoramic radiography showing the radiolucent area and radiopaque mass in the right jaw; (b) Tomographic section showing a hyperdense lesion with the surrounding hypodense area indicative of bone sequestration; (c) Necrotic bone tissue; (d) Application of the photosensitization agent during trans-operative surgery before laser irradiation; (e) Six-month postoperative panoramic radiograph shows absence of recurrence; (f) Intraoral mucosa shows excellent tissue covering and repair.



## DISCUSSION

Bisphosphonates are the most used antiresorptive drugs to preserve bone integrity and structure in osteoporosis, Paget disease, multiple myeloma, and bone metastasis in malignant tumors. Bisphosphonates show selectivity toward areas of bone resorption and act by inhibiting the action of osteoclasts.<sup>2,4,6</sup> Bisphosphonates containing nitrogen, such as pamidronate, zoledronic acid, alendronate, risedronate, and ibandronate, are poorly metabolized by the body, considering their accumulation capacity in bones. It is known that the drug and its time of administration, route, and dose are important factors that can modify the amount of substance accumulated in the bone, which can be found for more than 10 years after the end of administration.<sup>6,7</sup>

Other risk factors associated with MRONJ onset, besides drug-related factors, include history of inflammatory disease, bone density, systemic factors such as age, comorbidities such as diabetes and hypothyroidism, corticosteroid use, and habits such as smoking.<sup>2,5</sup> In the cases presented here, one of the patients was a smoker and the other had hypothyroidism.

For the proper treatment of this disease, it is particularly important to check the stage of MRONJ. According to the American Association of Oral and Maxillofacial Surgery,<sup>3</sup> the first patient had stage 3 MRONJ with pain related to extensive osteolysis in the jaw and infection with intraoral and extraoral fistulas. The second patient was between stages 1 and 2. Although there was no exposed necrotic bone in the mouth in either case, there was an intraoral fistula showing purulent drainage with associated pain. In both cases, the radiographic and tomographic images were consistent with the symptoms presented and the history of the disease. Although one patient reported a history of previous dental extraction that could justify local trauma and the development of MRONJ, there are other

reports of spontaneous development, especially in the posterior inferior mandibular region, in which greater friction may occur, as seen in the second case.<sup>2,5</sup>

There are several effective treatments for osteonecrosis. The literature proposes surgical debridement, which may involve local removal of necrotic bone, more extensive bone resection in larger lesions, as well as tooth or implant extractions that may be present in the necrotic bone.<sup>6-10</sup> In early-stage lesions, therapies are preferably non-surgical and involve oral antiseptics, local or systemic antibiotics, and antifungals. Other adjuvant treatments have also shown great results, such as ozone therapy and low-power laser therapy/PBMT, which help in pain relief and have anti-inflammatory and antimicrobial actions.<sup>4,5</sup>

An aPDT protocol with good therapeutic and preventive effects against MRONJ has been previously demonstrated.<sup>5</sup> We applied a photosensitive solution (0.01% methylene blue) to the tissues for five minutes, followed by continuous irradiation with a red laser gallium-aluminum-arsenide diode (660 nm and at least 9 J per point at three points).<sup>5</sup> In this protocol, we performed 4-5 weekly sessions in the areas of exposed bone before surgical treatment, until the inflammation and local infection had reduced. This process aims to generate reactive oxygen species, which can irreversibly damage bacterial membranes and cause bacterial death. Methylene blue, as a photosensitizer, potentiates cytotoxic effects on bacteria, as it allows specific binding and penetration into the bacterial membrane, and, therefore, shows an antimicrobial effect during the modulation of tissue repair. Some studies have emphasized the infectious role of MRONJ and, mainly, the presence of *Actinomyces israelii*.<sup>8</sup> APDT protocols locally reduce the bacterial component of the wound, which an antibiotic can hardly do in the lesion biofilm. During the surgical procedure, aPDT is performed immediately after removal of the necrotic bone inside the bone defect,

and additional applications are performed weekly until the full repair of the wound.<sup>5</sup>

It is noteworthy that this therapy has many benefits, including no bacterial resistance, no side effects in patients, and symptomatology relief already in the first session.<sup>5</sup> The benefits of PBMT can be attributed to the ability of an infrared laser to stimulate keratinocyte activity and angiogenesis, leading to substantial tissue repair and healing.<sup>4</sup> Laser light causes increased cellular energy by inducing cytochrome C oxidase, an important enzyme in the cellular respiratory chain. Thus, the conditions for local tissue repair are radically improved. Combination treatment, using the two phototherapies in biosafe conditions,<sup>10</sup> can help create better conditions for tissue repair, since aPDT decreases bacterial colonization and PBMT stimulates angiogenesis. It is especially important, besides treatment if possible, to reduce the risk of developing the disease by preventive methods.<sup>4,5</sup> This is seen with a multidisciplinary approach in disease treatment, which involves preventive dental treatment before the onset of antiresorptive or anti-angiogenic medications.

## FINAL CONSIDERATIONS

APDT and PBMT can be useful adjuvant therapies in managing lesions, performing less contaminated surgeries, and providing stimuli for more efficient tissue repair.

## DECLARATIONS

Conflict of interest: None.

Funding: Students Scholarships: Julia Lucio Master's degree from Coordination of Advanced Personnel (CAPES); Beatriz Campos Pereira Researcher Trainee Scholarships from grant #2020/05149-6 from the São Paulo Research Foundation (FAPESP). Angela Beatriz Pereira scholarship from the Unified Program of Scholarship

PRG-USP. We would like to thank Editage (www.editage.com) for their English editing services.

## REFERENCES

1. Marx RE. Pamidronate (Aredia) and zoledronate (Zometa) induced avascular necrosis of the jaws: a growing epidemic. *J Oral Maxillofac Surg.* 2003;61(9):1115-17. Doi: [http://doi.org/10.1016/S0278-2391\(03\)00720-1](http://doi.org/10.1016/S0278-2391(03)00720-1).
2. Ruggiero SL, Mehrotra B, Rosenberg TJ, Engroff SL. Osteonecrosis of the jaws associated with the use of bisphosphonates: a review of 63 cases. *J Oral Maxillofac Surg.* 2004;62:527-34. Doi: <http://doi.org/10.1016/j.joms.2004.02.004>.
3. Ruggiero SL, Dodson TB, Fantasia J, Goodday R, Aghaloo T, Mehrotra B, et al. American Association of Oral and Maxillofacial Surgeons position paper on medication-related osteonecrosis of the jaw – 2014 update. *J Oral Maxillofac Surg.* 2014;72(10):1938-56. Doi: <https://doi.org/10.1016/j.joms.2014.04.031>.
4. Statkiewicz C, Toro LF, Mello-Neto JM, Sá DP, Casatti CA, Issa JPM, et al. Photomodulation multiple sessions as a promising preventive therapy for medication-related osteonecrosis of the jaws after tooth extraction in rats. *J Photochem Photobiol B.* 2018;184:7-17. Doi: <https://doi.org/10.1016/j.jphotobiol.2018.05.004>.
5. Tartaroti NC, Marques MM, Naclério-Homem MG, Migliorati CA, Deboni MCZ. Antimicrobial photodynamic and photobiomodulation adjuvant therapies for prevention and treatment of medication-related osteonecrosis of the jaws: case series and long-term follow-up. *Photodiagnosis Photodyn Ther.* 2020;29:101651. Doi: <https://doi.org/10.1016/j.pdpdt.2020.101651>.
6. Beth-Tasdogan NH, Mayer B, Hussein H, Zolk O. Interventions for managing medication-related osteonecrosis of the jaw. *Cochrane Database Syst Rev.* 2017;10:CD012432. Doi: <https://doi.org/10.1002/14651858.CD012432.pub2>.
7. Brozoski MA, Traina AA, Deboni MCZ, Marques MM, Naclério-Homem MG. Bisphosphonate-related osteonecrosis of the jaw. *Rev Bras Reumatol.* 2012;52(2):265-70. Doi: <https://doi.org/10.1590/S0482-50042012000200010>.
8. Cerrato A, Zanette G, Boccutto M, Angelini A, Valente M, Bacci C. Actinomyces and MRONJ: A retrospective study and a literature review. *J Stomatol Oral Maxillofac Surg.* 2021;122(5):499-504. Doi: <https://doi.org/10.1016/j.jor- mas.2020.07.012>.

9. Brozowski MA, Lemos CA, Naclério-Homem MG, Deboni MCZ. Adjuvant aqueous ozone in the treatment of bisphosphonate induced necrosis of the jaws: report of two cases and long-term follow-up. *Minerva Stomatol.* 2014;63(1-2):35-41.
10. Rodrigues FCN, Araújo JGL, Araújo EMS, Lago ADN, Mantilla TF, Freitas PM. Influence of biosafety materials of the laser output power. *Lasers Med Sci.* 2021;26(2):311-5. Doi: <https://doi.org/10.1007/s10103-020-03030-1>.