

## The effects of ionizing radiation on the development of human caries lesions *in vitro*

• **Deborah Pereira Lee** Undergraduate Student, School of Dentistry, University of São Paulo, São Paulo, SP, Brazil • **Luciana Cardoso Espejo-Trung** Department of Operative Dentistry, School of Dentistry, University of São Paulo, São Paulo, SP, Brazil • **Maria Regina Lorenzetti Simionato** Department of Microbiology, Institute of Biomedical Sciences, University of São Paulo, São Paulo, SP, Brazil • **Fabio de Abreu Alves** Department of Stomatology, School of Dentistry, University of São Paulo, São Paulo, SP, Brazil • **Moacyr Domingos Novelli** Department of Stomatology, School of Dentistry, University of São Paulo, São Paulo, SP, Brazil • **Maria Aparecida Alves de Cerqueira Luz** Department of Operative Dentistry, School of Dentistry, University of São Paulo, São Paulo, SP, Brazil

**ABSTRACT** | Radiotherapy is associated with several undesired side effects, such as rampant radiation caries. The aim of this study was to evaluate the effect of ionizing radiation on the development of carious lesions using a bacterial system *in vitro*. Fifteen sound human molars were selected and sectioned into buccal (A, control) and lingual (B, irradiated) dental fragments, which were considered dependent. Group B was submitted to radiotherapy according to the protocol for head and neck oncological treatment. The two groups were exposed to a cariogenic challenge using a bacterial system with *S. mutans* for 10, 20 and 30 days (n = 5). The variables depth, extension and area for lesions formed at the enamel-dentin junction were measured by software coupled with light microscopy. Optical coherence tomography (OCT) was used to visualize the morphological characteristics of the lesions. Only the 20-day period of culture immersion for caries development resulted in significantly better lesion comparisons, by light microscopy. Of the three lesion dimensions analyzed, lesion depth (LD) differed statistically between groups A and B ( $p = 0.013$ ). Analysis using OCT allowed the visualization of carious lesions without showing the carious layers. Within the limitations of this study, we can conclude that radiation treatment of sound teeth before a cariogenic challenge *in vitro* causes deeper carious lesions than in those teeth not subjected to radiation treatment.

**DESCRIPTORS** | Dental Caries; Head and Neck Neoplasms; Radiotherapy; *Streptococcus mutans*.

**RESUMO** | **Efeito da radiação ionizante no desenvolvimento de lesões de cárie em dentes humanos *in vitro*** • A radioterapia é associada a diversos efeitos colaterais, entre eles a cárie de radiação. O objetivo desse estudo foi avaliar o efeito da radiação ionizante no desenvolvimento de lesões cáries utilizando um sistema bacteriano *in vitro*. Foram selecionados quinze terceiros molares humanos inclusos que foram seccionados em fragmentos vestibular (A, controle) e lingual (B, irradiado), e foram mantidos pareados até o término do estudo. O grupo B foi submetido à radioterapia de acordo com protocolo utilizado no tratamento radioterápico de cabeça e pescoço. Ambos os grupos foram expostos a um desafio cariogênico utilizando um sistema bacteriano com *S. mutans* por 10, 20 e 30 dias (n = 5). As variáveis de profundidade, extensão e área das lesões formadas no limite amelo-dentinário foram medidas por um software acoplado ao microscópio de luz. A Tomografia de coerência óptica (TCO) foi utilizada para visualizar as características morfológicas das lesões. Os resultados da microscopia de luz mostraram que, no período de 20 dias de desafio bacteriano, ocorreu um resultado significante, comparando a profundidade das lesões formadas entre os grupos A e B ( $p = 0.013$ ). A análise de TCO não permitiu visualizar as camadas de cárie das lesões. Podemos concluir, dentro das limitações do estudo, que o tratamento radioterápico pode levar à formação de lesões de cárie mais profundas do que aquelas que se desenvolvem em dentes sem exposição à radiação ionizante.

**DESCRITORES** | Cárie Dentária; Neoplasias de Cabeça e Pescoço; Radioterapia; *Streptococcus mutans*.

**CORRESPONDING AUTHOR**

• **Maria Aparecida Alves de Cerqueira Luz** Department of Operative Dentistry, School of Dentistry, University of São Paulo. • **Av. Prof. Lineu Prestes, 2227** São Paulo, SP, Brazil • **05508-000** E-mail: maacruz@usp.br

• **Received** Jan 07, 2013 • **Accepted** Jun 24, 2013

## INTRODUCTION

Cancer is one of the major health problems in the world. In Brazil, the National Cancer Institute estimates that there were 14,170 new cases in 2012, with 9,990 men and 4,180 women being diagnosed. In 2009, 6,510 deaths occurred due to oral cancer.<sup>1</sup>

Radiotherapy is often used in palliative or curative treatment of malignancies, since this method is capable of destroying tumor cells using ionizing radiation beams. The total radiation dose to be used is usually split into equal daily doses in order to guarantee tissue tolerance; this way, the biological effect reaches the largest number of neoplastic cells.

Many patients with head and neck cancer are exposed to high doses of radiotherapy in extensive fields of radiation that include the oral cavity, maxilla, mandible and salivary glands. Radiotherapy preserves the tissue structure but causes adverse reactions that appear in the oral cavity.<sup>2,3</sup> The severity of these reactions depends on the volume and radiation location, total dose, fractionation, age, clinical conditions of the patient and associated treatments. These reactions can occur in the acute phase (during or within the first weeks of treatment) or in the chronic phase (months or years after the radiotherapy), and include the following conditions:

- mucositis,
- candidiasis,
- taste alteration,
- osteoradionecrosis,
- soft tissue necrosis,
- dry mouth and
- radiation caries.<sup>4,5,6,2,7</sup>

Rampant caries from radiation is a common and important complication<sup>4,3</sup> of treatment and usually develops at the cervical level of the tooth, starting at the labial surface and moving sequentially to the lingual surface in a chronic process. The change usually occurs without painful symp-

toms because of loss of pulpal sensitivity. These lesions are observed in anterior and posterior teeth, which may develop four weeks after completion of radiotherapy or 3–6 months after the beginning of treatment.<sup>4,8,9</sup> The multifactorial disease termed radiation caries is not well-defined by the literature,<sup>4,7</sup> nor by its histological features. Several authors suggest that radiation caries occurs due to pH changes caused by a decrease in oral salivary flow because of salivary gland damage from treatment of head and neck cancer.<sup>4,5,6,2,9,10</sup> Others, such as Poyton<sup>11</sup> and Anneroth *et al.*,<sup>12</sup> suggest that these lesions are caused by changes in the crystalline structure of hard tissues as a consequence of direct radiation to the teeth. Franzel and Gerlach<sup>13</sup> concluded that enamel and dentin are strongly affected by high and low energy irradiation, and, consequently, that the mechanical properties of the enamel are damaged by cancer radiation treatment.

Considering the small number of studies about this topic and the disagreement in the literature about the role of radiotherapy in radiation caries, the aim of this study was to evaluate the hypothesis that radiotherapy is able to increase the caries risk of human teeth subjected to a cariogenic challenge, using a bacterial method *in vitro*.

## OBJECTIVE

The aim of this study was to evaluate, *in vitro*, the effect of ionizing radiation on the development of carious lesions using a bacterial system.

## MATERIALS AND METHODS

Fifteen extracted, non-erupted human third molars without previous lesions or visible enamel defects were stored in distilled water at 4°C. Approval by the Ethics Committee, School of Dentistry, University of São Paulo was obtained. After the apical 2/3 of the roots had been removed, the teeth were sectioned with double-faced diamond discs (Discoflex, KG Sorensen, Cotia, SP, Brazil) into two

fragments:

- buccal (A, control) and
- lingual (B, irradiated).

Group B was submitted to radiotherapy according to the protocol for head and neck oncological treatment. The dental fragments from groups A and B were paired, and all of them were cleaned with an aqueous slurry of pumice and anionic detergent.

The fragments from Group B were irradiated according to the following protocol: 2 Gy per day for 35 days, for a total of 70 Gy, by a linear accelerator device (2100C 6x; Clinac iX, Varian Medical Systems, Palo Alto, CA, USA). The sample was randomly divided into 3 groups (n = 5), with each one being subjected to a cariogenic challenge for a specific period of time:

- Group 1, 10 days;
- Group 2, 20 days;
- Group 3, 30 days.

During the cariogenic challenge there were specimen losses in Group 1 and Group 2. Consequently, an n = 4 was considered for all the groups, randomly ruling out one specimen of Group 3.

Steel wires were attached to each dental fragment, and the surfaces of the fragment were painted with acid-resistant nail varnish (Risque, Niasi Ind. de Cosméticos, Taboão da Serra, SP, Brazil), except on a 3 × 5 mm window at the enamel-dentin junction. The specimen/wire sets were sterilized with gamma irradiation (25 kGy), using a Gama-cel 220 device (Atomic Energy of Canada, Chalk River, Ontario, Canada), at the Institute of Energy and Nuclear Research. The development of carious lesions was induced *in vitro* with a bacterial system following the method used by Gama-Teixeira *et al.*<sup>14</sup> and Espejo *et al.*<sup>15</sup> The microorganism used was *S. mutans* ATCC 25.175. The specimens of the same group were immersed in a tube containing

300 mL of TSB with 5% sucrose and 3 mL of the inoculum broth, and were maintained in this bacterial system and transferred to a fresh tube every 24 h. During the incubation period, tests were performed to check for contaminants. After 10, 20 and 30 days, the groups were removed from each bacterial system and cleaned.

Optical coherence tomography (OCT; OCP-930SR, Thorlabs, Newton, New Jersey, USA) was used to visualize the morphological characteristics of the lesions.<sup>16,17,18</sup> In this study, OCT was used in order to detect alterations of the tissues optical properties and for qualitative analysis of the carious lesions at the enamel-dentin junction.

After OCT analysis, each specimen was embedded in epoxy resin (Arazym, Redlease, São Paulo, SP, Brazil) and sectioned in a buccolingual direction, resulting in sections with 300 µm thickness, exposing the enamel-dentin junction. Three of these sections were randomly chosen from the central area of the lesions and were ground by hand to a thickness of 80–120 µm using sandpaper for light microscopy analysis. Each section was examined under a light microscope (Citoval 2 with CarlZeiss lens, Laboral 4, Zeiss, USA) coupled with software (DIRACOM 3 Imagelab 2000, Bio Rad Canton, MA, USA) in order to take the following measurements (variables):

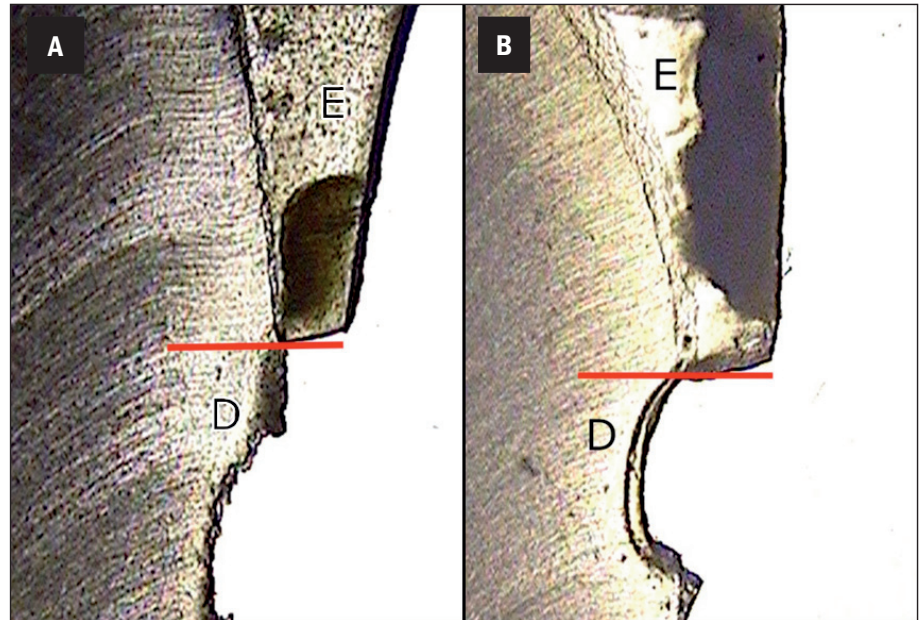
- lesion extension (LE), from the external lesion margin to the opposite margin at the enamel-dentin junction;
- lesion depth (LD), from the enamel-dentin junction to the deepest point of the lesion in dentin;
- lesion area (LA), calculated using the software's "calculated area" tool, based on the selected area of the lesion.

The data were subjected to statistical analysis using Student's t-test for pairwise comparisons of each period of cariogenic challenge ( $p < 0.05$ ).

**Figure 1** | OCT Images. Twenty days of cariogenic challenge. **A:** A thin, whitish stripe corresponding to less scattered light representing less demineralized enamel can be seen on the non-irradiated specimen. **B:** A wide stripe corresponding to more scattered light representing more demineralized enamel can be seen on the irradiated specimen.



**Figure 2** | Light microscopy analysis (60×). **A:** Non-irradiated specimen; **B:** Irradiated specimen. The red line indicates the region and direction of depth measurement; E = enamel; D = dentin.



## RESULTS

The images taken with OCT are based on the optical properties of the sample and they are made using false color mapping, where the white color corresponds to a high spreading coefficient equivalent to demineralized areas and the black color corresponds to a low spreading coefficient. In this study, the image taken with OCT allowed observation of the demineralization depth of the area exposed to the cariogenic challenge on enamel and/or dentin and of the enamel-dentin junction (Figure 1A), corresponding to the transverse area delineated by a homogeneous whitish stripe that runs continuously on the healthy enamel. The healthy dentin exhibited a similar whitish stripe that was less homogeneous than that of the enamel, but had a clearer surface boundary. Enamel and dentin displayed distinct spreading characteristics in the OCT images. The tissue struc-

ture of the enamel and dentin was clearly visible in the OCT images. The enamel displayed a homogeneous whitish stripe that runs continuously on the healthy enamel. The healthy dentin exhibited a similar whitish stripe that was less homogeneous than that of the enamel, but had a clearer surface boundary. Enamel and dentin displayed distinct spreading characteristics in the OCT images. The tissue struc-

**Table 1** | Descriptive analysis of the data and comparison between groups (n = 4) considering the factors analysed.

Treatment		Control		Irradiated	
		Mean	SD	Mean	SD
Depth (µm)	10 days	1.08 <sup>a</sup>	0.07	1.58 <sup>a</sup>	0.37
	20 days	1.66 <sup>b</sup>	0.75	2.26 <sup>c</sup>	0.81
	30 days	1.68 <sup>a</sup>	0.35	2.16 <sup>a</sup>	0.22
	Total	1.48	0.52	2.00	0.57
Extension (µm)	10 days	11.49 <sup>d</sup>	3.84	9.78 <sup>d</sup>	3.57
	20 days	15.91 <sup>d</sup>	4.29	11.38 <sup>d</sup>	2.07
	30 days	18.40 <sup>d</sup>	2.94	15.99 <sup>d</sup>	3.45
	Total	15.27	4.51	12.38	3.93
Area (µm <sup>2</sup> )	10 days	14.61 <sup>e</sup>	2.94	18.12 <sup>e</sup>	7.36
	20 days	26.11 <sup>e</sup>	12.30	27.23 <sup>e</sup>	9.33
	30 days	35.85 <sup>e</sup>	15.31	41.17 <sup>e</sup>	8.48
	Total	25.52	13.78	28.84	12.49

Different letters in the same row indicate statistically significant differences analyzed using the paired t test for each factor ( $\alpha < 0.05$ ).

tures with carious lesions showed a whitish stripe deeper than did the healthy teeth (Figure 1B).

Through the light microscopy analysis (Figure 2A and 2B), it was possible to make comparisons between the carious lesions of both groups studied, irradiated and non-irradiated teeth. The data are presented in Table 1. The comparison between the periods of time of cariogenic challenge showed that only after 20 days of the bacterial cariogenic challenge was there a significant difference between the lesions formed in both groups studied. Comparing the depth of the lesions of the irradiated and non-irradiated teeth after 20 days of cariogenic challenge, the control group ( $1.66 \pm 0.75$ ) showed a smaller lesion depth than the irradiated group ( $2.26 \pm 0.81$ ) with  $p = 0.013$ . Comparing the extension and the area of the lesions, it was not possible to find statistically significant differences with  $p = 0.22$  and  $p = 0.87$ , respectively, for each of the cited variables.

## DISCUSSION

This study did not consider the saliva factor variable because several researchers<sup>6,9,19,3</sup> have already

affirmed that radiotherapy indirectly causes caries by compromising the salivary glands tissue, causing hyposalivation, but without directly damaging the dental tissue. Conversely, several authors<sup>12,11</sup> affirm that these lesions occur owing to modifications of the crystalline structure of hard tissues as a consequence of the direct action of radiation to the teeth. Others<sup>5</sup> claim that both hyposalivation and direct radiation make the teeth more susceptible to decalcification and affect the development of radiation caries. We agree with Springer *et al.*<sup>7</sup> and Aguiar *et al.*<sup>4</sup> that both generic caries and radiation caries should be treated as a multifactorial disease, i. e., in addition to the changes in the dental tissues, the salivation decrease might also favor lesion development, in addition to other modifying factors, such as food diet, social conditions, education, and others.<sup>2</sup>

In this *in vitro* study, a comparison of the size of the carious lesions in the control group and in the irradiated group was made. After subjecting both tooth groups to the same bacterial cariogenic challenge, the irradiated tooth lesions were found to be deeper than those on non-irradiated teeth. However, the literature does not contain conclusive consider-

ations regarding the effect of radiation alone on dental tissues, except for histological changes demonstrated by chromatography analysis on pulp tissue according to Springer *et al.*<sup>7</sup> These findings may offer an additional explanation for the great incidence of carious lesions in irradiated patients, mainly in the cervical region of the teeth at the enamel-dentin junction, since pain sensitivity may be modified due to histological changes of pulp tissue.

The irradiation protocol adopted in this study was calculated by a physicist operating the equipment in such a way that all teeth received the same radiation dose. The dental fragments received 2 Gy of radiation per day, and, over 35 days, the fragments received a total of 70 Gy, which represents the maximum radiation that a patient receives during radiotherapy treatment of the head and neck.

Because OCT images did not have good contour definition, it was impossible to estimate their dimensions clearly; therefore, we could merely affirm or deny the presence of caries by using this mode of lesion analysis. Comparing the periods of time of the bacterial cariogenic challenge—10, 20 and 30 days—using light microscopy associated with a measurement of the lesions, we observed differences in carious lesions only after the intermediate period of time (20 days). It was observed that the lesions that developed over 10 days of cariogenic challenge were too small, and the lesions that developed over 30 days were too large, for comparisons. This usually occurs using the bacterial challenge, since the bacterial strains may have different pathogenicity, and the teeth may have different susceptibility. These were the reasons why we used different periods of challenge in this study. After 20 days of cariogenic challenge, it was possible to observe differences among the depths of the lesions, which were deeper in irradiated teeth than in non-irradiated ones. Therefore, the results after 20 days were used in the discussion.

The analysis method initially adopted using

optical coherence tomography (OCT) was not conclusive because it was difficult to observe the differences among the carious lesions, probably because the images of the lesions appeared somewhat tenuous and, for this reason, were not clear enough to make a comparison. Due to these difficulties of interpretation, common light microscopy analysis associated with the measurements of the carious lesions was added to this study in order to obtain quantitative data that enabled a more objective comparison.

We considered that this result pointed indirectly to a tissue alteration because the saliva factor and other modifying factors, such as socioeconomic and cultural factors, are not present in this case.<sup>2</sup> The result is in accordance with that of Springer *et al.*<sup>7</sup> that verified that a total dose of 31.5 Gy of radiation would be sufficient to damage the collagen fibers present in dentin, enamel and pulp tissues of human third molars using chromatographic analysis. The extension of the lesion was similar for all groups because it depends directly on the contact of the bacterial biofilm present on the exposed enamel and dentin area, which had the same dimensions in all specimens. Although the depth of the lesions was statistically higher in irradiated teeth than in non-irradiated teeth in the 20-day cariogenic challenge group, the area of the lesions did not differ significantly between the groups. This difference can be explained by the small sample size of each group and by the high standard deviation of the lesion extension measurements, since the calculation of area used extension versus depth. The depth measurements, in contrast, exhibited a low standard deviation; for this reason they showed a clear difference between non-irradiated and irradiated teeth. The tooth crown location chosen for development of the lesions was the region of the enamel-dentin junction because previous studies showed a great clinical incidence of carious lesions in this dental area in irradiated head and neck pa-

tients.<sup>9</sup> The collagen fibers, more present in dentin than in enamel, could have suffered alterations due to the radiation-enabled progression of the lesion in the direction of the pulp, since it has been shown that collagen fibers present in dental pulp<sup>19</sup> undergo histological modification after radiation treatment, which may change pain sensitivity and favor a higher incidence and larger development of caries lesions in patients. This interpretation leads indirectly to the conclusion that the ionizing radiation used for oncological head and neck treatment can induce tissue alterations in enamel and/or dentin that facilitate the development of dental caries; however, more studies are needed to analyze irradiated tissues.

## REFERENCES

1. Brazil. Ministry of Health. National Institute of Cancer José Alencar Gomes da Silva. Estimate/2012 - Cancer Incidence in Brazil [Internet]. Rio de Janeiro: Inca; 2011 [cited 2013 May 23]. Available from: URL:[http://www.saude.sp.gov.br/resources/ses/perfil/gestor/homepage/estimativas-de-incidencia-de-cancer-2012/estimativas\\_incidencia\\_cancer\\_2012.pdf](http://www.saude.sp.gov.br/resources/ses/perfil/gestor/homepage/estimativas-de-incidencia-de-cancer-2012/estimativas_incidencia_cancer_2012.pdf).
2. Moore S, Burke MC, Fenlon MR, Banerjee A. The role of the general dental practitioner in managing the oral care of head and neck oncology patients. *Dent Update*. 2012 Dec;39(10):694-6,698-700,702.
3. Thariat J, Ramus L, Darcourt V, Marcy PY, Guevara N, Odin G, et al. Compliance with fluoride custom trays in irradiated head and neck cancer patients. *Support Care Cancer*. 2012 Aug;20(8):1811-4.
4. Aguiar GP, Jham BC, Magalhães CS, Sensi LG, Freire AR. A review of the biological and clinical aspects of radiation caries. *J Contemp Dent Pract*. 2009 Jul 1;10(4):83-9.
5. Jham BC, da Silva Freire AR. Oral complications of radiotherapy in the head and neck. *Braz J Otorhinolaryngol*. 2006 Sep-Oct;72(5):704-8.
6. Meurman JH, Grönroos L. Oral and dental health care of oral cancer patients: hyposalivation, caries and infections. *Oral Oncol*. 2010 Jun;46(6):464-7.
7. Springer IN, Niehoff P, Warnke PH, Böcek G, Kovács G, Suhr M, et al. Radiation caries--radiogenic destruction of dental collagen. *Oral Oncol*. 2005 Aug;41(7):723-8.
8. Jham BC, Reis PM, Miranda EL, Lopes RC, Carvalho AL, Scheper MA, et al. Oral health status of 207 head and neck cancer patients before, during and after radiotherapy. *Clin Oral Investig*. 2008 Mar;12(1):19-24.
9. Silva AR, Alves FA, Antunes A, Goes MF, Lopes MA. Patterns of demineralization and dentin reactions in radiation-related caries. *Caries Res*. 2009;43(1):43-9.
10. Silva AR, Alves FA, Berger SB, Giannini M, Goes MF, Lopes MA. Radiation-related caries and early restoration failure in head and neck cancer patients. A polarized light microscopy and scanning electron microscopy study. *Support Care Cancer*. 2010 Jan;18(1):83-7.
11. Poyton HG. The effects of radiation on teeth. *Oral Surg Oral Med Oral Pathol*. 1968 Nov;26(5):639-46.
12. Anneroth G, Holm E, Karlsson G. The effect of radiation on teeth. A clinical, histologic and microradiographic study. *Int J Oral Surg*. 1985 Jun;14(3):269-74.
13. Fränzel W, Gerlach R. The irradiation action on human dental tissue by X-rays and electrons -- a nanoindenter study. *Z Med Phys*. 2009;19(1):5-10.
14. Gama-Teixeira A, Simionato MR, Elian SN, Sobral MA, Luz MA. Streptococcus mutans-induced secondary car-

## CONCLUSION

Within the limitations of this *in vitro* study, it can be concluded that radiation treatment of sound teeth may cause deeper carious lesions than in non-irradiated teeth subjected to the same cariogenic challenge.

## ACKNOWLEDGMENTS

The authors of this study are thankful to FUNDECTO; to Prof. Anderson Zanardi de Freitas from the Nuclear and Energy Research Institute (IPEN-CNEN/SP), São Paulo, SP, Brazil; and to the Technological Center for Radiation, A. C. Camargo Hospital.

- ies adjacent to glass ionomer cement, composite resin and amalgam restorations in vitro. *Braz Oral Res.* 2007 Oct-Dec;21(4):368-74.
15. Espejo LC, Simionato MR, Barroso LP, Netto NG, Luz MA. Evaluation of three different adhesive systems using a bacterial method to develop secondary caries in vitro. *Am J Dent.* 2010 Apr;23(2):93-7.
16. Azevedo CS, Trung LC, Simionato MR, Freitas AZ, Matos AB. Evaluation of caries-affected dentin with optical coherence tomography. *Braz Oral Res.* 2011 Sep-Oct;25(5):407-13.
17. Lee C, Darling CL, Fried D. Polarization-sensitive optical coherence tomographic imaging of artificial demineralization on exposed surfaces of tooth roots. *Dent Mater.* 2009 Jun;25(6):721-8.
18. Maia AM, Fonsêca DD, Kyotoku BB, Gomes AS. Characterization of enamel in primary teeth by optical coherence tomography for assessment of dental caries. *Int J Paediatr Dent.* 2010 Mar;20(2):158-64.
19. Specht L. Oral complications in the head and neck radiation patient. Introduction and scope of the problem. *Support Care Cancer.* 2002 Jan;10(1):36-9.