

EVALUATION OF PALATAL PROSTHESIS FOR THE TREATMENT OF VELOPHARYNGEAL DYSFUNCTION

AVALIAÇÃO DE PACIENTES PORTADORES DE DISFUNÇÃO VELOFARÍNGEA TRATADOS COM PRÓTESE DE PALATO

João Henrique Nogueira PINTO

DDS, Ph.D Prosthodontist, Department of Prosthodontics, Hospital of Rehabilitation for Craniofacial Anomalies, University of São Paulo and Professor, Department of Prosthodontics, Faculty of Dentistry, University of Sagrado Coração, Bauru, São Paulo, Brazil.

Maria Inês PEGORARO-KROOK

Ph.D Professor, Department of Communication Disorder Faculty of Dentistry, University of São Paulo, Bauru, São Paulo, Brazil.

Support in this study by CAPES, Brazil.

Some patients presenting velopharyngeal dysfunction need treatment with a palatal prosthesis, and few researches attempt to evaluate the judgement of its efficacy. For that reason, a questionnaire was submitted to 48 patients with a palatal prosthesis, with ages from 8 to 74 (mean 31.47), from which 42 had a congenital cleft, 2 exhibited an acquired cleft and 4 presented total or partial palsy of the soft palate. Results revealed that 81.2% of these patients were able to eat while using their prostheses; 85.4% stated their speech had improved with the prostheses; 75% considered the prosthesis stable during nourishment, and 91.7% during speech; 79.2% felt comfortable using the prosthesis; and 85.4% related a general improvement in life quality with the prosthetic treatment of velopharyngeal dysfunction. It was concluded that the prosthetic treatment of velopharyngeal dysfunction demonstrated efficacy in improving speech, despite of the heterogeneous sample. Besides, it offered the other basic requirements of a prosthesis whenever it was needed.

UNITERMS: Speech; Velopharyngeal insufficiency; Palatal obturators; Speech, physiology.

INTRODUCTION

The velopharynx is a tridimensional muscular valve located between the oral and nasal cavities, consisting basically of the lateral and posterior pharyngeal walls and the soft palate, and controls the passage of air. The velopharyngeal dysfunction may take place when this valve is unable to perform its own closing, due to a lack of tissue (velopharyngeal insufficiency) or even lack of proper movement (velopharyngeal incompetence). It can jeopardize the subject's communication, for his speech becomes completely atypical. The constant communication between the oral and nasal cavities jeopardizes the speech comprehension, as well as absent or weak intra-oral pressure, hypernasality, compensatory articulation, and nasal air emission.

The anxiety for not being understood, not being

able to express himself, restrains creativity and the ability to learn, possibly leading the subject to a psychosocial disturbance, even making him avoid social relationships, something that can be assigned to social impositions or the patient himself.

The velopharyngeal dysfunction may be treated through surgery, prosthesis, speech therapy, or a combination of them all, depending on the case. The palatal prosthesis may be the best option in several situations, e.g. when surgery is not indicated due to systemic, anatomical, functional, or social disturbances, or even when the subject is not willing to undergo surgery, since his opinion, despite not determining the proceeding, is extremely important.

With the evolution of concepts and the technique of construction, the treatment with a palatal prosthesis has become part of the current philosophy for the rehabilitation of velopharyngeal dysfunction patients.

It aims at providing them a socially acceptable speech, and through this speech, the overcoming of their deficiency and a good social relationship ^{1, 3, 6, 7, 8, 11}.

Based on these features, an attempt was made to evaluate the prosthetic treatment for velopharyngeal dysfunction, through the subjects' judgement, involving questions on mastication, stability, esthetics, comfort and life quality in general, provided by the palatal prosthesis.

MATERIAL AND METHODS

Our sample consisted of 48 velopharyngeal dysfunction patients, from whom 42 had a congenital cleft, 2 had an acquired cleft (patients with palatal cancer) and 4 exhibited palatal palsy. There were 23 (47.9%) male subjects and 25 (52.1%) female subjects, with ages ranging from 8 to 74 (mean 31.47 ± 16.03).

The palatal prosthesis can be didactically divided in 2 portions, anterior and posterior. The anterior portion corresponds to the conventional prosthesis, and it can be a removable partial prosthesis, a complete denture, an overdenture or even an acrylic plate. Its function is the same of any other conventional prosthesis, i.e., replace the missing teeth and absent structures, present to be biologically safe to the tissues, provide an acceptable esthetics and assure all the functions performed by the stomatognathic system. In some cases, the nasopharynx is so deep that some authors consider an intermediate portion between these two that properly places and retains the posterior portion.

This posterior portion intends to correct or at least reduce the effects of the velopharyngeal dysfunction. Basically, this portion can belong to three different kinds depending on the velopharyngeal dysfunction's etiology.

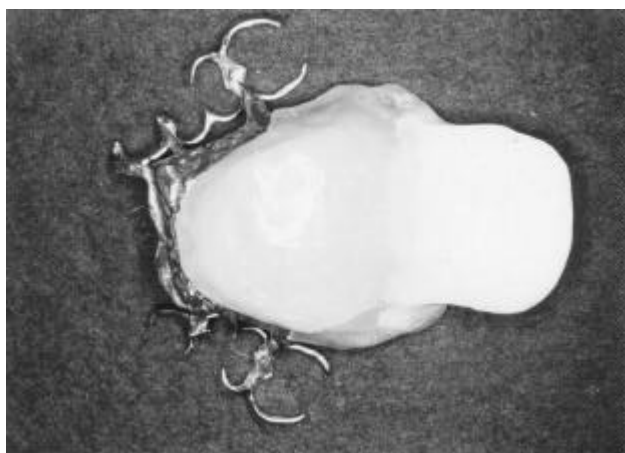

FIGURE 1B AND 1C- Obturator prosthesis with speech bulb

The patients presenting a palatal fistula and a normal velopharynx received a palatal obturator prosthesis. Patients with a short palate or open palate were treated through an obturator prosthesis with a pharyngeal bulb (Figures 1A, 1B and 1C). Patients presenting an anatomically normal palate, though with velopharyngeal dysfunction caused by a neuromuscular problem received a palatal lift prosthesis (Figure 2).

First, the patients were given the prostheses only with the anterior portion, i.e., the conventional prosthesis they needed (removable partial, complete denture, overdenture, etc.). When the patient presented no edentulous spaces, a metallic structure with clasps was made just to support the palatine portion. The construction technique fulfilled all the principles that rule the making of conventional prosthesis.

The making of the posterior portion was begun just after the patient was used to the anterior prosthesis ⁹. A brass wire was adapted to the end of the prosthesis to mold the posterior portion, which supported the impression compound. The wire was folded so that it

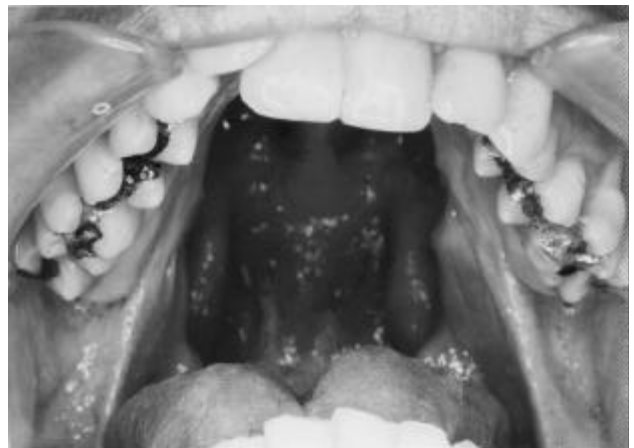
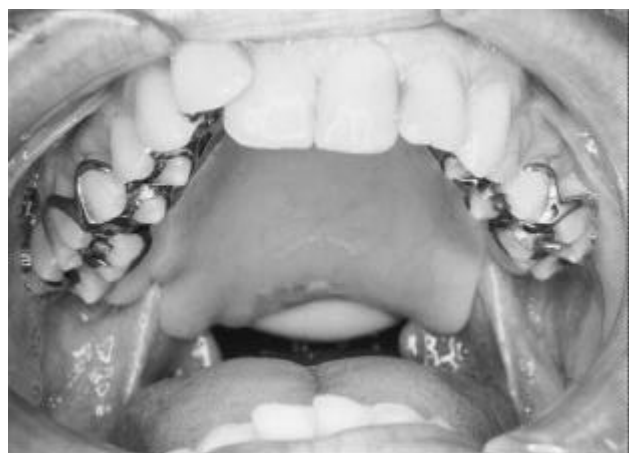
FIGURE 1A- Patient with open palate



formed a loop, attached to the prosthesis by means of two orifices, made with a multilaminar steel bur n. 5 (MAILLEFER) and acrylic resin. That way, it was prevented to loosen from the prosthesis while molding was performed ⁶.

The impression compounds used were the low fusion modeling compound (SYBRON KERR Industry and Commerce Ltd., Guarulhos, SP) and a wax for impressions (ADATPOL, J. F. JELENKO and Co. Inc. – New York, USA). A preliminary impression was initially taken adapting the modeling compound to the metallic loop. When the material was still plastic, the prosthesis was placed in the patient's mouth and he was properly asked by the speech pathologist to

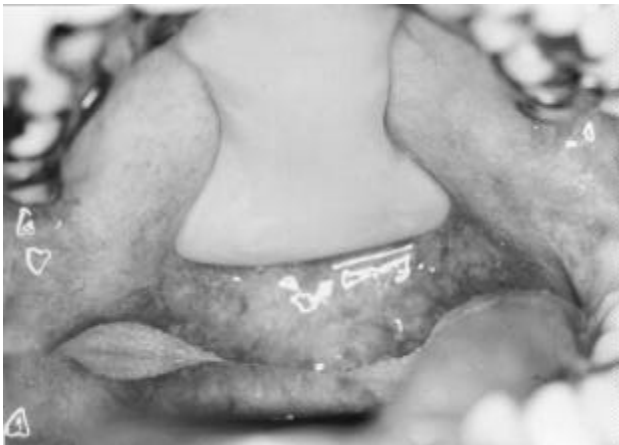


FIGURE 2- Lift prosthesis

produce some phonemes, move his head, and swallow.

The conclusion of the anatomical impressions of the velopharynx was performed with Adaptol[®], superficially added to the modeling compound, during the nasoendoscopy view. This exam consisted of introducing an optic fiber through the patient's nose up to a point that permitted a superior view of the velopharynx. The image was presented on a monitor and allowed all the staff and even the patient himself to observe the molding process. The intra-oral view alone would not be enough for this step.

After all the adjustments, the impression was properly included in a master cast, and the posterior portion was also processed with heat-activated acrylic resin.

The patients used the prosthesis for at least 6 months before they answered the following questionnaire (Table 1).

All the questionnaires were applied personally by the same examiner who just described the palate conditions, type of prosthesis, and explained the questions to the patient, whenever needed, trying not to induce or suggest any kind of answer.

RESULTS

The daily period of use of the prosthesis was approximately 24 hours for 29 (60.3%) patients, around 12 hours for 16 (33.3%), and only 3 of them

TABLE 1- Questionnaire applied to velopharyngeal dysfunction patients treated with a palatal prosthesis

-
- 1) During how many hours a day do you use your prosthesis?
Nearly 24 hours() Nearly 12 hours() Less than 8 hours()
 - 2) Do you eat with your prosthesis?
Yes() No() Sometimes()
 - 3) In relation to mastication, your prosthesis:
Makes it worst() Makes no difference() Improves()
The prosthesis is not used to eat()
 - 4) In your opinion, the prosthesis...
Worsens speech() Doesn't interfere with speech() Improves speech()
 - 5) Is your prosthesis stable while you speech?
Yes() No() Sometimes()
 - 6) Is your prosthesis stable while you eat?
Yes() No() Sometimes()
 - 7) In relation to comfort, your prosthesis is...
Comfortable() Slightly uncomfortable() Uncomfortable()
 - 8) Your life in general with the prosthesis...
Worsened() Had no changes() Improved()
-

(6.3%) used it for less than 8 hours a day.

Regarding the mastication results, 39 (81.2%) of the patients related they could eat while using the prostheses, 7 (14.6%) could not and 2 (4.2%) used to eat with their prostheses just occasionally.

In relation to mastication, 25 (52%) patients demonstrated an improvement, 9 (18.8%) stated it worsened, 12 (25%) subjects said it had no influence at all in mastication and 2 (4.2%) could not answer this question for they had never tried to eat with the prosthesis.

In relation to the patients' judgement regarding changes in speech with the prosthesis, the results demonstrated an improvement after the prosthesis was installed in 41 (85.4%) of the subjects, while 7 (14.6%) related no changes at all.

When the stability of the prosthesis was evaluated during speech, 44 (91.7%) patients stated the prosthesis was stable, against 4 (8.3%) who related occasional instability of the prosthesis during speech. Regarding the prosthesis' stability during mastication, 36 (75%) stated it was stable, 4 (8.3%) related instability, 6 (12.5%) reported the prosthesis was sometimes not stable and 2 (4.2%) did not answer that question due to never having tried to eat while using the prosthesis.

Regarding comfort with the use of the prosthesis, the results demonstrated that 38 (79.1%) felt comfortable with it, 9 (18.8%) related a slight discomfort and only 1 (2.1%) affirmed it was uncomfortable.

When assessing the life quality of the patients after the treatment with the palatal prosthesis, 41 (85.4%) patients related an improvement in their lives and 7 (14.6%) demonstrated no changes at all.

DISCUSSION

Most of the patients (60.3%) used their prostheses for nearly 24 hours a day despite being told not to use it during sleep. However, this information was not surprising. Literature has show that half of the evaluated patients also used their prostheses 24 hours a day, through a questionnaire applied to subjects who used conventional removable partial prostheses¹⁰. It is conceivable that patients who noticed enhancement and felt comfortable with the prosthesis considered it part of themselves, not willing to remove it anytime. Some patients have also related feeling embarrassed to remove the prosthesis in front of their spouses, the reason for nighttime usage.

Most of the patients (81.2%) affirmed to eat with

the palatal prosthesis, while those who referred to eat without it said it was due to the fact that the prosthesis had worsened their mastication. It is noticeable that 5 patients whose mastication was jeopardized by the prosthesis solved this matter simply by removing it at mealtime. The other 4 subjects (8.3%), on the other hand, maintained the use in some meals because they felt shame in removing it, especially in social happenings.

It must be taken into account that partial or total edentulous subjects may have a benefit in mastication with a dentate prosthesis. However, some studies have demonstrated that around 7% of the patients who used conventional removable prostheses, which replaced missing teeth, reported a jeopardized mastication with the prosthesis^{10, 14}. In the present study, 18.8% of the patients considered their mastication jeopardized by the palatal prosthesis. However, it must be underlined that some patients were not in need of a prosthesis to chew, and it was made just to improve speech.

Judgement of the speech performed by the patients themselves revealed 85.4% of the patients related an improvement with the palatal prosthesis. Nevertheless, the speech improvement has also been observed in patients without velopharyngeal dysfunction who used conventional prostheses although its influence, in these cases, was much less remarkable.

When the patients' satisfaction was related to speech and dysfunction etiology it could be noticed that only 28 of the 42 congenital cleft lip and palate patients were fully satisfied after the palatal prosthesis was placed. The speech compensatory mechanisms among congenital cleft patients are deep-rooted habits that cannot be eliminated simply by using the palatal prosthesis¹¹. Despite grimaces and nasal air emission have been previously found to disappear when the correction of the velopharyngeal sphincter is performed. These disturbances are often habits and persist, and the speech therapy is extremely important to improve speech.

Both patients presenting an acquired cleft related full satisfaction with their speech after using the palatal prosthesis. Speech recovery in these patients is very good because in general they do not present articulatory disorders, only hypernasality¹².

All 4 patients presenting velopharyngeal incompetence related improvement in speech, after using the palatal prosthesis. These findings agree with previous studies^{2, 4, 11, 15}. However, none of these patients was completely satisfied with their speech after treatment. It is probably due to the patients' expectation to recover the original speech they had before the accident that led to velopharyngeal

incompetence.

In relation to stability, the patients considered their palatal prostheses more stable in speech than mastication. This may be due to the fact that the articulatory movements are finer during speech, presenting contact only between soft tissues, or between them and the teeth. None of the patients related complete instability of the prosthesis during speech, but 4 (8.3%) related it was occasionally unstable.

Stability is a basic requirement in any kind of prosthesis, and most of the difficulties are obviously related to total prostheses. It was previously observed through a questionnaire that just 46.5% of the patients using conventional total prostheses considered it stable enough; a similar percentage of 46.5% was found to consider it just acceptable and 7% stated that stability was weak⁵. In patients with a cleft palate, it is even more difficult to get stable total prostheses, for their palates often present high surgical manipulation or fistulas. In these cases, dental implants are needed to support the prostheses¹³. Two patients needed implants to make prosthetic retention and stability possible. When the complete denture presents good stability, an attempt to construct the pharyngeal bulb would be worthy while. This stability may possibly be preserved after adapting the bulb, which was actually observed in those patients assessed in the present study who wore a complete denture.

Regarding the comfort with the palatal prosthesis, just one patient related a great discomfort and 9 (18.8%) reported a slight discomfort, especially in swallowing, when the prosthesis "scratched the throat". From the total sample, 38 subjects (79.1%) related feeling comfortable when using the prosthesis. This is a cheering percentage, for it is very close to the 83% found among patients with conventional removable partial prostheses¹⁴. These data are important because they illustrate that palatal prostheses may be well tolerated by the subjects.

At the end of the questionnaire, the patients were asked whether the palatal prosthesis use had improved their life quality any. From the total 48 patients, 41 (85.4%) related an improvement in their lives, 7 (14.6%) reported no changes, and these were the patients who did not observe any improvement in speech, except for one (2.1%), who had related his speech was better but who stated his life was not better. This may be due to the fact that this patient was very young (8 years old). Another patient has reported the opposite. He stated his life in general was better, even though his speech had not enhanced, because the palatal prosthesis improved his mastication, his

esthetics, and even other people considered his speech better.

Many authors have been writing on the indications of the palatal prosthesis^{1, 4, 6, 7, 8, 11}. The major concern about that is to avoid rivalry between several specialties or, even worse, between several professionals within the same center. In fact, the aim is the opposite, that the specialists have a great knowledge both of their specialties as well as other specialties which can be related to the same problem, so that the professional knows how to offer the patient the best care. A normal speech is one of the principal criteria for the cleft patient rehabilitation^{1, 3}.

In the present study, all patients presented problems with speech intelligibility, due to the hypernasal resonance associated with an articulatory disturbance, from the mildest to the most severe degree, before treatment was initiated. The sample was significantly heterogeneous also in relation to age, sex, access to speech therapy, improvement expectations, other complications in general health, dental conditions, presence of constricted pharyngeal walls, etc.

Despite the heterogeneity of the sample, the prosthetic treatment of velopharyngeal dysfunction has demonstrated an enhancement in patients' speech, besides fulfilling, whenever needed, the other basic requirements of a prosthesis, including esthetics and mastication.

CONCLUSIONS

1. Most patients (81.2%) reported they could eat using the palatal prosthesis. Half of the sample (52%) related improvement in mastication with the prosthesis and few subjects related worsening (18.8%).
2. Regarding speech, 85.4% reported it improved with the palatal prosthesis; the others stated there were no changes.
3. Most of the patients related the palatal prosthesis was stable during both nourishment (75%) and speech (91.7%).
4. The majority of the patients (79.1%) related feeling comfortable while using the palatal prosthesis.
5. The largest part of the patients (85.4%) related improvement in life quality with the prosthesis.
6. Despite the sample's heterogeneity, the prosthetic treatment of velopharyngeal dysfunction exhibited enhancement in patients' speech, besides fulfilling, whenever needed, the other basic requirements of a prosthesis.

RESUMO

O trabalho avaliou a efetividade do tratamento da disfunção velofaríngea com prótese de palato. A amostra consistiu em 48 pacientes, com idades variando entre 8 e 74 anos ($X = 31,47 \pm 16,03$), sendo 42 com insuficiência velofaríngea devido à fissura palatina congênita operada ou não, 2 com insuficiência velofaríngea devido à ressecção total ou parcial do palato (casos que tiveram câncer) e 4 com incompetência velofaríngea devido à paralisia total ou parcial do palato mole. Os resultados do questionário mostraram que: (1) a maioria dos pacientes preferiu se alimentar usando a prótese (81,2%); (2) a maioria relatou melhora da fala com a prótese (85,4%); (3) a prótese ficou estável para a maioria dos pacientes, tanto na alimentação (75%), quanto na fala (91,7%); (4) a maior parte dos pacientes (79,2%) sentiram-se confortável em usar a prótese; (5) a estética com a prótese foi satisfatória para a maioria dos pacientes (97,9%); (6) a qualidade de vida da maioria dos pacientes (85,4%), melhorou com o uso da prótese.

Unitermos: Fala; Insuficiência velofaríngea; Obturadores palatinos; Fala, fisiologia.

REFERENCES

- 1- Adisman IK. Cleft palate prosthetics. In: Grabb WC, Rosenstein SW, Bzoch KR, editors. Cleft lip and palate. Boston: Little Brown; 1971. p. 617-42.
- 2- Gonzales JB, Aronson AE. Palatal lift prosthesis for treatment of anatomic and neurologic palatopharyngeal insufficiency. Cleft Palate J 1970; 7:91-104.
- 3- Harkins CS. Role of the prosthodontist in the rehabilitation of cleft palate patients. J Am Dent Assoc 1951; 43:29-33.
- 4- Kipfmüller LJ, Lang BR. Treating velopharyngeal inadequacies with a palatal lift prosthesis. J Prosthet Dent 1972; 27:63-72.
- 5- Magnusson T. Clinical judgement and patients' evaluation of complete dentures five years after treatment: a follow-up study. Swed Dent J 1986; 10:29-35.
- 6- Mattos CMA. A prótese de fala como forma de reabilitação dos pacientes portadores de fissura lábio-palatal. Bauru; 1990. [Monografia de Especialização - Hospital de Pesquisa e Reabilitação de Lesões Lábio-Palatais, Universidade de São Paulo].
- 7- Mazaheri M. Indications and contra-indications for prosthetic speech appliances in cleft palate. Plast Reconstr Surg 1962; 30:663-9.
- 8- Mazaheri M. Prosthodontic care. In: Cooper HK, Harding RL, Krogman WM, Mazaheri M, Millard RT. Cleft palate and cleft lip: a team approach to clinical management and rehabilitation of the patient. Philadelphia: Saunders; 1979. p.285-314.
- 9- Mazaheri M, Mazaheri EH. Correction of palatal defects: a prosthodontist's viewpoint. J Oral Surg 1973; 31:913-7.
- 10- Nyhlin J, Gunne J. Opinions and wearing habits among patients new to removable partial dentures. An interview study. Swed Dent J 1989; 13:89-93.
- 11- Pegoraro-Krook MI. Avaliação da fala de pacientes que apresentam inadequação velofaríngea e que utilizam prótese de palato. São Paulo; 1995. [Tese de Doutorado – Escola Paulista de Medicina].
- 12- Plank DM, Weinberg B, Chalian VA. Evaluation of speech following prosthetic obturation of surgically acquired maxillary defects. J Prosthet Dent 1981; 45:627-38.
- 13- Roumanas ED, Nishimura RD, Davis BK, Beumer III J. Clinical evaluation of implants retaining edentulous maxillary obturator prostheses. J Prosthet Dent 1997; 77:184-90.
- 14- Van Wass M, Meeuwissen J, Meeuwissen R, Käyser A, Kalk W, Van't Hof M. Relationship between wearing a removable partial denture and satisfaction in the elderly. Community Dent Oral Epidemiol 1994; 22:315-8.
- 15- Williams W, Pegoraro-Krook MI, Dutka J, Turner G, Pinto JHN. Prótese de palato no tratamento da incompetência velofaríngea. In: Marchesan IQ, ed. Tópicos em fonoaudiologia 1996. São Paulo: Lovise; 1996. p.681-99.

Recebido para publicação em: 26/03/2003
Aceito após reformulações em: 17/05/2003

Address:

João Henrique Nogueira Pinto
Setor de Prótese do HRAC-USP
Rua Silvio Marchione, 3-20 – Vila Universitária
17043-900 – Bauru – SP
Telephone: 55(14)235-8086
Fax: 55(14)235-8162
e-mail: sandrab@usp.br