

# Papéis Avulsos de Zoologia

Museu de Zoologia da Universidade de São Paulo

Volume 55(18):255-260, 2015

[www.mz.usp.br/publicacoes](http://www.mz.usp.br/publicacoes)

[www.revistas.usp.br/paz](http://www.revistas.usp.br/paz)

[www.scielo.br/paz](http://www.scielo.br/paz)

ISSN impresso: 0031-1049

ISSN on-line: 1807-0205

## CRANIAL OSTEOLOGY OF *CYCLARHIS GUJANENSIS* (AVES: VIREONIDAE)

DIEGO MATIUSSI PREVIATTO<sup>1</sup>

SÉRGIO ROBERTO POSSO<sup>1,2</sup>

### ABSTRACT

*The small passerine Cyclarhis gujanensis can tear into small pieces large or heavy-bodied preys that could not be swallowed whole such as frogs, snakes, bats and birds. However there are few studies on the cranial anatomy of this species. Thus, we focused on the description of the cranial osteology to contribute to the anatomical knowledge of this species and to make some assumptions about functional anatomy. The fossa temporalis is shallow but broad and the fossa of os palatinum is deepened. The os quadratum processes are long and thick. The os pterygoideum is enlarged and the upper jaw is strongly inclined ventrally (140°) with reference to the skull. The rostral extremity of rhamphotheca is hooked with ventral concavity to fit the mandible (pincer form). The mandible fossae are deepened and broad and its bulky medial process probably provides mandible stability and strong support to the muscles attached on it. All these peculiar characteristics probably indicate a considerable force in the C. gujanensis jaws and partially explain its distinctive feeding habit compared with the other Vireonidae. Nevertheless, new studies with functional approaches to analysis the forces of the muscle fibers and the cranial kinesis are needed to prove the hypotheses mentioned above.*

KEY-WORDS: Rufous-browed Peppershrike; Skull; Osteology; Anatomy.

### INTRODUCTION

The Rufous-browed Peppershrike, *Cyclarhis gujanensis* (Gmelin, 1789), is a well distributed passerine in the Neotropical region where it occupies a wide range of habitats (Sick, 1997). Although it is considered an omnivorous bird, the literature revealed a peculiar foraging behavior. This little bird can capture and tear big preys as frogs, snakes, bats and birds (Moojen *et al.*, 1941; Sick, 1997; Ghizoni-Jr *et al.*, 2000; Andreau & Fernandes, 2010).

*C. gujanensis* uses the beak to tear apart large prey items held down with the foot (Snow, 1964).

However, the morphofunctional system of the feeding apparatus in *C. gujanensis* is little known. Only few studies on its anatomy are found (Beecher 1953, 1978; Raikow, 1978; Orenstein & Barlow, 1981), but none provided a detailed description of the cranial osteology and the morphological functions of the feeding apparatus.

Donatelli *et al.* (2014) stand out the importance to study the movements of the beak to apprehension and dilacerations of preys through an analysis from the jaw apparatus. Such approaches could enable us to understand this unique foraging strategy by this little passerine when compared to other heavy-bodied

<sup>1</sup> Universidade Federal de Mato Grosso do Sul – UFMS, Laboratório de Ecologia Sistemática e Conservação de Aves Neotropicals. Avenida Ranulpho Marques Leal, 3.484, Caixa Postal 210, CEP 79620-080, Três Lagoas, MS, Brasil.

<sup>2</sup> E-mail to corresponding author: srposso@hotmail.com  
<http://dx.doi.org/10.1590/0031-1049.2015.55.18>

and large carnivorous birds. Thus, we provided the description of the cranial osteology of feeding apparatus in *C. gujanensis* to contribute to the anatomical knowledge of this species and to discuss some aspects about functional anatomy and feeding habit of this bird.

## MATERIALS AND METHODS

We studied the cranial and jaw osteology based on eight adult specimens of *C. gujanensis* (Gmelin, 1789). We compared the descriptions with three specimens of *Vireo olivaceus* (Red-eyed Vireo) (Linnaeus, 1766) and two of *Vireo chivi* (Chivi Vireo) (Linnaeus, 1766). The material analyzed is from the collections of the Museum of Zoology, University of São Paulo (MZUSP: *Vireo chivi* 9A392, 9A393), the Museum of Natural History Taubaté (MHNT: *C. gujanensis* 630 and *Vireo olivaceus* 192, 808, 1066) and the Laboratory of Ecology, Systematics and Conservation of Neotropical Birds – UFMS (LESCAN: *C. gujanensis* 1, 2, 3, 11, 12, 13, 14).

We focused in bones associated with jaws movements and their morphological functions are based on previous studies (Bock, 1960, 1964; Cracraft, 1968; Richards & Bock, 1973; Zweers, 1974; Zusi, 1984; Gennip, 1986; Baumel *et al.*, 1993). The inconspicuous structures were described using an Olympus SZX12 stereo-microscope (Olympus, Tokyo). We used a protractor (180°) to calculate the angle of inclination between the upper jaw and the *arcus jugalis*. Specific measurements of all specimens were taken with a digital caliper to the nearest 0.01 mm: snout-vent length (SVL).

We followed *Nomina Anatomica Avium* (Baumel *et al.*, 1993) for the osteological terminology and some nomenclature modifications proposed by Burton (1984) and Posso & Donatelli (2005). The jaw apparatus were studied concurrently but this manuscript refers only to the osteological analysis. The analysis of the jaw muscles will be presented in another manuscript (Previatto & Posso (in press)).

## RESULTS

The frontal region (F) (Fig. 1) shows a little conspicuous and rostrally suture in the *zona flexoria craniofacialis* (ZFC) (Fig. 1). In the orbital portion, the lateral extremities of frontal medially are curved (concave) with an average width of 1.2 mm and the parietal region (*os parietale*) (P) (Fig. 1) has an average

width of 1.9 cm. It gives a stout head to the *C. gujanensis*. This difference is bigger in *V. olivaceus* and *V. chivi* (0.6 to 1.5 cm). The rostral apex of the upper jaw (*ossa maxillae*) (OM) (Figs. 1 and 3) shows a pronounced curvature when the *ramphotheca* is preserved, where we also observed a small concavity for engagement of the jaw (pincer form). The upper jaw is inclined ventrally at an angle of approximately 140° (Fig. 2) to the *arcus jugalis* and it is about half the total length of the skull (from 17.1 mm to 37.2 mm). The *arcus jugalis* (J) (Figs. 1 and 2) has an average of 16 mm in length, slightly less than half the total length of the skull, and its bones are completely fused to each other. The *arcus jugalis* shows strong curvature in *C. gujanensis* (140°) when compared with *V. chivi* and *V. olivaceus* (160°).

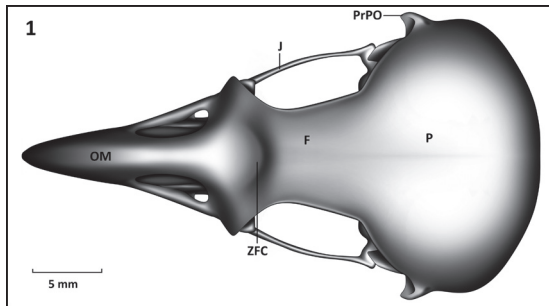
The bony projection 1 (*facies nasalis*) (Bp1) (Fig. 2) of the *os ectethmoidale* (E) (Fig. 2) is large and it fuses with *os lacrimale*. It is also observed in *V. chivi* and *V. olivaceus*. Apparently the *os lacrimale* (L) (Fig. 2) also fuses with the frontal region. The bony projection 2 (*facies orbitalis*) (Bp2) (Fig. 2) is larger in its ventral portion covering partially the *os palatinum* bones and it is in contact with the *arcus jugalis*, but not ventrally beyond it.

The *fossa temporalis* (FT) (Fig. 2) is shallow, but deepened in its rostroventral portion, dorsoventrally enlarged (embracing the dorsal portion of the *proc. postorbitalis*) and rostrocaudally shortened. The *fossa temporalis* is more reduced and deepened in *V. chivi* and *V. olivaceus*. The *fossa subtemporalis* (FST) (Fig. 2) is swallowed in all species studied.

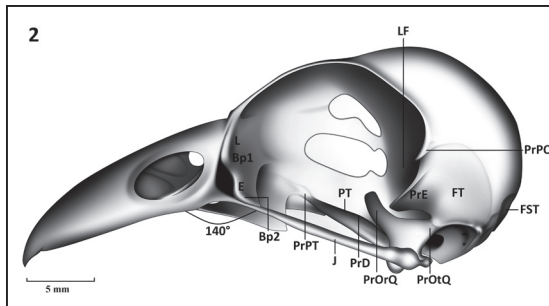
The *proc. squamosalis* (PrE) (Fig. 2) is long, with about half the distance of its insertion onto the skull to the *arcus jugalis* (4.5 mm by 8.3 mm) in *C. gujanensis*. It is laterally flattened and in its dorsal portion shows a semi-spiral form. The *proc. postorbitalis* (PrPO) (Figs. 1 and 2) is laminar (rostrocaudally flattened) and reduced, since its length from the distance between its origins in the skull to the *arcus jugalis* shows an average size of 3.3 mm (about one fifth of the distance of its insertion onto the skull to the *arcus jugalis*). In *V. chivi* and *V. olivaceus* the *proc. postorbitalis* is shorter (1/6 from its origin in the skull to the *arcus jugalis*) than in *C. gujanensis* (1/5). In the *pars caudalis orbitae* there is a narrow lateroesfenoidal fossa (LF) (Fig. 2) housing the first component of the *M. adductor mandibulae externus rostralis medialis*. Ventromedially we observed the *area muscularis aspera*, place of origin of the *M. pseudotemporalis superficialis*.

The *os palatinum* bone (PA) (Fig. 3) is wider in its caudal portion, tapering as it approaches its rostral

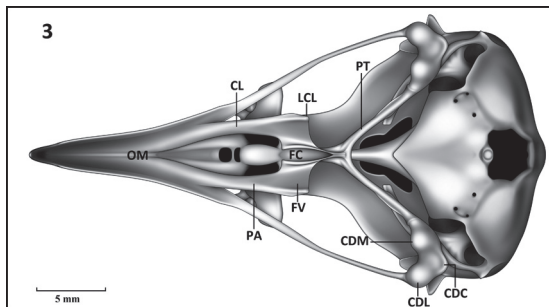
portion. Its caudolateral expansion is continuous with the *crista lateralis* (CL) (Fig. 3) with a slight ventral curvature. This crest extends to the caudal portion of the palate and it ends almost perpendicular to the boundary with the *proc. pterygoideum* of *os palatinum*, forming the *lamella caudolateralis* (LCL) (Fig. 3). Dorsomedially the *os palatinum* is flattened, where some fibers of the *M. pterygoideus dorsalis medialis* are originated. The *fossa choanalis* (FC) and *ventra-*



**FIGURE 1:** Dorsal view of the skull of *C. gujanensis* – F: *os frontale*; J: *arcus jugalis*; OM: *ossa maxillae*; P: *os parietale*; PrPO: *proc. postorbitalis*; ZFC: *zona flexoria craniofacialis*.



**FIGURE 2:** Lateral view of the skull of *C. gujanensis* – Bp1: bony projection 1; Bp2: bony projection 2; E: *os ectethmoidale*; FST: *fossa subtemporalis*; FT: *fossa temporalis*; J: *arcus jugalis*; L: *os lacrimale*; LF: lateroefenoidal fossa; PrE: *proc. esquamosalis*; PrPO: *proc. postorbitalis*; PrPT: *proc. pterygoideum*; PrD: *proc. dorsalis*; PrOrQ: *proc. orbitalis*; PrOtQ: *proc. oticus os quadratum*; PrPT: *proc. pterygoideum*.

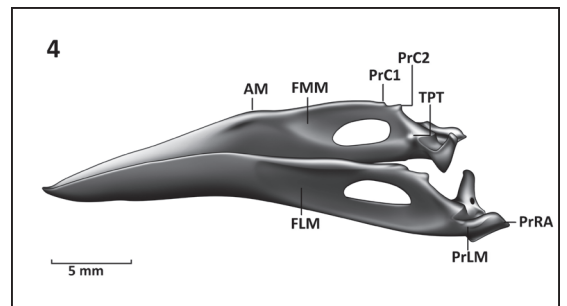


**FIGURE 3:** Ventral view of the skull of *C. gujanensis* – CDC: *condylus caudalis*; CDL: *condylus lateralis*; CDM: *condylus medialis*; CL: *crista lateralis*; FC: *fossa choanalis*; FV: *fossa ventralis*; LCL: *lamella caudolateralis*; OM: *ossa maxillae*; PA: *os palatinum*; PT: *os pterygoideum*.

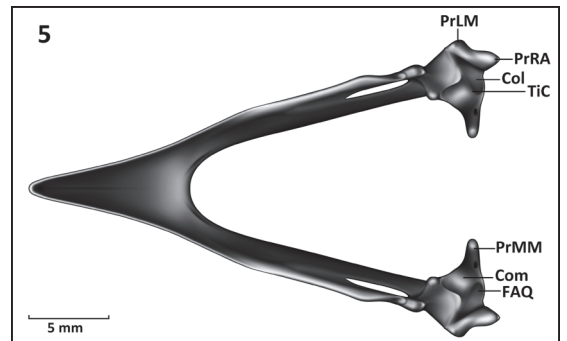
*lis* (FV) (Fig. 3) are both narrow and deep, but the first is narrower and deepened as it approaches to the *proc. pterygoideum* of *os palatinum*. The dorsal surface of the *os palatinum* lacks the *lamella choanalis* due to this bone is ventrally curved and also the *fossa ventralis* is deep. In *C. gujanensis* the *os palatinum* is caudally wider and its *fossa ventralis* is very deeper than in *V. chivi* and *V. olivaceus*. The *proc. pterygoideum* (PrPT) (Fig. 2) is narrow, long, and completely fused with the *os pterygoideum*. The *os pterygoideum* is robust (average of 8 mm and about 1/5 of the total length of the skull) in *C. gujanensis*.

*Cyclaris gujanensis* presented the *proc. orbitalis os quadratum* (PrOrQ) (Fig. 2) with a similar length to other vireos studied, but is wider and thicker, especially in its basal portion. The *proc. oticus os quadratum* (PrOtQ) (Fig. 2) is wide. Moreover the *sulcus intercotylaris* is deepened and the *condylus medialis* (CDM) (Fig. 3) is larger than the *condylus lateralis* (CDL) (Fig. 3) and *caudalis* (CDC) (Fig. 3).

The bones of the mandible are completely fused. The *pars simphysialis* reaches about one third of the total length of the mandible (from 9.1 mm to



**FIGURE 4:** Lateral view of the mandible of *C. gujanensis* – AM: *angulus mandibulae*; FLM: *fossa lateralis*; FMM: *fossa medialis*; PrC1: *proc. coronoides 1*; PrC2: *proc. coronoides 2*; PrLM: *proc. lateralis*; PrRA: *proc. retroarticularis*; TPT: *tuberculum pseudotemporalis*.



**FIGURE 5:** Dorsal view of the mandible of *C. gujanensis* – Col: *cotyla lateralis*; Com: *cotyla medialis*; FAQ: *fossa articularis quadratica*; PrMM: *proc. medialis mandibulae*; PrLM: *proc. lateralis mandibulae*; PrRA: *proc. retroarticularis*; TiC: *tuberculum intercotylaris*.

27.75 mm). In the intermediate portion, the *angulus mandibulae* (AM) (Fig. 4) is ventrally inclined at an angle of 150°. The *proc. coronioideus* 1 (PrC1) (Fig. 4) and 2 (PrC2) (Fig. 4) are reduced, but the latter is more prominent. The *tuberculum pseudotemporalis* (TPT) (Fig. 4), the local insertion for the *M. pseudotemporalis superficialis* is reduced. Both *fossa medialis* (FMM) (Fig. 4) and *fossa lateralis* (FLM) (Fig. 4) are broad and deepened. The *fossa lateralis mandibulae* showed similar size in the three species of vireos studied, but is deeper in *C. gujanensis*.

The *tuberculum intercotylaris* (TiC) (Fig. 5) is prominent. The *fossa articularis quadratica* (FAQ) (Fig. 5) is broad, being deeper in *C. gujanensis* than in the other vireos studied. The *cotyla medialis* (Com) (Fig. 5) is deeper than the *cotyla lateralis* (Col) (Fig. 5) due to its articulation with the large *condylus medialis* of the *os quadratum*.

The *proc. medialis mandibulae* (PrMM) (Fig. 5) is longer and thicker in the basal portion compared with *V. chivi* and *V. olivaceus*. The *proc. lateralis* (PrLM) (Figs. 4 and 5) is thick and prominent at the base but it apex is thin. The *proc. retroarticularis* (PrRA) (Figs. 4 and 5) is short and narrow.

## DISCUSSION

*Cyclarhis gujanensis* has strong curvatures of the beak and *arcus jugalis*, combined with the stout head and heavy and hooked beak. These strong curvatures can also be found in parrots (120 to 130°) (Thompson, 1899), a well-known strong-billed group of birds. In addition, when the *ramphotheca* is preserved, we observed a ventral curvature in its rostral end (pincer form) that could provide more power to peck and to cut preys in small pieces.

The *os lacrimale* is completely fused with the *os frontale* and *ectethmoidale*. This bony is absent or vestigial in many Passeriformes (Cracraft, 1968), including Vireonidae, due to the large *os ectethmoidale*, and it is generally supported by the *arcus jugalis*. The *ectethmoidale* is large and thick (pneumatic) in frugivorous species of Sturnidae due to the broad development of the adductor muscles, especially the *M. pseudotemporalis superficialis* (Beecher, 1978). However, our results showed that in *C. gujanensis* and *Vireo* the large *os ectethmoidale* does not appear to be modified by the reduced *M. pseudotemporalis superficialis*. The same results were observed by Orenstein & Barlow (1981).

Orenstein & Barlow (1981) argue that the *fossa temporalis* was restricted to lateral portion of the skull

as a result of the dorsal position of the *crista subtemporalis* in *C. gujanensis*, thereby preventing the *fossa temporalis* could extend to the caudal region of the skull. The same result was observed in this study. However, this fossa is more reduced and deeper in *V. chivi* and *V. olivaceus* than in *C. gujanensis*. In Dendrocolaptidae and Furnariidae (Donatelli, 1997 and Donatelli & Marceliano, 2007) this fossa is broad, longer than wide, except close to rostral region of the *proc. squamosalis* for Furnariidae. Richards & Bock (1973) found a reduced *fossa temporalis* in *Loxops*, located between the *proc. postorbitalis* and the *proc. squamosalis*.

The *proc. squamosalis* provides the broadest area of origin for large external adductor muscles in birds (Baumel *et al.*, 1993). Similar to *C. gujanensis*, it is also long in Dendrocolaptidae (Donatelli, 1997) and Furnariidae (Donatelli & Marceliano, 2007), but shorter and narrower in *V. chivi* and *V. olivaceus*. Richards & Bock (1973) stated that the size of *proc. postorbitalis* is related to the development of *M. adductor mandibulae externi rostralis temporalis* and *lateralis*. Indeed, these muscles are larger in *C. gujanensis* than in *V. chivi* e *V. olivaceus* and also in other vireos (Orenstein & Barlow, 1981).

The *fossa ventralis* of the palatine bones origins the ventral *os pterygoideum* muscles system which connects the palate to the laterocaudal, medial and caudomedial portions of the mandible (Bock, 1964; Bulher, 1981). This fossa is deepened in *C. gujanensis* probably due to selective pressures to tear larger preys played by the complex and bulky *os pterygoideum* muscles system (Orenstein & Barlow, 1981).

The *os pterygoideum* plays an important role in the jaw apparatus to transmit movement from the *os quadratum* to the *os palatine* and the other way around (Gennip, 1986). This bone is robust in *C. gujanensis*, similar to the other passerines (Donatelli, 1997, and Donatelli & Marceliano, 2007) and the other Vireonidae studied. Although the *os pterygoideum* primarily serves as the transmission mechanism of muscle movements, we observed few and tenuous muscles inserted on the *proc. dorsalis*. However, this process is useful to prevent bone disarticulation and to ensure the articulation between *os palatinum* and *pterygoideum* (Zweers, 1974).

The *os quadratum* plays important role in the jaw apparatus on birds. It connects some of its most important elements, namely the skull, mandible, *os pterygoideum* and *arcus jugalis*. In addition it is a bone of origin and insertion for several muscles (Gennip, 1986). In fact, the *os quadratum* plays a fundamental role in the skull kinesis, causing the force to be transmitted by the *os pterygoideum* and *os palatinum*

to the upper jaw (Zusi, 1984). *Cyclaris gujanensis* presented the *os quadratum* orbital process with a similar length to other vireos studied, but is wider and thicker, especially in its basal portion.

The both large lateral and medial condylus and deepened cotylas of the upper jaw are providing protection against mandible lateral disarticulations (Bock, 1960). According to Bock (1960) these features provide better support to prevent disarticulation of the mandible when the beak is opened. Therefore, it is an advantage for *C. gujanensis* since it needs a stronger more fixed mandible and so that the most powerful biting and crushing become more stabilized.

The deep *fossa lateralis mandibulae* and *articularis quadratic* showed similar size in the three species of vireos studied, but is deeper in *C. gujanensis*. According to Zusi (1984) these depressions are critical to the jaw apparatus articulation because they houses large adductor external muscles that elevate the mandible.

In *C. gujanensis* the *proc. medialis mandibulae* is longer and thicker in the basal portion compared with *V. chivi* and *V. olivaceus*. Similar results were observed in Furnariidae (Donatelli & Marceliano, 2007). In Icteridae, Bock (1960) found the process long and narrow, and he states it is a site for insertion to the muscles of the depressor system and of the *os pterygoideum*. Besides, Bock (1960) also argues that when this process is very long in birds, he could be in contact with the basitemporal plate and it serves as a support to avoid possible disarticulation of the mandible. Despite the large development of this process, it is difficult to argue that in *C. gujanensis* it provides more stability to peck without morphofunctional approaches.

## CONCLUSION

The broad and deep depressions of the palatine and mandible, where the muscles from the adductor and *pterygoideus* systems are lodged, combined with long processes (*proc. orbitalis os quadratum*, *proc. medialis ossa mandibulae* and *proc. squamosalis*) to support an origin or insertion to these muscles.

The position of the *arcus jugalis* with the upper jaw resulting in a very oblique angle provides strength to the prehensile in order to capture and to dilacerate large preys. On the other hand, the *fossa temporalis*, the region where the most developed external adductor muscles are found, is restricted to the lateral skull. In fact, it is dorsoventrally wide and deep only in its rostroventral region.

The strong, fused, hooked and curved bill, associated with long and large processes and fossae,

where the adductor muscles are housed, probably allow *C. gujanensis* to tear large preys into small pieces. These anatomical studies could partially explain its peculiar feeding behavior in comparison with other Vireonidae. However, further studies on functional approaches and analyzes of muscle fibers forces are necessary to corroborate/refute the hypotheses mentioned above.

## RESUMO

*O pitiguari (Cyclarhis gujanensis) é um pequeno vireonídeo com uma ampla variedade de presas, capaz inclusive de dilacerar presas maiores, como lagartos, morcegos e aves. No entanto, são escassos os estudos sobre morfologia craniana desta espécie, e, motivados pela sua maneira particular de alimentação, objetivou-se descrever a osteologia craniana para contribuir com os conhecimentos anatômicos dessa espécie, além de discutir alguns aspectos morfofuncionais relacionados à sua alimentação. A fossa temporal é ampla, porém pouco profunda, já o osso palatino apresentou fossas profundas. Os processos do osso quadrado são longos e espessos. O os pterygoideum é robusto e a maxila superior é fortemente inclinada (140°) em relação ao crânio. A extremidade rostral da ranfoteca é curvada acentuadamente, com formato côncavo em sua porção ventral para se encaixar com a mandíbula (forma de pinça). A mandíbula possui, além de fossas amplas e profundas, um processo medial bastante desenvolvido, que provavelmente dá suporte aos músculos que movimentam as maxilas. Tais características peculiares na osteologia craniana de C. gujanensis, poderiam explicar parcialmente o seu hábito alimentar diferenciado quando comparado com outros Vireonidae. Porém, novos estudos, com abordagens funcionais, cineses craniana e análises da força das fibras musculares da mandíbula são necessários para comprovar as afirmações mencionadas acima.*

PALAVRAS-CHAVES: Pitiguari; Crânio; Osteologia; Anatomia.

## ACKNOWLEDGMENTS

We are grateful to Luis F. Silveira (Museu de Zoologia da Universidade de São Paulo) and to Herculano Alvarenga (Museu de História Natural de Taubaté) to permit the osteological descriptions *in loco*. We also thank to André V.C. Levorato by the high-quality illustrations and Maria F.M. Ortiz by the English version of the manuscript.

## REFERENCES

- ANDREAU, M. & FERNANDEZ, D.P. 2010. Predación del juan chiviro (*Cyclarhis gujanensis*) sobre aves, murciélagos, reptiles y anfibios. *Nuestras Aves*, 54: 43-45.
- BAUMEL, J.J.; KING, A.S.; BREAZILE, J.E.; EVANS, H.E. & BERGE, J.C.V. 1993. Handbook of avian anatomy: Nomina Anatomica Avium. 2. ed. Cambridge, Nuttall Ornithological Club.
- BEECHER, W.J. 1953. A phylogeny of the Oscines. *The Auk*, 70: 270-333.
- BEECHER, W.J. 1978. Feeding adaptations and evolution in the starlings. *Bulletin of the Chicago Academy of Sciences*, 11: 268-297.
- BOCK, W.J. 1960. Secondary articulation of avian mandibulae. *The Auk*, 77: 19-55.
- BOCK, W.J. 1964. Kinetics of the avian skull. *Journal of Morphology*, 114: 1-42.
- BULHER, P.L. 1981. Functional anatomy of the avian jaw apparatus. In: King, A.S.E.; Melellaneds, J. (Eds.). *Form and function in birds*. London, Academic Press. p. 439-469.
- BURTON, P.J.K. 1984. Anatomy and evolution of the feeding apparatus in the avian orders Coraciiformes and Piciformes. *Bulletin of the British Museum Natural History*, 47(6): 331-443.
- CRACRAFT, J. 1968. The lacrimal-ectethmoid bone complex in birds: a single character analysis. *American Midland Naturalist*, 80: 316-359.
- DONATELLI, R.J. 1997. Osteologia e miologia cranianas de Dendrocolaptidae (Passeriformes, Tyranni) 1. Gêneros *Glyphorhynchus*, *Campylorhynchus*, *Dendrocincla*, *Xiphorhynchus* e *Dendrocolaptes*. *Aranajuba*, 5: 19-37.
- DONATELLI, R.J. & MARCELIANO, M.L.V. 2007. Osteologia e miologia cranianas de *Megaxenops paraguayae* (Furnariidae: Philydorinae) *Boletim Museu Paraense Emílio Goeldi Ciências Naturais*, 2: 183-215.
- DONATELLI, R.J.; HÖFLING, E. & CATALANO, A.L. 2014. Relationship between jaw apparatus, feeding habit and food source in the Oriental woodpeckers. *Zoological Science*, 31(4): 223-227.
- GENNIP, E.M.S.J. 1986. The osteology, arthrology and myology of the jaw apparatus on the pigeon (*Patagioenas livia* L.). *Netherlands Journal of Zoology*, 36: 1-46.
- GHIZONI-JR., I.R.; AZEVEDO, M.A.G. & POR-CARVALHO, M. 2000. Predação de *Hyla nalderevi* (Anura: Hylidae) por *Cyclarhis gujanensis* (Aves: Vireonidae) em Santa Catarina. *Melospittacus*, 3: 137-139.
- MOOJEN, J.; CARVALHO, J.C.M. & LOPES, H.S. 1941. Observações sobre o conteúdo gástrico das aves brasileiras. *Memórias do Instituto Oswaldo Cruz*, 36: 405-444.
- ORENSTEIN, R.I. & BARLOW, J.C. 1981. Variation in the jaw musculature of the avian family Vireonidae. *Life Sciences Contribution, Royal Ontario Museum*, 128: 1-60.
- POSSO, S.R. & DONATELLI, R.J. 2005. Skull and mandible formation in the cuckoo (Aves, Cuculidae): contributions to the nomenclature in avian osteology and systematics. *European Journal of Morphology*, 4(5): 163-172.
- PREVIATTO, D.M. & POSSO, S.R. (IN PRESS). JAW MUSCULATURE OF *CYCLARHIS GUJANENSIS* (AVES: VIREONIDAE). *BRAZILIAN JOURNAL OF BIOLOGY*, 76(1).
- RAIKOW, R.J. 1978. Appendicular myology and relationships of the New World nine-primaried oscines (Aves: Passeriformes). *Bulletin of Carnegie Museum of Natural History*, 7: 1-43.
- RICHARDS, L.P. & BOCK, W.J. 1973. Functional anatomy and adaptative evolution of the feeding apparatus in the Sawaiian honeycreeper genus *Loxops* (Drepanidae). *Ornithological Monographs*, 15: 1-73.
- STICK, H. 1997. *Ornitologia brasileira*. Rio de Janeiro, Nova Fronteira.
- SNOW, D.W. 1964. Peper-shisker. In: Thompson AL (Ed.). A new dictionary of birds. London, Nelson. p. 452-455.
- THOMPSON, D.W. 1899. On characteristic points in the cranial osteology of the parrots. *Proceedings of the Zoological Society of London*, 1: 9-46.
- ZUST, R.L. 1984. A functional and Evolutionary analysis of rhynchokinesis in birds. *Smithsonian Contributions to Zoology*, 395: 1-40.
- ZWEERS, G.A. 1974. Structure, movement and myography of the feeding apparatus of the mallard *Anas platyrhynchos*. L. *Netherlands Journal of Zoology*, 24: 323-467.

Aceito em: 08/04/2015  
 Impresso em: 30/06/2015