

doi: <http://dx.doi.org/10.11606/issn.1679-9836.v97i3p348-352>

The transrectal ultrasound/MRI fusion biopsy for prostate cancer diagnosis after previous negative biopsy: a case report

Biópsia transretal de próstata por fusão de imagens de ressonância magnética para o diagnóstico de câncer de próstata após biópsia prévia negativa: relato de caso

José Pontes-Júnior, Luiz Carlos Neves de Oliveira, Rafael Ferreira Coelho, Miguel Srougi, William Carlos Nahas

Pontes-Júnior J, Oliveira LCN, Coelho RF, Srougi M. The transrectal ultrasound/MRI fusion biopsy for prostate cancer diagnosis after previous negative biopsy: a case report / *Biópsia transretal de próstata por fusão de imagens de ressonância magnética para o diagnóstico de câncer de próstata após biópsia prévia negativa: relato de caso*. Rev Med (Sao Paulo). 2018 May-June;97(3):348-52.

ABSTRACT: *Introduction:* The adoption of multiparametric MRI (mpMRI) guided fusion biopsy is becoming an important tool to improve the diagnostic yield in those suspected of having prostate cancer, especially for patients with suspicious lesion located at the anterior region that is uncommonly sampled at randomized biopsy. *Methods:* Herein we report a case of a man with persistent elevated PSA and a previous negative randomized prostate biopsy. His PSA was 8.1 ng/dL and a multiparametric MRI showed a 2cm suspicious PIRADS-4 lesion located at the anterior region of the right transition zone at base and mid gland. A transrectal ultrasound/MRI (TRUS/mpMRI) fusion biopsy was performed and its pathologic report showed a Gleason 3+4 (ISUP II) that was present only in the fragments that sampled the suspected area at MRI. We review the role of mpMRI in the diagnosis of prostate cancer at rebiopsy.

Keywords: Prostate/pathology; Image-guided biopsy/methods; Prostatic neoplasms/diagnosis; Prostatic neoplasms/diagnostic imaging; Prostatic neoplasms/pathology.

RESUMO: *Introdução:* A adoção da biópsia de próstata guiada por fusão de imagens de ressonância magnética (RM) multiparamétrica está se tornando um método importante no diagnóstico do câncer de próstata, especialmente para aqueles com suspeita de lesão localizada na região anterior, que normalmente não é amostrada na biópsia randomizada. *Métodos:* Aqui relatamos um caso de homem com PSA persistentemente elevado e com uma biópsia randomizada anterior negativa. O PSA atual era de 8,1 ng / dL e a ressonância magnética multiparamétrica mostrou uma lesão suspeita PIRADS-4 de 2 cm localizada na região anterior da zona de transição direita na altura da base e terço médio da glândula. Foi realizada uma biópsia transretal guiada por fusão de imagens de ressonância multiparamétrica (TRUS / mpMRI) e o exame anatomopatológico mostrou a presença de adenocarcinoma escore de Gleason 3 + 4 (ISUP II) apenas nos fragmentos amostrados na área suspeita da mpMRI. Revisamos o papel da mpMRI no diagnóstico do câncer de próstata na rebiópsia.

Descritores: Próstata/patologia; Biópsia guiada por imagem/métodos; Neoplasias da próstata; Neoplasias da próstata/diagnóstico por imagem; Neoplasias da próstata/patologia.

Hospital das Clínicas HCFMUP, Faculdade de Medicina, Universidade de Sao Paulo, Sao Paulo, SP, BR.

ORCID/Email: Pontes Junior J - <https://orcid.org/0000-0001-7012-7806>, docjpir@uol.com.br; Oliveira LCN: <https://orcid.org/0000-0001-8738-7241>, lcouro@uol.com.br; Coelho RF - coelhouro@yahoo.com.br; Srougi M - srougi@srougi.com.br; Nahas WC - wnahas@uol.com.br

Correspondent author: José Pontes Jr. Faculdade de Medicina da USP Av. Dr. Arnaldo 455, 2º andar, sala 2145. Cerqueira César. Sao Paulo, SP, Brazil. CEP: 01246-903. E-mail: docjpir@uol.com.br.

INTRODUCTION

Prostate cancer (PC) is the most common solid malignancy in western countries including Brazil¹. The slow-growing nature, the heterogeneous clinical behavior and the long latency time of many cases highlight the need to predict which tumors will grow and spread beyond the prostate as compared to indolent tumors². The diagnosis is usually established by transrectal ultrasound guided biopsy where a minimum of 12 cores are sampled in a randomized fashion under local anesthesia. The caveats with the 12-core biopsy are two-fold, there is a 30% false negative rate and an increase in the diagnosis rate of insignificant cancer³.

The multiparametric magnetic resonance imaging (mpMRI) is a noninvasive method of identifying tumor location in the prostate as well as functional characteristics to predict tumor behavior and is employed in the diagnosis, staging and follow-up of patients after local treatment or active surveillance⁴. The accuracy of PC diagnosis based on mpMRI is higher when compared to TRUS, and one of its advantage is that Gleason score higher than 6 are preferentially visualized by this method⁴. The suspected lesions at mpMRI are classified according to the PIRADS-2 criteria that range from 1-very low risk to 5-high risk of clinically significant PC (PCcs)⁵. Herein we report a case of a patient with persistent elevated PSA and a previous negative randomized prostate biopsy who underwent a transrectal ultrasound/mpMRI fusion biopsy. Additionally, we review the role of mpMRI in the diagnosis of PC at rebiopsy.

CASE REPORT

A 68-year-old white male patient came to a routine urological evaluation. No lower urinary tract symptoms or any other symptom was informed. He reported having systemic arterial hypertension on treatment with an ACE inhibitor. He denied any family history of PC.

Clinical examination of the external genitalia and the abdomen was normal. At the digital rectal examination, the prostate was enlarged to about 40g with a fibroelastic consistency and without suspected nodules. Laboratory tests (blood count and urine test strip) did not reveal any abnormalities. The serum PSA level was 5,7ng/dl and the free PSA was 14%. Further investigations were pursued by suprapubic ultrasound that showed signs of benign prostatic hyperplasia with a prostate volume of 44g, no post-voiding residual urine or upper urinary tract without abnormalities. A prostate biopsy was performed with a sampling of 12 fragments that showed no malignancy. Thus, he was advised to return in a year.

The patient returns after one year, with no voiding complaints for a new routine urological examination. The PSA was 8.15 ng/dl, free PSA 11% and again the DRE was unsuspecting. Because of a previous negative biopsy a mpMRI was required. It was performed in a high-field 3-tesla unit without an endorectal coil and it showed a suspicious 2 cm PIRADS 4 lesion in the anterior region of the transitional zone at right base and mid gland. The lesion was ill delimited and had a hypointense signal at T2 and diffusion weighted ADC map sequences (Figure 1). Subsequently a transrectal ultrasonography /MRI fusion-guided biopsy was performed and the pathologic report showed a Gleason score 3+4 (ISUP group 2) usual adenocarcinoma. The tumor was present only at the 4 cores that sampled the suspected area at MRI. The maximum core involvement was up to 55%.

DISCUSSION

The mpMRI has emerged as an important tool to more accurately determine the risk of significant disease at diagnosis because it provides an anatomical assessment which can determine the presence and location of the significant tumor⁴. The typical lesions have a hypointense signal on T2-weighted images; however other conditions may also have the same appearance such as androgen deprivation therapy, prostatitis, benign prostatic hyperplasia, previous radiotherapy. At the dynamic contrast-enhanced (DCE) phase the tumor shows a rapid contrast enhancement and wash-out, and at the DWI-ADC map the lesion is typically hypointense. The DCE and DWI imaging sequences provide more functional information and provide a comprehensive evaluation of suspected lesions and the joint analysis of the findings in these three parameters yields the PIRADS degree that is considered suspicious when it is ≥ 3 ⁵.

One of the most interesting aspects is that suspicious changes in mpMRI are associated with a greater chance of PC with Gleason score ≥ 7 . Thus, we could potentially reduce the diagnosis of indolent tumors if we biopsy only patients with suspected MRI. This test detects 95% of prostate tumors with GS > 7 , when they present a tumor volume from 0.5 mL and have a negative predictive value of 80% - 98% for high risk tumors⁶.

In our case, the suspect area in the mpMRI was in the anterior transition zone around the midline, which is a area that is not usually sampled in systematic biopsy with 12 fragments (Figure 1). It should be emphasized that at the ultrasound images there was no suspected hypoechoic lesion in this region. The biopsy of this region confirmed the diagnosis of PCcs which is in accordance with the literature data.

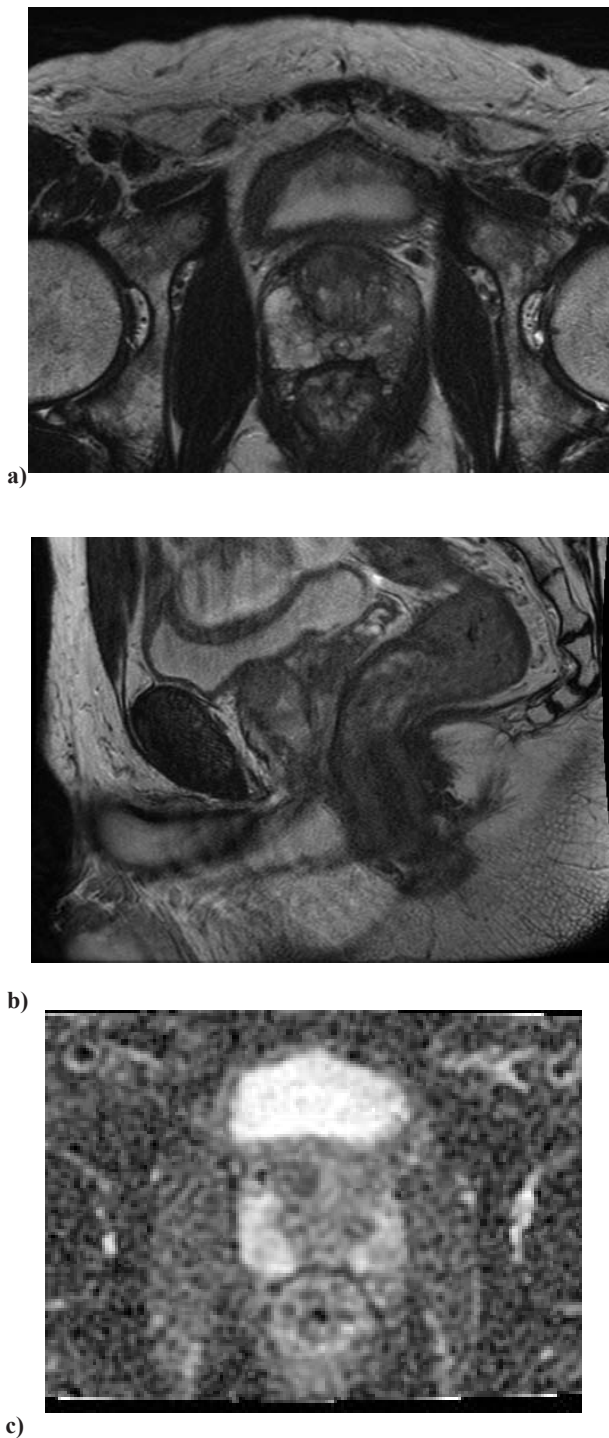


Figure 1 – mpMRI showing a suspicious 2 cm PIRADS 4 lesion in the anterior region of the transitional zone at right base and mid gland. T2 axial (a), T2 sagittal (b), and diffusion weighted DWI axial images (c)

The benefit of mpMRI in PC diagnosis was demonstrated by Sidiqui et al.⁷, who prospectively compared 1,003 patients sequentially submitted to MRI-guided biopsy versus USTR-guided biopsy with 12 fragments of which 43% had a previous negative biopsy⁷.

Similar PC detection rates were observed between the two methods 45.9% vs. 46.7%, but the biopsy guided by mpMRI detected 30% more high grade PC (173 vs. 122 cases) and reduced by 16% the detection of low grade tumors (213 vs. 258 cases ($p < 0.001$)). To diagnose a high-grade PC, 30.7 fragments were required in the mpMRI-guided biopsy and 100.8 in the USTR-guided biopsy. When considered the tumors that USTR-guided biopsy did not detect, 60% of them were $GS \geq 7$ while this rate fell to 1% in the mpMRI-guided biopsy group. The mpMRI-guided biopsy also showed greater concordance of the Gleason score of the biopsy vs. of the surgical specimen in the 170 operated cases ($p < 0.05$)⁷.

According to the literature, mpMRI-guided biopsy seems to have an advantage in patients with previous negative biopsy and persistence of suspected PC. A meta-analysis of 16 studies, in which 1929 men with suspected mpMRI who underwent TRUS-guided biopsy versus mpMRI-guided biopsy, showed a significant increase in PC detection of 54% (relative sensitivity 1.54, 95% CI 1.05-2.57 vs. 1.10, 95%, CI 1.00-1.22) in favor of mpMRI in patients with a history of previous negative biopsy and 10% in patients without previous biopsy⁸. The European and American Urological Association guidelines recommend that an mpMRI should be performed when a re-biopsy is indicated, and that at prostate biopsy 2 to 4 fragments must be sampled in the suspected mpMRI area plus the 12 randomized fragments^{6,9}.

Another interesting characteristic is the higher negative predictive value of a normal mpMRI for PCcs that is around 90-95%, making the exam a useful tool in determining whether a patient is a candidate for biopsy. Based on this finding some authors propose that a normal resonance be enough to not indicate a biopsy and that in the case of an altered MRI we could only sample the suspected lesion¹⁰.

Addressing the first question a multicenter prospective study (PROMIS trial) with 576 patients compared the performance of mpMRI-guided vs. TRUS-guided prostate biopsy and observed negative predictive value for any cancer and for significant cancer of 76 and 89%, respectively. It means that if one postpones the biopsy due a normal mpMRI this would lead to the loss of 24% of PC and 11% of PCcs cases¹¹. Corroborating these results, a meta-analysis of 48 studies with 9613 found a negative predictive value of 82% for any PC and 88% for PCcs. Thus, again if a biopsy was contraindicated because of a normal mpMRI, about 12% of intermediate and high-risk tumors would not be diagnosed¹². Current consensus also agrees that an mpMRI per se is not yet sufficient to postpone a biopsy in the presence of clinical suspicion^{6,9}.

Addressing the question if we should sample only the suspected areas in patients with an altered mpMRI undergoing target biopsy, Borofsky et al.¹³, retrospectively evaluated 100 patients who had undergone mpMRI and

subsequent radical prostatectomy due PC diagnosis. The authors compared the pre-operative mpMRI findings with the whole-mount pathology slices report and found that of the 162 lesions, 136 (84%) were correctly identified with mpMRI but the size of 8 lesions was underestimated. Among the 26 (16%) lesions missed at MRI, GS was 3+4 in 65%, 4+3 in 4%, 4+4 in 27%, and 4+5 in 4% of patients. On a per-patient basis, mpMRI depicted clinically important PC in 99 of 100 patients however at least one clinically important tumor was missed in 26 (26%) patients, and lesion size was underestimated in eight (8%) if only suspected areas were biopsied. They concluded that the limitation of mpMRI imaging is important, and new approaches to reduce this false-negative rate are needed¹³. Thus, despite the high negative predictive value of mpMRI, it is still early to abandon the systematic biopsy with 12 fragments. Thus, as a rule, 12 randomized fragments must be sampled, plus 2 to 4 fragments directed to the suspected area in the mpMRI^{6,9}.

There is no consensus as to whether mpMRI should be performed in patients already on the first biopsy, mainly because 2 meta-analysis studies based on retrospective studies have not shown an advantage in patients with no previous biopsy⁶. However, the first randomized, multicenter study that evaluated this situation was recently published. In this trial 500 men with a clinical suspicion of PC who had not undergone biopsy previously were assigned to undergo mpMRI, with or without targeted biopsy, or standard TRUS-guided biopsy¹⁴. Men in the mpMRI-targeted biopsy group underwent a targeted biopsy (without standard biopsy cores) if the MRI was suggestive of PC; and men whose MRI results were not suggestive of PC were not offered biopsy¹⁴. Regarding the overall PC detection there was no difference 46.8 vs. 47%, but the mpMRI arm showed a higher rate of PC diagnosis 38 vs. 26% $p=0.005$ and lower rate of insignificant PC 9 vs 22% $p<0.0001$. At the mpMRI arm 28% of patients had a PIRADS 1 - 2 and were not biopsied¹⁴. If the results of these trials are confirmed and the cost effectiveness studies also show advantage of the mpMRI in this scenario probably mpMRI will be also recommended for men with clinical suspicion of PC and no previous biopsy. The two critics to this study is that the patients with normal mpMRI did not undergo biopsy and based at the Promis trial results we know that 10% of PCes will be missed if the biopsy is not performed¹¹. Additionally, we must highlight that in 22% of cases there was a PIRADS assignment disagreement between the radiologist at the trial raising concern about the act of not offering biopsy if the PIRADS was less than 3.

There are three ways to perform the mpMRI guided biopsy. At the in-bore method the biopsy is performed inside the MRI device, it requires special material and the costs are higher. The advantage is that it would be a true real-time mpMRI-guided biopsy technique. The cognitive method does not require any special apparatus. In this

method the images of the mpMRI are arranged next to the ultrasound device and the urologist cognitively samples the suspected area. The TRUS/mpMRI fusion biopsy requires ultrasound devices with special software that are fed with the images of the previously performed mpMRI and during the performance of the ultrasound the images of the mpMRI are coupled in real time with the images of the ultrasound and the suspected area is theoretically sampled with greater accuracy.

There is no clear evidence of superiority of one mpMRI-guided biopsy method over the other^{6,9}. A meta-analysis evaluated the results of the three methods in more than 3,500 patients in 39 studies¹⁵. Among the included studies 11 used the in-bore method, 17 employed the fusion guided method and 11 employed the cognitive biopsy. There was a significant advantage ($p = 0.02$) of in-bore compared with cognitive for overall PC detection. For overall PC detection there was no significant advantage of in-bore compared with fusion biopsy ($p=0.13$), and neither for fusion compared with cognitive ($p=0.11$). For PCes detection there was no significant advantage of any technique of MRI-guided biopsy¹⁵.

In conclusion it is clear that the mpMRI has an important role in PC diagnosis. It is strongly recommended in patients with PC suspicious and previous negative biopsy and now we have some data also indicating advantage of the exam even in patients with no previous biopsy. The mpMRI has a high negative predictive value however it cannot avoid a systematic biopsy in patients with no prior biopsy.

Disclosure/Conflict of Interest: The authors have no conflict of interest to declare.

REFERENCES

1. Jemal A, Bray F, Center MM, Ferlay J, Ward E, Forman D. Global cancer statistics. *CA Cancer J Clin.* 2011;61:69-90. doi: 10.3322/caac.20107.
2. Estebanez J, Teyrouz A, Gutierrez MA, Linazasoro I, Belloso J, Cano C, Peralta JM, Sanz JP. Natural history of prostate cancer. *Arch Esp Urol.* 2014;67(5):383-7.
3. Verbeek JFM, Roobol MJ. What is an acceptable false negative rate in the detection of prostate cancer? ERSPC Rotterdam study group. *Trans Androl Urol.* 2018;7(1):54-60. doi: 10.21037/tau.2017.12.12.
4. Kumar V, Bora GS, Kumar R, Jagannathan NR. Multiparametric (mp) MRI of prostate cancer. *Prog Nucl Magn Reson Spectrosc.* 2018;105:23-40. doi: 10.1016/j.pnmrs.2018.01.001.
5. Barentsz JO, Weinreb JC, Verma S, Thoeny HC, Tempny CM, et al. Synopsis of the PI-RADS v2 Guidelines for multiparametric prostate magnetic resonance imaging and recommendations for use. *Eur Urol* 2016;69(1):41-9. doi: 10.1016/j.eururo.2015.08.038.
6. Mottet N, Bellmunt J, Bolla M, Briers E, Cumberbatch

- MG, De Santis M, et al. EAU-ESTRO-SIOG Guidelines on Prostate Cancer. Part 1: Screening, diagnosis, and local treatment with curative intent. *Eur Urol*. 2017;71(4):618-62
7. Siddiqui MM, Rais-Bahrami S, Turkbey B, George AK, Rothwax J, Shakir N, et al. Comparison of MR/ultrasound fusion-guided biopsy with ultrasound-guided biopsy for the diagnosis of prostate cancer. *JAMA*. 2015;215(13):390-7. doi: 10.1001/jama.2014.17942.
 8. Schoots IG, Roobol MJ, Nieboer D, Bangma CH, Steyerberg EW, Hunink MG. Magnetic resonance imaging-targeted biopsy may enhance the diagnostic accuracy of significant prostate cancer detection compared to standard transrectal ultrasound-guided biopsy: a systematic review and meta-analysis. *Eur Urol*. 2015;68(3):438-50. doi: 10.1016/j.eururo.2014.11.037.
 9. Sanda MG, Cadeddu JA, Kirkby E, Chen RC, Crispino T, et al. Clinically localized prostate cancer: AUA/ASTRO/SUO Guideline. Part I: Risk stratification, shared decision making, and care options. *J Urol*. 2017;pii: S0022-5347(17)78003-2. doi: 10.1016/j.juro.2017.11.095.
 10. Pepe P, Garufi A, Priolo GD, Galia A, Fraggetta F, Pennisi M. Is it time to perform only MRI targeted cores? Our experience in 1032 men submitted to prostate biopsy. *J Urol*. 2018;pii: S0022-5347(18)43030-3. doi: 10.1016/j.juro.2018.04.061.
 11. Ahmed HU, El-Shater Bosaily A, Brown LC, Gabe R, Kaplan R, et al. Diagnostic accuracy of multi-parametric MRI and TRUS biopsy in prostate cancer (PROMIS): a paired validating confirmatory study. *Lancet*. 2017;389(10071):815-22. doi: 10.1016/S0140-6736(16)32401-1.
 12. Moldovan PC, Van den Broeck T, Sylvester R, Marconi L, Bellmunt J, et al. What is the negative predictive value of multiparametric magnetic resonance imaging in excluding prostate cancer at biopsy? A systematic review and meta-analysis from the European Association of Urology Prostate Cancer Guidelines Panel. *Eur Urol*. 2017;72(2):250-66. doi: 10.1016/j.eururo.2017.02.026.
 13. Borofsky S, George AK, Gaur S, Bernardo M, Greer MD, et al. What are we missing? False-negative cancers at multiparametric MR imaging of the prostate. *Radiology*. 2018;286(1):186-95. doi: 10.1148/radiol.2017152877.
 14. Kasivisvanathan V, Rannikko AS, Borghi M, Panebianco V, Mynderse LA, et al. MRI-targeted or standard biopsy for prostate-cancer diagnosis. *N Engl J Med*. 2018; 378(19):1767-77. doi: 10.1056/NEJMoa1801993.
 15. Wegelin O, van Melick HHE, Hooft L, Bosch JLHR, Reitsma HB, et al. Comparing three different techniques for magnetic resonance imaging-targeted prostate biopsies: a systematic review of in-bore versus magnetic resonance imaging-transrectal ultrasound fusion versus cognitive registration. Is there a preferred technique? *Eur Urol*. 2017;71(4):517-31. doi: 10.1016/j.eururo.2016.07.041.
- Submitted for publication: May 25, 2018
Accepted in: June 18, 2018