

## Minimally invasive surgical treatment in patients with immunological thrombocytopenic purpura: total splenectomy by a hybrid mini-laparoscopic technique

### *Tratamento minimamente invasivo em pacientes com púrpura trombocitopenica imunológica: esplenectomia por uma técnica minilaparoscópica híbrida*

Gustavo Lopes de Carvalho<sup>1</sup>, Diego Laurentino Lima<sup>2</sup>, Raquel Nogueira Cordeiro<sup>3</sup>,  
Gustavo Henrique Belarmino de Góes<sup>4</sup>, Marianna Castro Araújo Lessa<sup>5</sup>

Carvalho GL, Lima DL, Cordeiro RN, Góes GHB, Lessa MCA. Minimally invasive surgical treatment in patients with immunological thrombocytopenic purpura: total splenectomy by a hybrid mini-laparoscopic technique / *Tratamento minimamente invasivo em pacientes com púrpura trombocitopenica imunológica: esplenectomia por uma técnica minilaparoscópica híbrida*. Rev Med (São Paulo). 2020 Jan-Feb;99(1):76-9.

**ABSTRACT:** Two female patients, one 28 years-old, and the other 61 years-old, with a history of asthenia, purpura and thrombocytopenia (both <15,000 platelets / mm<sup>3</sup>). Once other etiologies were excluded, and the diagnosis of immune thrombocytopenic purpura (ITP) was established, corticoid therapy was started in both cases. However, the patients remained with a platelet count <20,000 / mm<sup>3</sup>, characterizing refractory ITP, and the splenectomy was indicated. The surgical team opted for a hybrid minimally invasive surgical procedure. Providing a better visualization of the surgical field, less abdominal trauma, greater technical dexterity, and early hospital discharge, the use of minilaparoscopic instruments proved to be a safe and effective approach for these patients.

**Keywords:** Laparoscopy; Splenectomy; General surgery; Purpura, thrombocytopenic.

**RESUMO:** Duas pacientes, uma com 28 anos e outro com 61 anos de idade, apresentavam quadro de astenia, púrpura e trombocitopenia (ambos < 15.000 plaquetas/mm<sup>3</sup>). Após a exclusão de outras etiologias e com o estabelecimento do diagnóstico de púrpura trombocitopênica imunológica (PTI), ambos iniciaram terapia com corticoides. Entretanto, ambos pacientes permaneceram com plaquetas < 20.000 /mm<sup>3</sup>, caracterizando PTI refratária e com a indicação de esplenectomia. A equipe cirúrgica optou por uma abordagem minilaparoscópica híbrida. Com uma melhor visualização do campo cirúrgico, menos trauma abdominal, mais destreza nos movimentos e com alta hospitalar precoce, o uso de instrumentos minilaparoscópicos se provou uma abordagem segura e eficaz para esses pacientes.

**Descritores:** Laparoscopia; Esplenectomia; Cirurgia geral; Púrpura trombocitopênica.

1. University of Pernambuco. University Hospital Oswaldo Cruz. Department of General Surgery. <https://orcid.org/0000-0001-9644-8333>. Email: [gldmd1@gmail.com](mailto:gldmd1@gmail.com).

2. Research Fellow - Department of Surgery, Montefiore Medical Center, New York, United States. <https://orcid.org/0000-0001-7383-1284>. Email: [dilaurentino@gmail.com](mailto:dilaurentino@gmail.com).

3. Research Fellow - Department of Surgery, Montefiore Medical Center, New York, United States. <https://orcid.org/0000-0003-1368-5021>. Email: [raquelnogueiracordeiro@gmail.com](mailto:raquelnogueiracordeiro@gmail.com).

4. Medical Student at University of Pernambuco. <https://orcid.org/0000-0003-3366-1182>. Email: [gustavogoesmt@hotmail.com](mailto:gustavogoesmt@hotmail.com).

5. Medical Student at University of Pernambuco. <https://orcid.org/0000-0002-5090-6703>. Email: [marianna.lessa@hotmail.com](mailto:marianna.lessa@hotmail.com).

**Correspondence:** Diego Laurentino Lima. Rua: Desembargador Joao Paes, 421, apart. 1101. Recife, Pernambuco. ZIP CODE: 51021-360. Email: [dilaurentino@gmail.com](mailto:dilaurentino@gmail.com).

## INTRODUCTION

Immune or autoimmune thrombocytopenic purpura (ITP) is a hematological disorder, characterized by the production of autoantibodies against platelet membrane proteins, leading to the destruction of platelets by the reticuloendothelial system<sup>1,2</sup>.

Despite the complications, ITP is benign and usually does not present central nervous system (CNS) or gastrointestinal bleeding. The first line of treatment is corticotherapy, or human immunoglobulin (in selected cases). If the condition persists with platelets  $< 20,000/\text{mm}^3$  (even if asymptomatic) and/or bleeding (regardless of platelet count), splenectomy is suggested<sup>3</sup>.

Traditionally a laparotomic splenectomy would be the option; however, the minimally invasive approaches have been shown to be more effective in these cases and are currently considered the gold standard surgical treatment<sup>4</sup>. Among the laparoscopic procedures, a hybrid approach consists the use of mini-laparoscopic instruments and one or two regular 5 mm laparoscopic instruments<sup>5</sup>. It's called a hybrid procedure due to the use of a 5 mm instrument such as a vessel sealing device, unavailable in a 3 mm size.

The aim of this study is to report two successful cases of hybrid, mini-laparoscopic splenectomies to demonstrate its safety and effectiveness as an alternative to the current therapeutic methods.

## CASE REPORT 1

A 28 year-old female patient, obese, diagnosed eight years ago with ITP refractory to corticoid use, with

a platelet count of  $8,000/\text{mm}^3$ . Since then, the patient has been presented with body pain, ecchymoses, and a diffused petechiae. Ultrasonography (USG) of the abdomen revealed hepatosplenomegaly; thus, a hybrid mini-laparoscopic splenectomy was proposed. Preoperatively, the platelet count was  $22,000/\text{mm}^3$ , and human immunoglobulin was infused.

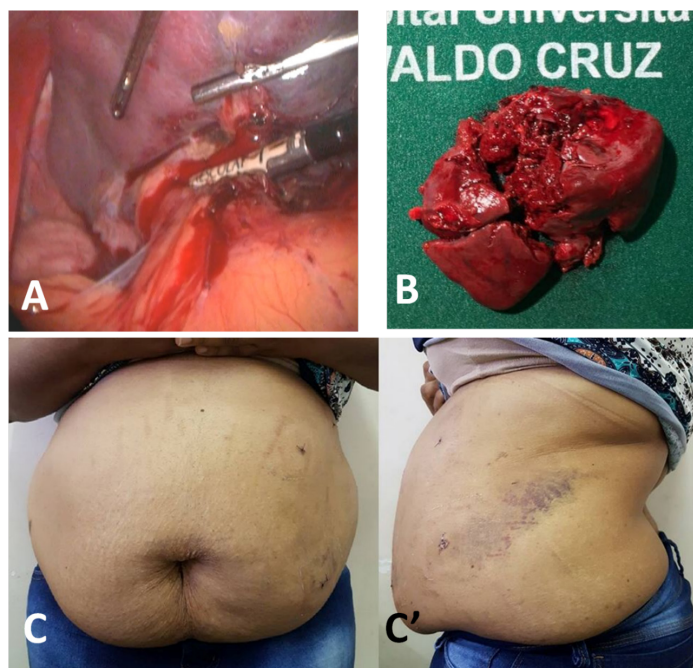
### Surgical Description 1

The surgery was performed with patient in right lateral decubitus position. Two low friction mini-laparoscopic trocars of 3 mm was used in the left right upper quadrant, a 5 mm trocar for the 7 mm vessel sealing forceps was used in the posterior axillary line, and a 11 mm trocar in the umbilical region was used for the optics.

Pneumoperitoneum was performed using the Hasson open technique under direct vision. The first step of the surgery was the dissection to separate the adhesions between the lower pole of the spleen and the splenic flexure of the colon. The vasa previa along the arcade was sealed using a vessel sealing device at the lower pole of the spleen.

This dissection continued superiorly to the upper pole of the spleen and the angle of His. Following the complete ligation of the vasa previa, only the splenic hilum remained as the blood supplier. The splenic hilum was approached and ligated with the vessel sealing device, after the complete mobilization of the spleen. An endobag was used to remove the spleen through umbilical incision.

The surgery was uneventful, with no further complications, and a total surgical time of 45 minutes. The patient was discharged in good clinical condition, three days following the procedure (Figure 1).



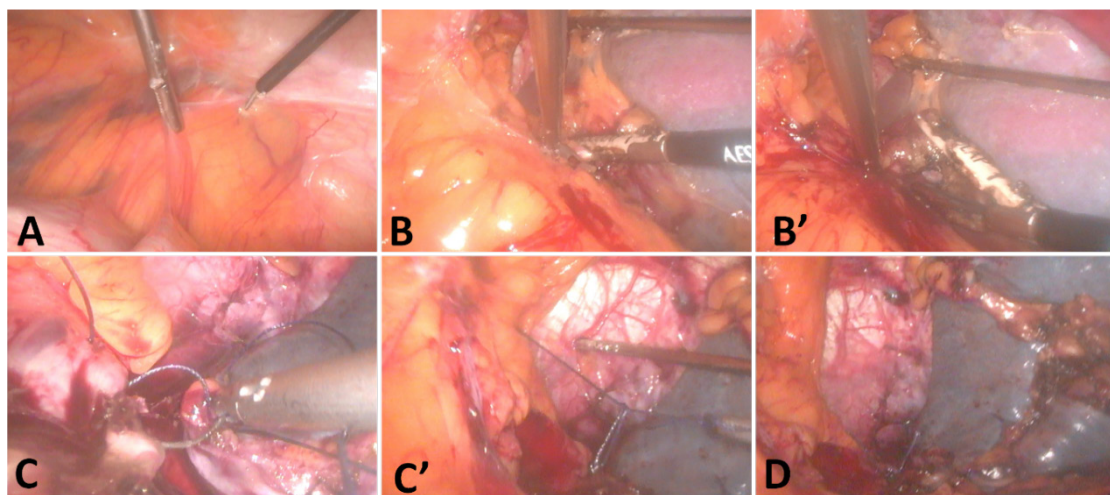
**Figure 1.** A. Minilaparoscopic instruments for spleen handling and vessel sealing device; B. Surgical specimen showing an enlarged spleen, about  $190 \text{ cm}^3$ , with no signs of malignancy; C and C'. Abdomen at discharge (4th postoperative day) showing minimal scars

## CASE REPORT 2

A 61-year old female patient was diagnosed with ITP for about six years, initially presenting with asthenia, purpuric lesions, and thrombocytopenia (15,000/mm<sup>3</sup>). Since then, the Hemotherapy Center had initiated her clinical treatment with corticosteroids, but the patient did not reveal a satisfactory clinical response. She presented episodes of bleeding, and a total, hybrid mini-laparoscopic splenectomy was proposed.

## Surgical Description 2

The procedure was not technically different from the first case. The spleen was enlarged (190 cm<sup>3</sup>), with no visible lesions or the presence of liquids in the cavity. Mini-laparoscopic forceps, for spleen handling, and the vessel sealing device, were used to carefully seal prior vasa previa and the splenic hilum. The surgical specimen was removed through the umbilical scar. During the dissection of the spleen with the vessel sealing device, the heat caused a small lesion in the stomach, which was sutured with the mini-laparoscopic instruments (Figure 2).



**Figure 2.** A. Insertion of the 3-mm minilaparoscopic trocars; B and B'. Resection of the spleen using a 5-mm vessel sealing device and 2 minilaparoscopic graspers; C and C'. Suture of the stomach due to energy lesion; D. Final view of the surgical field and the resected spleen

The surgery had no further complications, and a total surgical time of 60 minutes. The patient was discharged in good clinical condition, four days following the procedure. The anatomopathological study of the piece showed to be a congestive splenic tissue with no signs of malignancy.

## DISCUSSION

The ITP is more prevalent in women of childbearing age, from 15 to 50 years-old, and the presence of purplish and bruised skin/mucous membranes is the most frequent complaint<sup>1</sup>.

Diagnostic investigation should be initiated with a peripheral blood analysis and its diagnosis is made when there is: presence of isolated thrombocytopenia (< 100,000/mm<sup>3</sup>), with no alterations in the other series of the hemogram, and in the peripheral blood smear; and absence of other clinical conditions that occur with thrombocytopenia, such as infections, autoimmune diseases, neoplasia, and adverse drug effects<sup>1,2</sup>. There are several, minimally invasive techniques to perform a splenectomy in patients with ITP: laparoscopy<sup>6</sup>, mini-laparoscopy<sup>7</sup>, and embolization<sup>8,9</sup>.

At our center, the conventional laparoscopic splenectomy is broadly performed. However, we do not possess the possibility of performing a partial embolization of the splenic artery, preoperatively, despite its known advantages in elevating the platelet count and decreasing bleeding during surgery<sup>8,9</sup>. Mini-laparoscopy is not commonly used to perform splenectomies, due to the size of the spleen, which would make the procedure more complicated. In our department, we have one surgical team with large experience in mini-laparoscopic procedures.

Mini-laparoscopy has been largely used in cholecystectomies and inguinal hernia repair<sup>10-13</sup>. Most randomized clinical trials (RCT), comparing mini-laparoscopy to conventional laparoscopy were performed in patients submitted to cholecystectomy, and three systematic reviews were performed<sup>14,15,16</sup>. Mini-laparoscopy showed better aesthetic results when compared to the standard laparoscopic cholecystectomy. Moreover, Sajid et al.<sup>15</sup> and McCloy et al.<sup>14</sup> reported less postoperative pain post a mini-laparoscopic cholecystectomy, when compared to the conventional laparoscopic approach. However, there exist no studies comparing mini-laparoscopic and conventional laparoscopic splenectomies.

When comparing only the technical aspects of the minimally invasive technique, Firme et al.<sup>4</sup> showed that for coarser approaches, conventional 5 mm instruments are preferable; however, for more precise and complex procedures, the low friction offered by 3 mm instruments are better. Besides, due to its smaller size, minilaparoscopy allows a better visualization of the surgical field. Other

more complex procedures have also been described<sup>17-19</sup>.

These cases reports describe successful, minimally invasive surgeries for the treatment of autoimmune thrombocytopenic purpura refractory to corticoid use. The hybrid mini-laparoscopic approach was proven to be a safe and effective method, and it should be included in the surgeon's therapeutic arsenal.

**Author contributions:** *Góes G, Cordeiro RN, Lessa M* - Data collection; *Lima DL, Carvalho GL* - Organizational Mentoring and relevance of the paper, Analysis, search of articles; *Cordeiro RN, Góes G, Lima DL, Lessa M* - Reading and writing; *Cordeiro RN, Góes G, Lima DL* - Text review.

## REFERENCES

- Ozkan MC, Sahin F, Saydam G. Immune thrombocytopenic purpura: new biological therapy of an old disease. *Curr Med Chem.* 2015;22(16):1956-62. doi: 10.2174/0929867322666150319102830.
- Sakamoto K, Nakasone H, Tsurumi S, Sasaki K, Mitani K, Kida M, et al. Prednisone versus high-dose dexamethasone for untreated primary immune thrombocytopenia. A retrospective study of the Japan Hematology & Oncology Clinical Study Group. *J Thromb Thrombolysis.* 2014;37(3):279-86. doi: 10.1007/s11239-013-0939-3.
- Qu Y, Xu J, Jiao C, Cheng Z, Ren S. Long-term outcomes of laparoscopic splenectomy versus open splenectomy for idiopathic thrombocytopenic purpura. *Int Surg.* 2014;99(3):286-90. doi: 10.9738/INTSURG-D-13-00175.1.
- Firme WA, Carvalho GL, Lima DL, Lopes VG de P, Montandon ID, Santos Filho F, et al. Low-friction minilaparoscopy outperforms regular 5-mm and 3-mm instruments for precise tasks. *JLS.* 2015;19(3). doi: 10.4293/JLS.2015.00067.
- Carvalho GL, Góes GHB, Cordeiro RN, Lima DL, Amorim LLL, Furtado RHM. A new hybrid mini-laparoscopic technique for Spigelian hernia. *J Minim Access Surg.* 2018;15(3):253-255. doi: 10.4103/jmas.JMAS\_179\_18.
- Tada K, Ohta M, Saga K, Takayama H, Hirashita T, Endo Y, et al. Long-term outcomes of laparoscopic versus open splenectomy for immune thrombocytopenia. *Surg Today.* 2018;48(2):180-5. doi: 10.1007/s00595-017-1570-2.
- Backus CL, Park AE, Matthews BD, Heniford BT. Mini-laparoscopic splenectomy. *J Laparoendosc Adv Surg Tech A.* 2000;10(5):259-62. doi: 10.1089/lap.2000.10.259.
- Sadamoto Y, Abe Y, Kato K, Nishimura J. Partial splenic embolization as a preoperative treatment for refractory idiopathic thrombocytopenic purpura [abstract]. *Rinsho Ketsueki.* 1998;39(12):1194-6.
- Baú PC, Cavazolla SA, Souza HP, Garicochea B. Preoperative embolization of the splenic artery in patients that underwent splenectomy for immune thrombocytopenic purpura. *Acta Cir Bras.* 2007;22(6):470-3. doi: 10.1590/S0102-86502007000600010.
- Lee P-C, Lai I-R, Yu S-C. Minilaparoscopic (needlescopic) cholecystectomy: a study of 1,011 cases. *Surg Endosc.* 2004;18(10):1480-4. doi: 10.1007/s00464-003-8247-1.
- Suo G, Xu A. Clipless minilaparoscopic cholecystectomy: a study of 1,096 cases. *J Laparoendosc Adv Surg Tech A.* 2013;23(10):849-54. doi: 10.1089/lap.2012.0561.
- Malcher F, Cavazzola LT, Carvalho GL, Araujo GDE, Silva JADCE, Rao P, et al. Minilaparoscopy For Inguinal Hernia Repair. *JLS.* 2016;20(4):pii: e2016.00066. doi: 10.4293/JLS.2016.00066.
- Carvalho GL, Loureiro MP, Bonin EA, Claus CP, Silva FW, Cury AM, et al. Minilaparoscopic technique for inguinal hernia repair combining transabdominal pre-peritoneal and totally extraperitoneal approaches. *JLS.* 2012;16(4):569-75. doi: 10.4293/108680812X13462882737096.
- McCloy R, Randall D, Schug SA, Kehlet H, Simanski C, Bonnet F, et al. Is smaller necessarily better? A systematic review comparing the effects of minilaparoscopic and conventional laparoscopic cholecystectomy on patient outcomes. *Surg Endosc.* 2008;22(12):2541-53. doi: 10.1007/s00464-008-0055-1.
- Sajid MS, Khan MA, Ray K, Cheek E, Baig MK. Needleoscopic versus laparoscopic cholecystectomy: a meta-analysis. *ANZ J Surg.* 2009;79(6):437-42. doi: 10.1111/j.1445-2197.2009.04945.x.
- Gurusamy KS, Vaughan J, Ramamoorthy R, Fusai G, Davidson BR. Miniports versus standard ports for laparoscopic cholecystectomy. *Cochrane Database Syst Rev.* 2013;(8):CD006804. doi: 10.1002/14651858.CD006804.pub3.
- Carvalho GL, Abreu GFS, Lima DL, Góes GHB Type IV Mirizzi syndrome treated with hepaticoduodenostomy and minilaparoscopy. *CRSLS e2016. 00057.* Available from: <http://crslns.sls.org/wp-content/uploads/2016/08/jls103163579001.pdf>.
- de Carvalho GL, de Góes GHB, Furtado RHM, Cordeiro RN, Araújo Lessa M de C. Resection of a giant nonparasitic splenic cyst by minilaparoscopy. *J Minim Access Surg.* 2019;15(1):71-3. doi: 10.4103/jmas.JMAS\_55\_18.
- Carvalho GL, Góes GHB, Furtado RHM, Cordeiro RN, Calheiros EMQ. Resection of giant hepatic cyst by hybrid minilaparoscopy. *J Minim Access Surg.* 2019;15(2):167-9. doi: 10.4103/jmas.JMAS\_68\_18.

Received: September 21, 2018.

Accepted: October 29, 2019.