

## Factors associated with increased atrial septum thickness in infants with Hypoplastic Left Heart Syndrome (HLHS): implication for percutaneous septostomy

### *Fatores associados ao aumento da espessura do septo atrial em lactentes com Síndrome da Hipoplasia do Coração Esquerdo (SHCE): implicações para septostomia percutânea*

Bárbara Justo Carvalho<sup>1</sup>, Vera Demarchi Aiello<sup>2</sup>

Carvalho BJ, Aiello VD. Factors associated with increased atrial septum thickness in infants with Hypoplastic Left Heart Syndrome (HLHS): implication for percutaneous septostomy / *Fatores associados ao aumento da espessura do septo atrial em lactentes com Síndrome da Hipoplasia do Coração Esquerdo (SHCE): implicações para septostomia percutânea*. Rev Med (São Paulo). 2020 Jan.-Feb;99(1):80-3.

**RESUMO:** *Introdução:* Nos procedimentos usualmente realizados em recém-nascidos acometidos pela Síndrome da Hipoplasia do Coração Esquerdo (SHCE), variações fenotípicas influenciam o sucesso do tratamento, principalmente as características relacionadas ao septo atrial e ao forame oval (FO) no caso de septostomia por cateter. *Objetivos:* Analisar características macroscópicas do septo atrial de corações com SHCE, a fim de definir e orientar procedimentos terapêuticos nessa estrutura. *Métodos:* Foram avaliados 18 corações de pacientes falecidos e diagnosticados com SHCE quanto à perviedade e tamanho do FO, abaulamento da lâmina, atresia ou perviedade da válvula mitral e calibre da aorta ascendente e tronco pulmonar. Cortes histológicos do septo atrial foram feitos para medidas da espessura máxima e mínima da lâmina. *Resultados:* A idade média dos pacientes foi de 34,5 dias (57% do sexo masculino), com espessura do septo atrial médio de 1,90 mm (0,63 - 4,09 mm). O diâmetro médio do tronco e da aorta pulmonar foi de 1,16 cm e 0,22 cm, respectivamente. O FO era patente em 39% dos casos. A valva mitral era atrésica em 21% das amostras. Houve diferença significativa na espessura do septo atrial nos casos com FO patente ou fechada, sendo maior nos casos em que a FO era fechada ( $p = 0,047$ ). A relação FO / idade apresentou correlação negativa estatisticamente significativa com a espessura do septo atrial ( $r = -0,76$  e  $p < 0,05$ ). *Conclusões:* Os resultados indicam que a perviedade e o tamanho do forame oval têm repercussões na espessura do septo atrial, sugerindo que esse fator pode limitar o sucesso de intervenções terapêuticas, principalmente na septostomia por cateter.

**Descritores:** Cardopatias congênitas; Comunicação interatrial; Forame oval.

**ABSTRACT:** *Introduction:* In the usual procedures performed on newborns affect by Hypoplastic Left Heart Syndrome (HLHS), phenotypic variations influence the success of the treatment, especially the characteristics related to the atrial septum and foramen ovale (FO) in case of catheter septostomy. *Objectives:* To analyze macroscopic features of the atrial septum of hearts with HLHS in order to define and guide therapeutic procedures on this structure. *Methods:* 18 hearts of deceased patients diagnosed with HLHS were evaluated for FO patency and size, bulging of its blade, atresia or patency of the mitral valve and caliber of the ascending aorta and pulmonary trunk. Histological sections of the atrial septum were made for measurements of maximum and minimum thickness of the lamina. *Results:* The mean age of the patients was 34.5 days (57% male), with a mean atrial septal thickness of 1.90 mm (0.63 - 4.09 mm). The mean diameter of the pulmonary trunk and aorta were 1.16 cm and 0.22 cm, respectively. FO was patent in 39% of cases. The mitral valve was atresic in 21% of the specimens. There was a significant difference in the thickness of the atrial septum in cases with patent or closed FO, being greater in cases where the FO was closed ( $p = 0.047$ ). The ratio FO/age presented a statistically significant negative correlation with atrial septum thickness ( $r = -0.76$  and  $p < 0.05$ ). *Conclusions:* The results indicate that the patency and size of the oval foramen have repercussions on the thickness of the atrial septum, suggesting that this factor may limit the success of therapeutic interventions, especially catheter septostomy.

**Keywords:** Heart defects, congenital; Heart septal defects, atrial; Foramen ovale.

Presented at XXXVIII COMU - Panels Awards - Surgical Area, October 5th, 2019.

1. Faculdade de Medicina da Universidade de São Paulo (FMUSP). Acadêmica de Medicina. ORCID: <https://orcid.org/0000-0002-7599-6610>. Email: [barbara.justo@fm.usp.br](mailto:barbara.justo@fm.usp.br).

2. Instituto do Coração do Hospital das Clínicas da Faculdade de Medicina da Universidade de São Paulo (InCor - HCFMUSP). Professora doutora, ORCID: <https://orcid.org/000-0002-4185-9423>. Email: [anpvera@incor.usp.br](mailto:anpvera@incor.usp.br).

**Correspondent author:** Bárbara Justo Carvalho. Address: Rua Cardeal Arcoverde, 364 - Pinheiros, São Paulo - SP. email: [barbara.justo@fm.usp.br](mailto:barbara.justo@fm.usp.br).

## INTRODUCTION

### Hypoplastic Left Heart Syndrome

The Hypoplastic Left Heart Syndrome (HLHS) encompasses a spectrum of cardiac malformations related to the poor development of left heart elements (such as the mitral valve and the left ventricle cavity) and the aorta, with the possibility of occurrence of atresia, stenosis and hypoplasia of these structures<sup>1</sup>. In the United Kingdom, one case of HLHS is reported for every 5,000 live births (150 children born with the condition per year), corresponding to 2 to 3% of all children with congenital heart disease<sup>2</sup>. In Canada, the condition is prevalent in 0.016% of live births<sup>3</sup>. However, despite the low incidence, the malformation accounts for 25% to 40% of cardiac deaths in the first week of life<sup>2</sup>.

The syndrome, introduced by Noonan and Nadas in 1958<sup>4</sup>, occurs at various levels of complexity and in the form of various cardiac phenotypes which have as their common characteristic an inability to generate adequate blood flow for systemic circulation. In addition, the presence or absence of patent ductus arteriosus and foramen ovale may influence the symptomatology and severity of the disease: in cases where both are closed, cyanosis and tachypnea are very evident due to the rapid venous pulmonary congestion, since underdevelopment of the left ventricle and/or aorta makes it impossible to receive adequate pulmonary flow and to send it to the great circulation, which may be incompatible with life. Even in cases where both structures mentioned are patent, increased pulmonary flow may also lead to congestion, with consequent tachypnea, respiratory acidosis, cyanosis, cardiac congestion, cardio and hepatomegaly and circulatory collapse<sup>2</sup>. In the observation of these symptoms, the postnatal diagnosis can be made through the echocardiogram, and it is possible to perform the prenatal diagnosis by the same method in the second trimester<sup>2,3</sup>. In view of this, the systemic circulation can be totally or partially dependent on the right ventricle. However, in order to make it possible for the right ventricle to promote systemic circulation in postnatal life and thus to keep the newborn alive until it is mature enough to perform the definitive surgical procedures, it is necessary the use of certain techniques, such as balloon atrial septostomy and the pharmacological or mechanical manipulation of the ductus arteriosus (with prostaglandins and stents, respectively).

### Balloon atrial septostomy

The procedure, first described in 1966 by Rashkind and Miller<sup>9</sup>, is a palliative treatment widely used in cyanogenic congenital heart diseases. In the 1980s, it was carried out at the bedside with echocardiogram, without exposure to radiation, costs and risks of injury

compared to the way it was done previously (with uni/biplanar fluoroscopy in a hemodynamic laboratory)<sup>10,11</sup>. The technique consists of catheterization of the right or left femoral vein with a guidewire that leads the catheter to the left atrium through the right atrium and foramen ovale. The balloon is then inflated with saline solution and drawn abruptly against the atrial septum, causing its rupture<sup>11</sup>.

However, even with interventions such as catheterization or surgeries, in cases with inadequate atrial septal defect (such as intact atrial septum or restrictive atrial septum), a high mortality rate of 50-65% persists<sup>12</sup>. Among the associated causes are damage to the parenchyma and pulmonary vessels due to high pressure in the left ventricle, such as edema, lymphangiectasia and increased pulmonary vascular resistance<sup>7</sup>. In order to avoid such damages, studies are being carried out to investigate the efficacy of these procedures in the prenatal phase, not with better results: the largest one (n = 21) involving atrial septostomy had a survival rate of just over half of fetuses (52%)<sup>13</sup>.

In view of the significant diversity of these septal anatomical variations related to HLHS and its influence on the survival of the newborns even after procedures that allow survival, it is necessary to study the morphology of specific anatomical aspects of these hearts in order to verify possible causes and origins for the difficulties found in therapy.

## OBJECTIVES

The purpose of the project is to study hearts with HLHS to analyze macroscopic features of the atrial septum in order to define and guide therapeutic procedures on this structure, correlating them with other aspects normally altered in this syndrome, such as the morphology of the heart valves.

## METHODS

This study used a collection of 18 hearts diagnosed with HLHS belonging to the collection of the Laboratory of Pathological Anatomy of the *Instituto do Coração do Hospital das Clínicas da Faculdade de Medicina de São Paulo*. The exclusion criteria were poor preservation of the anatomical specimen and atrial septum resection.

The atrial septum were evaluated for the presence of patency of the foramen ovale, bulging of its lamina to one or other atrial cavity, presence of septal defects and displacement to the left of its insertion. The foramen ovale were measured by means of a calibrated explorer and other morphological features such as atresia or aortic and mitral valve stenosis, patency of the ductus arteriosus and ascending aorta were recorded.

A resection of the atrial septum were performed, with parallel transverse sections identified topographically from the most posterolateral to the most anterior. The

obtained fragments were submitted to conventional histological processing and then to histological sections of 5 micrometers thickness. The sections were stained by hematoxylin-eosin.

Comparisons of quantitative variables between groups were processed by mean tests (Student's t-distribution or Mann-Whitney test, according to the distribution of the data). In order to verify possible correlations between variables, the Pearson or Spearman coefficients were calculated. To evaluate associations, a Chi-square test were

performed. The significance level adopted in this study was 5% ( $p < 0.05$ ).

**RESULTS**

The mean age was 34.5 days, with 57% of male patients. Table 1 shows the mean, highest, lowest and median values for age, atrial septum thickness, aorta diameter, pulmonary trunk diameter and foramen ovale.

**Table 1** - Mean, median, higher and lower bounds of age, atrial septum thickness and aorta, pulmonary trunk and foramen ovale diameter

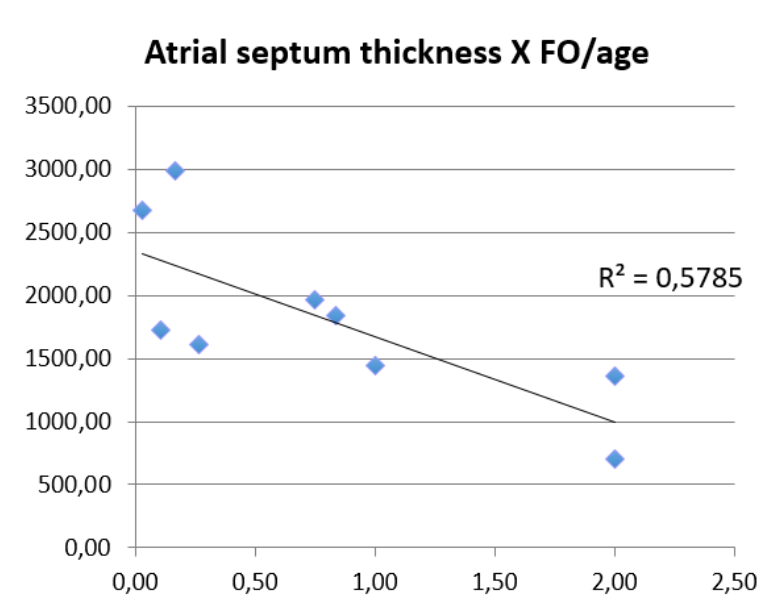
|                               | Mean | Median | Higher bound | Lower bound |
|-------------------------------|------|--------|--------------|-------------|
| Age (days)                    | 34.5 | 8      | 270          | 1           |
| Atrial septum thickness (mm)  | 1.9  | 1.74   | 4.09         | 0.63        |
| Aorta diameter (cm)           | 0.22 | 0.2    | 0.4          | 0.1         |
| Pulmonary trunk diameter (cm) | 1.16 | 1.1    | 1.8          | 0.8         |
| Foramen ovale diameter (mm)   | 4,4  | 5      | 8            | 4           |

The mitral valve was atresic in 21% of the cases, with valve hypoplasia in the remaining cases, and the both features (atresic and hypoplastic valves) did not have significant statistical correlation with other anatomical features.

Foramen ovale was patent in 39% of the cases, with lamina deviation to one side in half of the cases and most deviations to the right (66.7% of the bulged laminae). A statistically significant correlation was found between atrial septal thickness and foramen ovale patency, so that the closed septa were thicker than those with patent foramen ovale ( $p = 0.047$ ).

When analyzing the statistical correlation between age and thickness of the atrial septum, a positive correlation was found, but without significant character. The same happened between the foramen ovale diameter and atrial septum thickness, but with a negative correlation. In order to reduce the effect of the patient's age on atrial septal thickness, the FO / age variable was created, relating the patient's foramen ovale diameter to age. This variable also showed a significant statistical correlation with thickness ( $p < 0.05$ ,  $r = -0.76$ ), being higher in patients with smaller foramen ovale (Graph 1).

**Graph 1** - Correlation between atrial septum thickness (mm) and FO / age variable



## DISCUSSION

In the analysis of the studied anatomical features, correlation was found between patency/diameter of the foramen ovale and the thickness of the atrial septum, with thicker septa in cases where the foramen ovale was not patent or small. Thus, it is possible to relate the thickness of the atrial septum with the restrictive condition of the foramen ovale, a feature with important long and short-term prognostic value which offers greater difficulty in septostomy procedure<sup>14</sup>.

The remaining studied anatomical features showed no correlation with each other, neither with atrial septal thickness or foramen ovale morphology. These results are possibly related to the sample size, which did not allow broader and multivariate analyzes in order to better identify the existence of other possible associations.

**Acknowledgments:** This work was supported by Fundação de Amparo à Pesquisa do Estado de São Paulo (FAPESP) – process 2018/14607-8.

## REFERENCES

1. Tchervenkov CI, Jacobs JP, Weinberg PM, Aiello VD, Béland MJ, Colan SD, Elliott MJ, Franklin RC, Gaynor JW, Krogmann ON, Kurosawa H, Maruszewski B, Stellin G. The nomenclature, definition and classification of hypoplastic left heart syndrome. *Cardiol Young*. 2006;16(4):339-68. doi: 10.1017/S1047951106000291.
2. Mussa S, Barron DJ. Hypoplastic left heart syndrome. *Paediatr Child Health*. 2017;27(2):75-82. doi: <https://doi.org/10.1016/j.paed.2016.12.002>.
3. Morris CD, Outcalt J, Menashe VD. Hypoplastic left heart syndrome: natural history in a geographically defined population. *Pediatrics*. 1990;85(6):977-83.
4. Noonan JA, Nadas AS. The hypoplastic left heart syndrome; an analysis of 101 cases. *Pediatr Clin North Am*. 1958;5(4):1029-56. doi: 10.1016/s0031-3955(16)30727-1.
5. Clausen H. Hypoplastic left heart syndrome. *Paediatr Child Health*. 2015;25(1):18-22. doi: <https://doi.org/10.1016/j.paed.2014.07.006>
6. Tatani SB. Ecocardiografia fetal: apresentando o método. *Arq Bras Cardiol*. 1997;69(3):197-201. <http://dx.doi.org/10.1590/S0066-782X1997000900011>.
7. Rychik J, Rome JJ, Collins MH, DeCampli WM, Spray TL. The hypoplastic left heart syndrome with intact atrial septum: atrial morphology, pulmonary vascular histopathology and outcome. *J Am Coll Cardiol*. 1999;34(2):554-60. doi: 10.1016/s0735-1097(99)00225-9.
8. Lowenthal A, Kipps AK, Brook MM, Meadows J, Azakie A, Moon-Grady AJ. Prenatal diagnosis of atrial restriction in hypoplastic left heart syndrome is associated with decreased 2-year survival. *Prenat Diagn*. 2012;32(5):485-90. doi:10.1002/pd.3850.
9. Rashkind WJ, Miller WW. Creation of an atrial septal defect without thoracotomy. A palliative approach to complete transposition of the great arteries. *JAMA*. 1966;196(11):991-2. doi: 10.1001/jama.1966.03100240125026.
10. Perry LW, Ruckman RN, Galioto FM Jr, Shapiro SR, Potter BM, Scott LP 3rd. Echocardiographically assisted balloon atrial septostomy. *Pediatrics*. 1982;70(3):403-8.
11. Lopes LM, Kawano C, Cristovão SAB, Nagamatsu CT, Fonseca L, Furlaneto BHS, Furlaneto G, Silva JP, Mangione JA. Atriosseptostomia por cateter balão guiada pela ecocardiografia em unidade de terapia intensiva neonatal. *Arq Bras Cardiol*. 2010;95(2):153-8. <http://dx.doi.org/10.1590/S0066-782X2010005000076>.
12. Herberg U, Berg C, Geipel A, Gembruch U, Breuer J. Foetal therapy: what works? Closed interatrial septum. *Cardiol Young*. 2014;24(Suppl 2):47-54. doi: 10.1017/S104795111400122X.
13. Marshall AC, Levine J, Morash D, Silva V, Lock JE, Benson CB, Wilkins-Haug LE, McElhinney DB, Tworetzky W. Results of in utero atrial septoplasty in fetuses with hypoplastic left heart syndrome. *Prenat Diagn*. 2008;28(11):1023-8. doi: 10.1002/pd.2114.
14. Hoque T, Richmond M, Vincent JA, Bacha E, Torres A. Current outcomes of hypoplastic left heart syndrome with restrictive atrial septum: a single-center experience. *Pediatr Cardiol*. 2013;34(5):1181-9. doi: 10.1007/s00246-012-0625-9.

Received: 2019 October 21

Accepted: 2019 October 21