

Case Report

Association of Hirschsprung's disease and Ladd's band in a newborn*Associação de doença de Hirschsprung e brida de Ladd em um neonato*

**Rúbria Liziero Picoli¹, Victor de Amorim Campos², Juliane Feitosa de Bezerra Gusmão³,
Alessandra dos Santos Domingues⁴**

Picoli RL, Campos VA, Bezerra JF, Domingues AS. *Association of Hirschsprung's disease and Ladd's band in a newborn / Associação de doença de Hirschsprung e brida de Ladd em um neonato*. Rev Med (São Paulo). 2022 Sept-Oct;101(5):e-165550.

ABSTRACT: Introduction: Hirschsprung's disease, also known as congenital megacolon, presents alterations in the distal enteric innervation. During the neonatal period, it presents through the classical triad of vomiting, abdominal distension and delayed meconium elimination. Objective: To describe clinical case of a male patient diagnosed with congenital megacolon, whose initial presentation was neonatal intestinal obstruction attributed to congenital adhesion bands and intestinal malrotation and Hirschsprung's disease. Comments: Although it is a congenital disease, the diagnosis does not always occur during the neonatal period and should be considered in the diagnostic reasoning of older patients with a history of constipation refractory to treatment. Approximately 20% of children have negative outcomes on the postoperative course, with constipation being the most common complaint, tending to improve over the years. No association was found in the literature with congenital band, intestinal malrotation and Hirschsprung's disease.

Keywords: Hirschsprung disease; Congenital abnormalities; Constipation; Intestinal obstruction.

RESUMO: *Introdução:* A doença de Hirschsprung, também conhecida como megacólon congênito, apresenta alterações na inervação entérica distal. Durante o período neonatal, apresenta-se através da tríade clássica de vômitos, distensão abdominal e atraso na eliminação meconial. *Objetivo:* Descrever quadro clínico de paciente do sexo masculino diagnosticado com megacólon congênito, brida congênita e má rotação intestinal. *Comentário:* Embora seja uma doença congênita, nem sempre o diagnóstico ocorre durante o período neonatal, devendo ser cogitada no raciocínio diagnóstico de pacientes mais velhos com história de constipação refratária ao tratamento. Aproximadamente 20% das crianças tem evolução pós-cirúrgica ruim, sendo a constipação a queixa mais comum, tendendo a melhorar com o passar dos anos. Não foi encontrado na literatura a associação de bridas congênitas, má rotação intestinal e doença de Hirschsprung.

Palavras-chave: Doença de Hirschsprung; Anormalidades congênitas; Constipação intestinal; Obstrução intestinal.

1. University of Brasilia, Faculty of Medicine, Department of Child and Adolescent Health. <https://orcid.org/0000-0001-5027-1982>. E-mail: rubriapicoli@gmail.com.
2. University of Brasilia, Faculty of Medicine, Department of Child and Adolescent Health. <https://orcid.org/0000-0001-6592-7032>. E-mail: victor_amorim@hotmail.com.
3. Brasilia University Hospital, Department of Child and Adolescent Health. <https://orcid.org/0000-0002-0849-7360>. E-mail: juliane.feitosa@hotmail.com.
4. University of Brasilia, Faculty of Medicine, Department of Child and Adolescent Health. <https://orcid.org/0000-0002-1722-417X>. E-mail: alessandra_gastro@hotmail.com

Correspondence: Rúbria Liziero Picoli. Hospital Universitário de Brasília – HUB/UnB. Setor de Grandes Áreas Norte 605 - Asa Norte, Unidade de Neonatologia. Brasília, DF, Brasil. CEP: 70840-901. E-mail: rubriapicoli@gmail.com

INTRODUCTION

Hirschsprung's disease, also known as congenital megacolon or intestinal aganglionosis, presents as alterations in the distal enteric innervation, characterized by the absence of ganglion cells in the submucosal and muscular layers¹, generally affecting the rectosigmoid region². The incidence varies from 1.5 to 2.8 per 10,000 births³, with a predominance in males and may be associated with genetic syndromes and congenital anomalies^{3,4}.

During the neonatal period, it is presented as the classic triad of vomiting, abdominal distension and delayed meconium elimination⁵, due to mechanical obstruction caused by the difficulty of relaxation during peristalsis⁶.

The gold standard diagnostic test is colon biopsy, which can be performed by suction or surgery, to acquire a sample of mucosal muscle tissue. The tissue removed is preferably evaluated by the acetylcholinesterase method, which has a specificity of 100% and a sensitivity of 91%⁷.

Anorectal manometry can be performed to assess the rectoanal inhibitory reflex⁸ and radiological assessment of colonic transit with radiopaque markers and barium contrast enema, to assess the motor function of the colon and rectum and also the presence of the transition zone between area with ganglion cells and the area with absent ganglion cells⁹. Treatment consists of resection of the aganglionic segment¹⁰.

Congenital adhesion bands, also known as Ladd's bands, are a rare condition, specific to childhood and a consequence of intestinal malrotation, which have symptoms of intestinal obstruction.

The present report illustrates a case of congenital

megacolon in an infant, with an initial presentation of neonatal intestinal obstruction attributed to congenital adhesion bands and intestinal malrotation that evolved with constipation, triggering a new investigation and diagnostic elucidation of Hirschsprung's disease.

CASE REPORT

Preterm newborn 32 weeks and 5 days, eutocyte, male, child of a lupus mother, with increased neonatal infectious risk due to premature rupture of membranes. The patient evolved without meconium elimination and multiple episodes of vomiting on the first day of life. A radiological evaluation was performed, which showed intestinal dilatation and absence of gas in the rectal ampulla, being diagnosed with intestinal obstruction. At three days of age, he was submitted to exploratory laparotomy, and the congenital bands were identified and resected (Ladd's bands) and the intestinal malrotation found was undone. The histological analysis of the surgical specimen was negative for aganglionic megacolon.

At ten days of age, the patient developed a new intestinal obstruction due to adhesions, and a double-mouth jejunostomy was performed. The patient had a satisfactory initial evolution, however, with evacuations only with rectal stimulation, three days after the surgery. During investigation of the condition, a barium enema was performed, which showed persistence of contrast material in the colon and distention of the left hemicolon even 24 hours after contrast administration through the distal jejunostomy (Figure 1). Reconstruction of the intestinal transit was performed 20 days later, evolving without interferences in the immediate postoperative period.

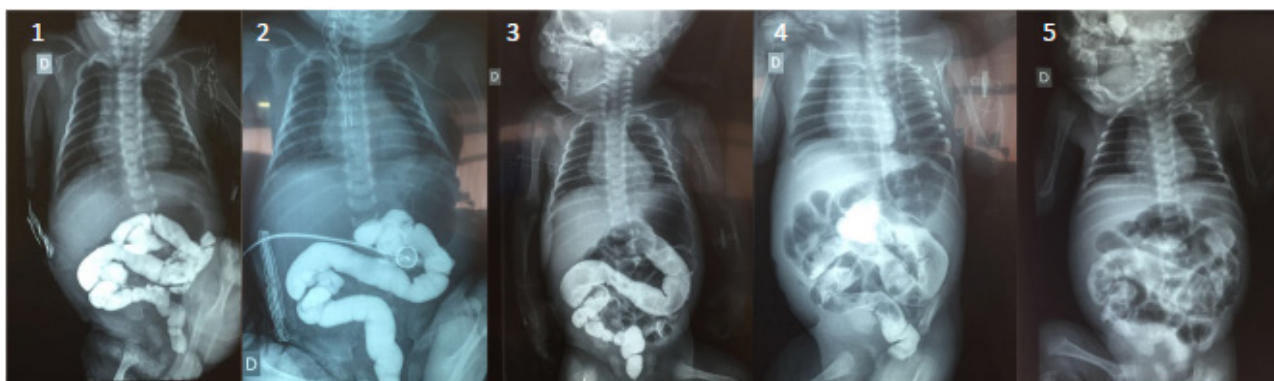


Figure 1: Sequence of evaluation of contrast emission: 1) fifteen hours after infusion; 2) one day after infusion; 3) three days after infusion; 4) eight days after infusion; 5) thirteen days after infusion

At eight months of age, a rectal biopsy was performed by laparotomy, which showed the absence of ganglion cells in the myenteric plexuses, corroborating the diagnosis of Hirschsprung's disease (Figure 2A).

At one year of life, colostomy and colonic biopsy were scheduled, however, the patient evolved with

ventilatory and hemodynamic decompensation in the initial perioperative period, and only the sigmoid loop colostomy was performed. After four months, he evolved with a new condition of obstructive acute abdomen, performed a new exploratory laparotomy with the finding of adhesions and suffering of intestinal loops. The surgical

team opted for a 25 cm jejunal enterectomy and end-to-end enteroanastomosis. Rectosigmoid junction biopsy confirmed a diagnosis of Hirschsprung's disease (Figures

2B and 2C). Reconstruction of the intestinal transit was performed at two years and one month of age.

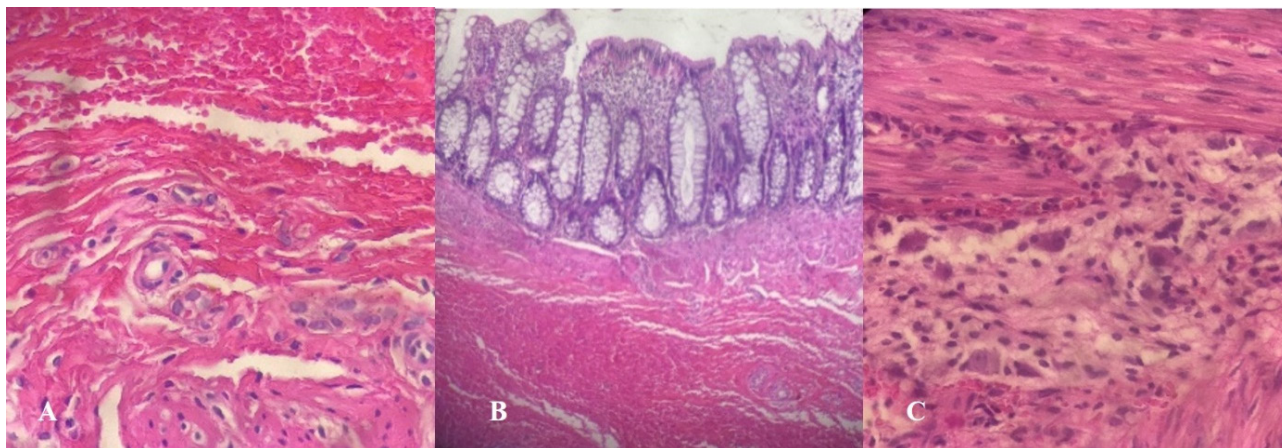


Figure 2: A) Photomicrograph of histological section of the rectum with absence of ganglion cells. (Hematoxylin – eosin staining, A – high magnification); B) Photomicrograph of histological section of rectosigmoid with absence of ganglion cells. (Hematoxylin – eosin staining, medium magnification); C) Photomicrograph of histological section of a jejunum segment with the presence of ganglion cells in the myenteric plexus (Hematoxylin-eosin staining, high magnification)

DISCUSSION

Congenital megacolon has an acute abdomen neonatal presentation¹³. With the primary diagnosis of intestinal obstruction, differential diagnoses in that age group should be considered; of mechanical etiology such as intestinal atresias, rotation vices, stenosis, congenital bands and also other functional causes such as meconium ileus, left colon syndrome and meconium plug syndrome¹⁴.

It is noteworthy that congenital bands are of embryological origin¹¹ and can occur in intestinal rotation anomalies, causing inadequate fixation of the intestine to the abdominal wall¹². Intestinal malrotation affects 1 in 500 live births¹², with 5% of those affected having intestinal obstruction produced by the bands¹⁵. Urgent surgery is the treatment of choice, given the risk of intestinal necrosis¹². In the present report, laparotomy was diagnostic and therapeutic and the patient still presented typical complications such as adhesions and perforation, requiring new approaches and jejunostomy construction.

The clinical evolution of constipation in Hirschsprung's disease after the neonatal period was seen in a retrospective study of a Korean hospital, affecting 68.7% of patients¹⁶ and in a Brazilian study, 73.6%¹¹. On the other hand, abdominal distension in 64.2% and 83%, respectively^{11,16}.

The diagnostic investigation of the patient with constipation that was refractory to conventional treatment was followed by a barium enema, which showed irregular contractions and colonic dilatation (Figure 1).

According to the literature, the test has a sensitivity of around 80% and a specificity of up to 100%⁴. Rectal

biopsy is the gold standard technique for diagnosis, and demonstrates the absence of ganglion cells and an increase in unmyelinated cholinergic nerve fibers in the submucosa and between the muscle layers.⁴

In our case, barium enema was the driver for the need for rectal biopsy, which confirmed the diagnosis of Hirschsprung's disease.

The most commonly used surgical technique is the modified Duhamel technique, but the basic principle involves resection of the affected colonic segment with anastomosis between the healthy intestine and the anus, aiming to maintain sphincter function. In severely affected patients, an initial colostomy bag with subsequent colorectal anastomosis may be necessary¹⁰.

Approximately 20% of children have a poor post-surgical course¹⁷, with constipation being the most common complaint, tending to improve over the years¹⁸. Another common complication is fecal incontinence, which affects 15 to 85% of treated children, affecting the patients' quality of life by decreasing self-esteem and socialization¹⁹.

CONCLUSION

This case illustrates the importance of reviewing previous diagnoses and emphasizes the need for neonatologists, surgeons, pediatricians and pediatric gastroenterologists to know the presentations of Hirschsprung's disease according to age group, aiming at early diagnosis and treatment. Although it is a congenital disease, the diagnosis is not always made during the neonatal period, and it should be considered

in the diagnostic reasoning of older patients with a history of constipation that is refractory to treatment. No

association of congenital bands, intestinal malrotation and Hirschsprung's disease was found in the literature.

REFERENCES

- Martins MR, Santos CHM, Falcão GR. Late diagnosis of Hirschsprung's disease. *J Coloproctol.* 2015;35(3):178-81. <http://dx.doi.org/10.1016/j.jcol.2015.02.009>
- Caserta NMG, Pacheco EMB, Silva MJG, Miyabara S, Pereira RM. Aganglionose total do colón: aspectos radiológicos. *Radiol Bras.* 2004;37(3):227-29. <http://dx.doi.org/10.1590/S0100-39842004000300018>
- Tam PK. Hirschsprung's disease: a bridge for science and surgery. *J Pediatr Surg.* 2016;51:18-22. <https://doi.org/10.1016/j.jpedsurg.2015.10.021>
- Haricharan RN, Georgeson KE. Hirschsprung disease. *Semin Pediatr Surg.* 2008;17:266-75. <https://doi.org/10.1053/j.sempedsurg.2008.07.005>
- Bradnock TJ, Knight M, Kenny S, Nair M, Walker G M. Hirschsprung's disease in the UK and Ireland: incidence and anomalies. *Arch Dis Child.* 2017;102:722-27. <https://doi.org/10.1136/archdischild-2016-311872>
- Lin YC. Nationwide Population-based epidemiologic study of Hirschsprung's disease in Taiwan. *Pediatr Neonatol.* 2016;57:165-66. <https://doi.org/10.1016/j.pedneo.2016.03.002>
- Martucciello G, Pini Prato A, Puri P, Holschneider AM, Meier-Ruge W, Jasonni V, et al. Controversies concerning diagnostic guidelines for anomalies of the enteric nervous system: a report from the fourth International Symposium on Hirschsprung's disease and related neurocristopathies. *J Pediatr Surg.* 2005;40(10):1527-31. <https://doi.org/10.1016/j.jpedsurg.2005.07.053>
- Huang Y, Zheng S, Xiao X. Preliminary evaluation of anorectal manometry in diagnosing Hirschsprung's disease in neonates. *Pediatr Surg Int.* 2009;25(1):41-5. <https://doi.org/10.1007/s00383-008-2293-7>
- Jamieson DH, Dundas SE, Belushi SA, Cooper M, Blair GK. Does the transition zone reliably delineate aganglionic bowel in Hirschsprung's disease? *Pediatr Radiol.* 2004;34(10):811-5. <https://doi.org/10.1007/s00247-004-1292-7>
- Carvalho ER, Silva LF, Ferreira CT; Gastroenterologia e nutrição em pediatria. Barueri, SP: Manole; 2012. p.466-511.
- Yang KH, Lee TB, Lee SH, Kim SH, Cho YH, Kim HY. Congenital adhesion band causing small bowel obstruction: What's the difference in various age groups, pediatric and adult patients? *BMC Surg.* 2016;16:79. <https://doi.org/10.1186/s12893-016-0196-4>
- Bigélli RHM, Fernandes MIM, Galvão LC, Sawamura R. Estudo retrospectivo de 53 crianças com doença de Hirschsprung: achados clínicos e laboratoriais. *Medicina.* 2002;35:78-84. <https://doi.org/10.11606/issn.2176-7262.v35i1p78-84>
- Devesa H, Lima B, Martins A, Ferreira M, Vasconcelos E, Torres R, et al. Obstrução intestinal alta por bandas de Ladd. *Rev Portuguesa Cir.* 2015;34:49-54. <https://revista.spcir.com/index.php/spcir/article/view/544>
- Durante AP, Baratella JRS, Velhote MCP, Hercowitz B, Napolitano-Neto P, Salgado-Filho H, et al. Obstrução intestinal neonatal: diagnóstico e tratamento. Projeto Diretrizes; 2005. Disponível em: https://diretrizes.amb.org.br/_BibliotecaAntiga/obstrucaoo-intestinal-neonatal-diagnostico-e-tratamento.pdf
- Buonomo KDRC. Radiología pediátrica. 3a ed. Madrid: Marban; 2000. p. 856-865.
- Jung PM. Hirschsprung's disease: one surgeon's experience in one institution. *J Pediatr Surg.* 1995;130(5):646-651. [https://doi.org/10.1016/0022-3468\(95\)90680-0](https://doi.org/10.1016/0022-3468(95)90680-0)
- Wang JS, Lee HC, Huang FY, Chang PY, Sheu JC. Unexpected mortality in pediatric patients with postoperative Hirschsprung's disease. *Pediatr Surg Int.* 2004;20(7):525-8. <https://doi.org/10.1007/s00383-004-1213-8>
- Hyman PE. Defecation disorders after surgery for Hirschsprung's disease. *J Pediatr Gastroenterol Nutr.* 2005;41(1):62-3. <https://doi.org/10.1097/01.scs.0000180310.47793.91>
- Mills JL, Konkin DE, Milner R, Penner JG, Langer M, Webber EM. Long-term bowel function and quality of life in children with Hirschsprung's disease. *J Pediatr Surg.* 2008;43(5). <https://doi.org/899-905.10.1016/j.jpedsurg.2007.12.038>

Received: January 09, 2020

Accepted: July 07, 2022