

## Case Report

**Chronic groin pain, are we aware of this complication?***Dor crônica inguinal, estamos atentos a essa complicação?*

**Paulo Henrique Fogaça de Barros<sup>1</sup>, Caroline Petersen da Costa Ferreira<sup>2</sup>, Bruno de Lucia Hernani<sup>3</sup>, Camila Scivoletto Borges<sup>4</sup>, Iron Pires de Abreu Neto<sup>5</sup>, João Nathanael Lima Torres<sup>6</sup>, Marcus Vinicius Figueiredo Lourenço<sup>7</sup>, Luciano Tastaldi<sup>8</sup>**

Barros PHF, Ferreira CPC, Hernani BL, Borges CS, Abreu IP, Torres JNL, Lourenço MVF, Tastaldi L. Chronic groin pain, are we aware of this complication? / *Dor crônica inguinal, estamos atentos a essa complicação?* Rev Med (São Paulo). 2022 Jan-Feb;101(1):1-5.

**ABSTRACT:** Inguinal hernia (IH) surgery is one of the most common procedures in the practice of the general surgeon. With adoption of tension-free technique and synthetic mesh implantation, recurrence rates decreased and recurrence is no longer the main late complication after IH repair. Currently, the main late postoperative complication of IH repair is chronic postoperative inguinal pain (CPIP). CPIP is defined as postoperative pain in the inguinal region persisting 3-6 months after surgery. We report the case of a young male patient who presented with CPIP after having undergone two inguinal hernia repairs. Initially, he had left inguinal pain without evident bulging and underwent left inguinal herniorrhaphy using the Lichtenstein technique. There was no relief of pain after surgery. After 1 year, he underwent surgery again, this time bilaterally and unfortunately the pain got worse. He had predominantly neuropathic pain (burning and irradiated to the testicular region bilaterally) and moderate intensity (visual analogue scale 6) refractory to medical management. He had hyperesthesia on the territory of the genitofemoral, iliohypogastric and ilioinguinal nerves on the left side and hypoesthesia in the territory of the three nerves on the right side. A local anesthetic inguinal block provided temporary relief. We performed a bilateral triple neurectomy with removal of the polypropylene mesh. Followed up one year after surgical treatment, the patient remains without inguinal pain.

**Keywords:** Chronic pain; Inguinal hernia; Lichtenstein technique.

**RESUMO:** A cirurgia de hérnia inguinal (HI) é um dos procedimentos mais comuns na prática do cirurgião geral. Estima-se que 20 milhões dessas operações sejam realizadas no mundo anualmente. Com o advento da técnica sem tensão e implante de tela sintética, as taxas de recidiva caíram expressivamente e a recidiva deixou de ser a principal complicação tardia após o reparo da hérnia inguinal. Hoje a principal complicação pós-operatória tardia da cirurgia de HI é a dor crônica inguinal pós-operatória (DCIP). A definição de DCIP é a dor pós-operatória da região inguinal após 3-6 meses da cirurgia. Relatamos o caso de um jovem paciente do sexo masculino que se apresentou com DCIP após ter sido previamente submetido a duas herniorrafias inguinais. Inicialmente apresentava dor inguinal a esquerda sem abaulamento evidente e na ocasião foi submetido a herniorrafia inguinal esquerda pela técnica de Lichtenstein. Não houve resolução da dor após a cirurgia. Após 1 ano foi novamente operado, dessa vez bilateralmente e infelizmente evoluiu com piora da dor apresentava dor predominantemente neuropática (em queimação e com irradiação para região testicular bilateralmente) e intensidade moderada (escala visual analógica 6), sem melhora com anti-inflamatórios não esteroidais ou analgésicos. Apresentava dor ao toque do anel inguinal externo bilateralmente, hiperestesia no território de nervos genito-femoral, ílio-hipogástrico e ílio-inguinal do lado esquerdo e hipoestesia no território dos três nervos do lado direito. Apresentou alívio temporário da dor após bloqueio anestésico inguinal bilateral. Paciente foi então submetido a triplo-neurectomia bilateral com remoção das telas de polipropileno. Em seguimento um ano após o tratamento cirúrgico, o paciente permanece sem dor inguinal.

**Palavras-chave:** Dor crônica; Hérnia inguinal; Técnica de Lichtenstein.

1. Hospital Alemão Oswaldo Cruz - HAOC, São Paulo (SP), Brasil. <https://orcid.org/0000-0003-1219-1142>. E-mail: [drpaulobarros@gmail.com.br](mailto:drpaulobarros@gmail.com.br)

2. Hospital Alemão Oswaldo Cruz - HAOC, São Paulo (SP), Brasil. <https://orcid.org/0000-0002-4318-4343>. E-mail: [capapetersen@gmail.com](mailto:capapetersen@gmail.com)

3. Hernia Clinic, São Paulo (SP), Brasil. <https://orcid.org/0000-0001-8866-7034>. E-mail: [drbrunohernani@gmail.com](mailto:drbrunohernani@gmail.com)

4. Faculdade de Medicina do ABC, Santo André (SP), Brasil. <https://orcid.org/0000-0001-9613-1635>. E-mail: [camilasborges4@gmail.com](mailto:camilasborges4@gmail.com)

5. Universidade Federal de São Paulo, São Paulo (SP), Brasil. <https://orcid.org/0000-0002-6437-8307>. E-mail: [ironpires@gmail.com](mailto:ironpires@gmail.com)

6. Hospital Israelita Albert Einstein, São Paulo (SP), Brasil. <https://orcid.org/0000-0002-4614-4689>. E-mail: [jnathanael@takaoka.com.br](mailto:jnathanael@takaoka.com.br)

7. Hospital Israelita Albert Einstein, São Paulo (SP), Brasil. <https://orcid.org/0000-0002-6336-6929>. E-mail: [marcus.lourenco@yahoo.com.br](mailto:marcus.lourenco@yahoo.com.br)

8. University of Texas Medical Branch, Galveston (TX), Estados Unidos. <https://orcid.org/0000-0001-8485-9960>. E-mail: [luciano.tastaldi@gmail.com](mailto:luciano.tastaldi@gmail.com)

**Correspondence:** Paulo Henrique Fogaça de Barros. Rua Mato Grosso 306, cj 1303 – Higienópolis. São Paulo, SP, Brasil. CEP 01239-040. E-mail: [drpaulobarros@gmail.com](mailto:drpaulobarros@gmail.com)

## INTRODUCTION

Inguinal hernia is one of the most frequent surgical diseases. There is an estimated incidence of 20 million surgical procedures worldwide per year.<sup>1</sup> In 1989, recurrence ceased to be the main late complication after Irving Lichtenstein proposed the tension-free technique using a polypropylene mesh<sup>2</sup>. Today, the Hernia Surge Group, considers the large centers recurrence around 1%<sup>1</sup>.

Therefore, today the main late postoperative complication of inguinal herniorrhaphy is chronic postoperative inguinal pain (CPIP). Data show that up to 63% of patients experience some degree of discomfort after the first year of surgery. It is estimated that 10-12% of patients will present chronic inguinal pain, with 0.5-6% being severe, with impact on daily activities and quality of life, requiring some type of treatment<sup>3</sup>.

The definition of CPIP is postoperative pain in the inguinal region that lasts for more than 3-6 months after surgery<sup>4,5</sup>. It can be characterized as neuropathic, nociceptive, somatic, or visceral. Neuropathic pain results from damage to one of the inguinal nerves. The patient presents burning pain, tingling, and irradiation to the dermatome corresponding to the injured nerve. Tinel's sign - percussion on the nerve, triggering a tingling sensation in the region may be positive in these cases and there is improvement with regional anesthetic blocks. Nociceptive pain occurs due to an exaggerated inflammatory response. It usually comprises the region of the mesh location, and temperature changes and erection of hairs can be observed. Somatic pain occurs due to injury of the periosteum in the region of the pubic tubercle and is usually exacerbated on movement and relieved at rest. Finally, visceral pain arises from injury to the spermatic cord and the patient usually presents testicular pain.

The purpose of this study is to report the case of a patient with CPIP, with resolution after triple-neurectomy,

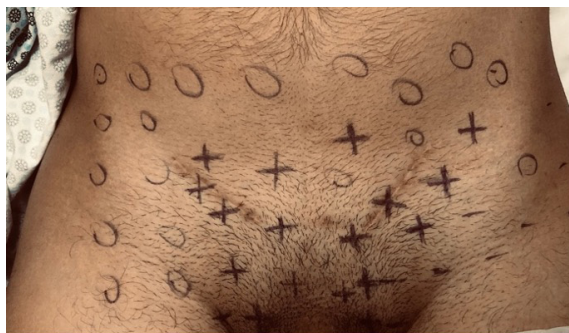as well as to review the management of CPIP.

## CASE REPORT

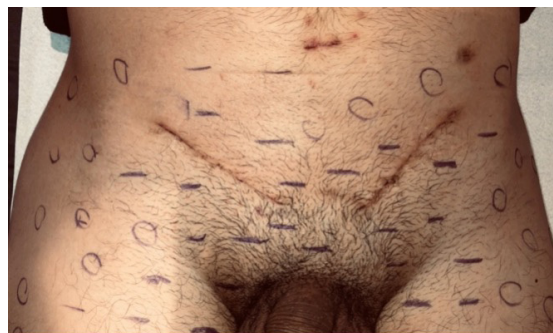A 34-year-old male patient have been with chronic bilateral inguinal pain for approximately 6 years. Initially, he showed left inguinal pain without evident bulging and underwent left inguinal herniorrhaphy using the Lichtenstein technique. The reported discomfort did not resolve and 5 years later, he underwent bilateral inguinal herniorrhaphy.

After the second surgical procedure, he developed worsening neuropathic pain (burning pain and irradiation to the testicular region bilaterally) and moderate intensity (VAS 6), with no improvement with the use of non-steroidal anti-inflammatory drugs and analgesics. Physical examination showed positive Tinel's sign near the external inguinal ring, bilaterally. Mapping of the inguinal nerves (Figure 1a) revealed hyperesthesia in the territory of the genitofemoral, iliohypogastric, and ilioinguinal nerves bilaterally. Then he underwent a bilateral anesthetic block of the three nerves, with complete resolution of symptoms by 48h. Thus, a bilateral triploneurectomy procedure was indicated, with removal of the polypropylene mesh.

The surgical procedure was initiated by laparoscopy, and a bilateral section of the genital branch of the genitofemoral nerve was performed (Figure 2a). Next, inguinoscopy was performed with removal of the polypropylene mesh and neurectomy of the iliohypogastric and ilioinguinal nerves was performed at their origins in situ near the anterior superior iliac spine (Figure 2b). The stump of the nerves was ligated with polygalactin thread and invaginated into the fibers of the internal oblique muscle. At hospital discharge, pregabalin 150 mg/day was maintained for 1 month. Currently at 1 year postoperative follow-up, the patient is pain-free. Mapping of the inguinal nerves now shows hypoesthesia in the territory of the bilaterally (Figure 1b).



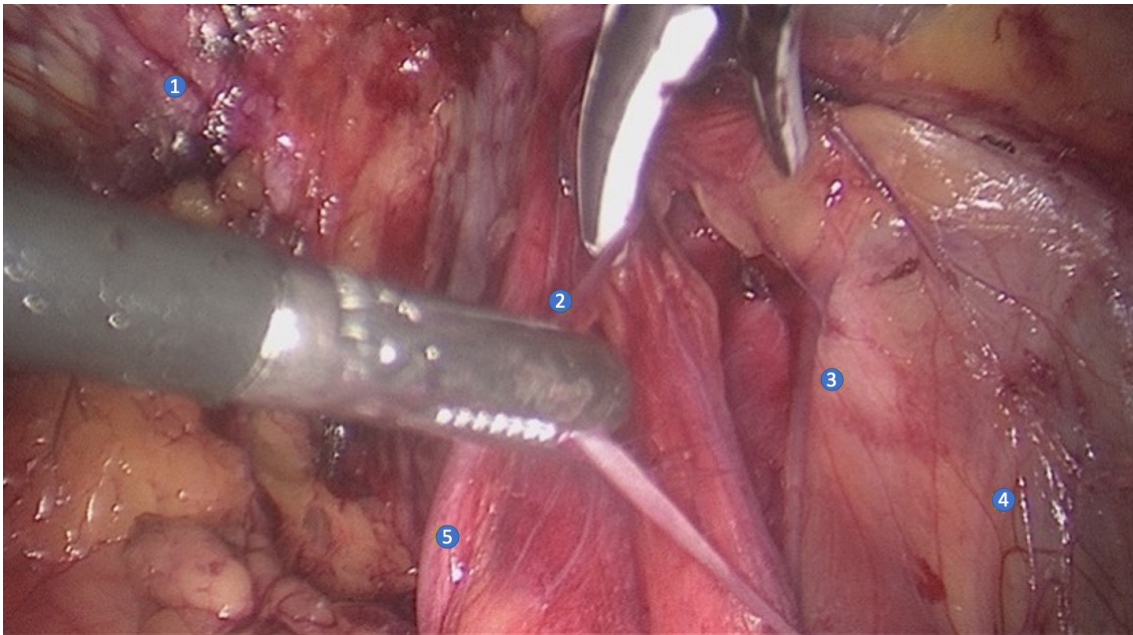
**Figure 1a:** Pre-operative – bilateral hyperesthesia;



**Figure 1b:** Post-operative – bilateral hypoesthesia

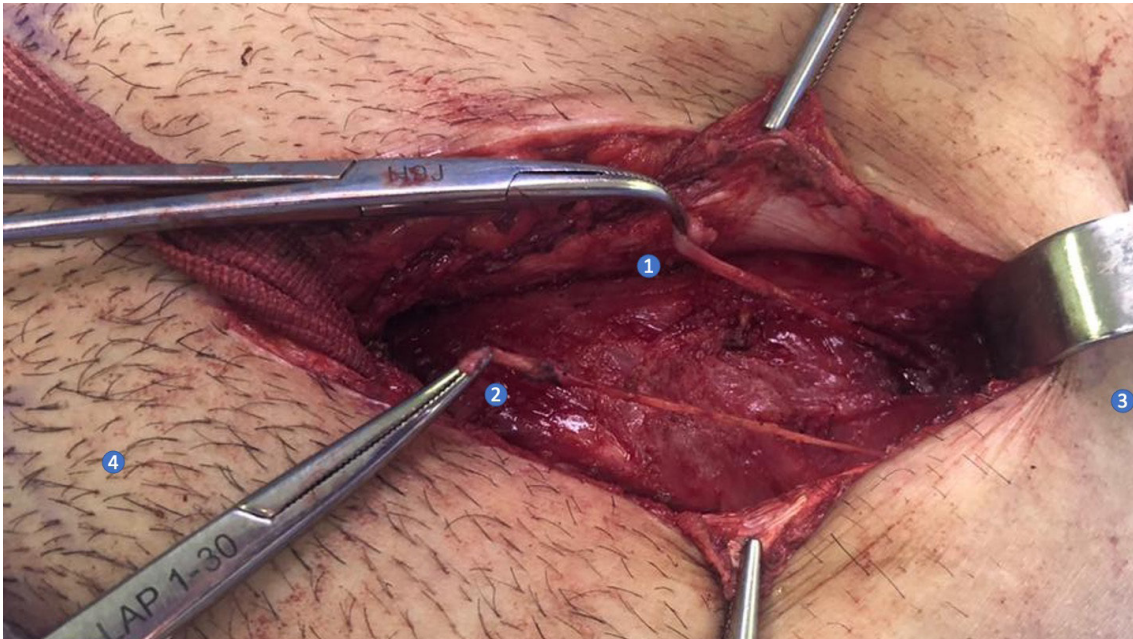
Meaning: (+) hyperesthesia; (-) hypoesthesia; (O) normoesthesia

**Right inguinal area**



**Figure 2a:** 1-Pub; 2- Genital branch of genitofemoral nerve; 3- Femoral branch of genitofemoral nerve; 4- Lateral cutaneous nerve; 5- Vas deferens

**Left inguinal area**



**Figure 2b:** 1-Iliohypogastric nerve; 2-Ilioinguinal nerve; 3-Anterosuperiour iliac crest; 4-Pub

**DISCUSSION**

**Inguinal Neuroanatomy**

Knowledge of the neuroanatomy of the inguinal region is imperative for the surgeon performing inguinal hernia repair. Only then, it is possible to identify and preserve nerves and avoid iatrogenic lesions. The

ilioinguinal and iliohypogastric nerves originate from the L1 nerve roots, emerge laterally to the psoas muscle, cross the quadratus lumborum muscle, and penetrate the transverse abdomen. They have a short path between the internal oblique and transverse abdominis muscle and, near the anterior superior iliac crest, penetrate the internal oblique muscle to the inguinal canal. The iliohypogastric

nerve lies superiorly to the ilioinguinal nerve, follows toward the rectus abdominis muscles and its sensory level is the hypogastric region. The ilioinguinal nerve goes towards the pubic tubercle, near the spermatic cord, and its sensory level is the region of the pubic tubercle in the medial face of the inguinal fold and the upper part of the scrotum. The genitofemoral nerve arises from L1 and L2, follows over the psoas muscle and, still in the retroperitoneum, divides itself into a femoral and a genital branch. The genital branch passes through the internal inguinal ring and together with the cremasteric vein runs along the spermatic cord until it reaches the lateral face of the scrotum, its sensitive region. The femoral branch penetrates near the iliopubic tract and innervates the region over the femoral vessels<sup>4,6</sup>.

**Patient Assessment**

The evaluation of the patient with CPIP goes through three steps (Figure 3). The first is to define whether or not the patient has a recurrence. Physical examination and ultrasonography of the inguinal region can confirm this hypothesis. Patients with recurrence and chronic pain must

be evaluated for the possibility of neurectomy associated with a new surgical procedure for correction. In these cases, neurectomy can be done either openly or laparoscopically when the initial approach was open. In cases of initial approach by laparoscopic procedure, neurectomy should also be performed this way, since the nerves need to be approached in their proximal portion.<sup>5</sup>

The second step is to rule out differential diagnoses. Several diseases cause inguinal pain. The MRI exam is recommended to help in the differential diagnosis of musculoskeletal diseases, such as adductor tendonitis, pubalgia, among others.

The third step is to characterize the pain as nociceptive or neuropathic. This evaluation is not easy because the vast majority of patients have a mixed picture. The imaging exam helps in the detection of an exaggerated inflammatory response on the mesh, known as “meshoma”, characteristic of nociceptive conditions. Evaluation of the dermatomes may suggest involvement of one or more nerves in the inguinal region.

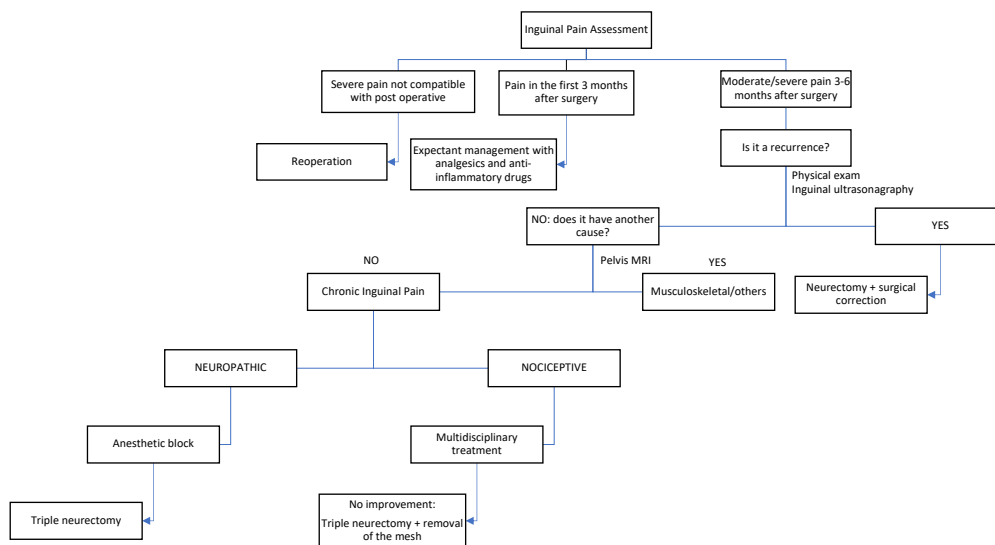


Figura 3: Fluxograma da avaliação do paciente com DCIP

**Treatment of inguinal pain**

A multidisciplinary team must perform the treatment: pain specialist, general surgeon, physiotherapist, among others. The expectant management is preferable in the first six months, with clinical treatment, use of simple analgesics, anti-inflammatory drugs and, in some cases, even the use of opioids. Patients that present severe pain, almost immediately after the surgery and not compatible with the normal postoperative period of an inguinal herniorrhaphy are the exception and must be considered for immediate reoperation.

Patients with maintenance of pain after 3-6 months from initial surgery are potential candidates for surgical procedure. Neuropathic conditions without resolution after clinical treatment may benefit from a triple neurectomy. Patients who have undergone open surgery may have the triple neurectomy procedure laparoscopically or openly, whereas patients who have previously undergone laparoscopic surgery should be reapproached laparoscopically. If an associated nociceptive component is suspected, triple neurectomy is recommended along with the removal of the polypropylene mesh and fixation material, if permanent. Triple neurectomy is preferred over

selective neurectomy as it has up to 95% success rate<sup>7</sup>. The major predictors of good response to operative treatment are patients who did not have much pain preoperatively, who have pain of exclusively neuropathic characteristic and those who have good response to peripheral anesthetic blocks of the ilioinguinal and iliohypogastric nerves.

When the procedure is done laparoscopically, the patient may present some abdominal bulging in the flank region, caused by denervation. Other complications involve spermatic cord lesion and consequent ischemic orchitis, besides the possibility of hernia recurrence. More serious complications such as injury to the iliac or femoral vessels are also described. All these possibilities should be discussed with the patients preoperatively.

Orchialgia (chronic testicular pain) is difficult to treat since there are several paravalvular branches that originate from S2-S4. Operative treatment consists of individualizing the ductus deferens and gonadal vessels by removing paravalvular branches between these two structures.

In a case of CPIP, a systematic and multiprofessional evaluation helps to correctly identify the cause of the pain and define the best treatment. Since the patient reported showed a good response to the peripheral nerve blocks, the probability of improvement was high with the operation. Delaying the correct evaluation of the patient can hinder the definitive treatment of chronic postoperative pain due to neuroplasticity and pain centralization. The ideal is to perform the treatment between 6 and 12 months after the initial operation, avoiding the perpetuation of the symptom.

## REFERÊNCIAS

1. The Hernia Surge Group Hernia. International guidelines for groin hernia management. *Hernia*. 2018;22:1-165. <https://doi.org/10.1007/s10029-017-1668-x>
2. Lichtenstein IL, Shulman AG, Amid PK, Montllor MM. The tension-free hernioplasty. *Am J Surg*. 1989;157(2):188-93. [https://doi.org/10.1016/0002-9610\(89\)90526-6](https://doi.org/10.1016/0002-9610(89)90526-6)
3. Hu QL, Chen DC. Approach to the patient with chronic groin pain. *Surg Clin N Am*. 2018;98:651-65. <https://doi.org/10.1016/j.suc.2018.02.002>
4. Alfieri S, Amid PK, Campanelli G, et al. International guidelines for prevention and management of post-operative chronic pain following inguinal hernia surgery. *Hernia*. 2011;15:239-49. <https://doi.org/10.1007/s10029-011-0798-9>

As important as the identification of CPIP and its correct treatment is its prevention. Patients who have inguinal pain without bulging is noted on physical examination should be investigated for causes of inguinal pain other than hernia. The follow-up of these cases, without surgical intervention, has proven to be a safe alternative<sup>1</sup>. Complementary imaging exams, such as MRI, can help rule out other causes of pain. In the open operation the correct identification of the inguinal nerves and their preservation is very important. Blunt isolation of the spermatic cord with the finger is a cause of injury to the genital branch of the genitofemoral nerve<sup>1</sup>. The use of non-absorbable sutures in the inguinal ligament should be respected with the recommendation of sutures with absorbable thread in the medial fixation of the mesh.<sup>7</sup> In laparoscopic operation, an atraumatic dissection and the use of atraumatic fixation methods, such as glue or self-fixing mesh, should be considered. In the case of using staples, use few respecting the region of the nerves and up to 2 cm above the ileopubic tract.<sup>6</sup> Closure of the peritoneum should preferably be performed with absorbable suture in order to minimize excess surgical staples.

## CONCLUSION

Chronic inguinal pain is currently the main postoperative complication of inguinal herniorrhaphy, thus prevention measures should be encouraged. Treatment must be evaluated carefully and performed by a multidisciplinary team. Triple neurectomy is an option for selected cases.

5. Lange JFM, Kaufmann R, Wijsmuller AR, Pierie JPEN, Ploeg RJ, Chen DC, Amid PK. An international consensus algorithm for management of chronic postoperative inguinal pain. *Hernia*. 2015;19(1):33-43. <https://doi.org/10.1007/s10029-014-1292-y>
6. Reinpold W, Schroeder AD, Schroeder M, Berger C, Roh, M, Wehrenberg U. Retroperitoneal anatomy of the iliohypogastric, ilioinguinal, genitofemoral, and lateral femoral cutaneous nerve: consequences for prevention and treatment of chronic inguinodynia. *Hernia*. 2015;19(4):539-48. <https://doi.org/10.1007/s10029-015-1396-z>
7. Amid PK. New understanding of the causes and surgical treatment of postherniorrhaphy inguinodynia and orchialgia. In: *Hernia repair sequelae*. Berlin: Springer; 2010. p.287-92. [https://doi.org/10.1007/978-3-642-11541-7\\_39](https://doi.org/10.1007/978-3-642-11541-7_39).

Submitted: 2021, June 19

Accepted: 2021 October 20