

## Use of secretome as an acellular regenerative therapy in the treatment of pneumonia resulting from infection by SARS-CoV-2 (COVID-19)

### *Utilização do secretoma como uma terapia regenerativa acelular no tratamento da pneumonia decorrente da infecção pela SARS-CoV-2 (COVID-19)*

Enrico Jardim Clemente Santos<sup>1</sup>, Angela Mazzeo<sup>2</sup>

Santos JCS, Mazzeo. Use of secretome as an acellular regenerative therapy in the treatment of pneumonia resulting from infection by SARS-CoV-2 (COVID-19) / *Utilização do secretoma como uma terapia regenerativa acelular no tratamento da pneumonia decorrente da infecção pela SARS-CoV-2 (COVID-19)*. Rev Med (São Paulo). 2023 Nov-Dec;102(6):e-210936.

**ABSTRACT:** The field of science related to stem cell biology has been extremely promising in recent years. Among the various branches, the therapeutic approach that involves the bioactive molecules secreted by the mesenchymal stem cells (MSCs) more commonly called the secretome, has been the subject of special attention. The fact that it is an acellular approach has led researchers to make it more effective. Among the possible targets are respiratory injuries in which yours includes the characteristic clinical pneumonia resulting from coronavirus infection (CoVs). In this work we address the state of the art and the therapeutic potential of the secretome in the treatment of patients affected by pneumonia due to infection by SARS-CoV-2 (severe acute respiratory syndrome derived from coronavirus 2).

**KEY WORDS:** SARS-CoV-2; Coronavirus; Mesenchymal stem cells; Secretome; Pneumonia.

**RESUMO:** O campo da ciência relacionado a biologia das células-tronco tem se mostrado extremamente promissora nos últimos anos. Dentre os diversos ramos, a abordagem terapêutica que envolve as moléculas bioativas secretadas pelas células-tronco mesenquimais (CTMs) mais comumente chamado de secretoma, vem sendo alvo de especial atenção. O fato de ser uma abordagem acelular tem levado os pesquisadores a torná-la mais eficaz. Dentre os possíveis alvos estão as lesões respiratórias na qual se inclui a pneumonia característica clínica decorrente da infecção por coronavírus (CoVs). Neste trabalho abordamos o estado da arte e o potencial terapêutico do secretoma no tratamento de pacientes acometidos por pneumonia em decorrência da infecção pela SARS-CoV-2 (severa síndrome respiratória aguda derivada do coronavírus 2).

**PALAVRAS-CHAVE:** SARS-CoV-2; Coronavírus; Células-tronco mesenquimais; Secretoma; Pneumonia.

<sup>1</sup> CELLTROVET, São Paulo, SP. ORCID ID: <https://orcid.org/0000-0003-0869-3342>. Email: [enrico@celltrovet.com.br](mailto:enrico@celltrovet.com.br).

<sup>2</sup> Universidade de São Paulo, São Paulo, SP. ORCID ID: <https://orcid.org/0000-0001-8483-5002>. Email: [amazzeo@usp.br](mailto:amazzeo@usp.br).

**Correspondence:** Enrico Jardim Clemente Santos. Rua José Piragibe 228/11a. Vila Indiana, São Paulo/SP, Brasil. CEP: 05585-040. Email: [enricosantos@celltrovet.com.br](mailto:enricosantos@celltrovet.com.br).

## INTRODUCTION

Since December 2019, severe acute respiratory syndrome coronavirus 2 (SARS-CoV-2), responsible for the outbreak of coronavirus disease 2019 (COVID-19), has been spreading rapidly around the world, which led the World Health Organization to declare the existence of a global coronavirus pandemic<sup>1</sup>.

Coronavirus (CoVs) is a virus belonging to the *Coronaviridae* family, which is composed of the genera *Alphacoronavirus*, *Betacoronavirus*, *Deltacoronavirus* and *Gammacoronavirus*, and is generally associated with respiratory

diseases and gastrointestinal infections. CoVs have been identified in several species, including felines, canines, horses, cattle, pigs, rodents, camels, bats, civets, humans, among other animals and avian species.

The human coronavirus (HCoVs), which has bats as its natural host, was initially described in 1965 by Tyrrell and Bynoe, based on children and adults who had respiratory infections. Subsequently, HCoVs were classified as belonging to the genera *Alphacoronavirus* (CoV-NL63 and CoV-229E) and *Betacoronavirus* (SARS-CoV, CoV-OC43, CoV-HKU1, MERS-CoV and SARS-CoV)(Table 1)<sup>2,3</sup>.

**Table 1** - Types of coronavirus that infect humans

VIRUS	GENDER	DISCOVERY	NATURAL HOST	INTERMEDIATE HOST
CoV-NL-63	<i>Alphacoronavirus</i>	1965	Bat	Unknown
CoV-229E	<i>Alphacoronavirus</i>	1967	Bat	Alpacas
SARS-CoV	<i>Betacoronavirus</i>	2003	Bat	Masked Palm Civet
CoV-OC43	<i>Betacoronavirus</i>	2004	Rodent	Cattle
CoV-HKU-1	<i>Betacoronavirus</i>	2005	Rodent	Unknown
MARS-CoV	<i>Betacoronavirus</i>	2012	Bat	Camel and Dromedary
SARS-CoV-2	<i>Betacoronavirus</i>	2019	Bat	Unknown

In February 2003, a new HCoVs was identified in Guangdong province, southern China, which has bats as its natural host and the masked palm civet as an intermediate host. This HCoV ended up being called SARS-CoV (severe acute respiratory syndrome derived from the coronavirus) as it was responsible for causing a severe respiratory disease. This is initially marked by systemic symptoms such as muscle pain, headache and fever, followed within 2 to 14 days by the appearance of respiratory symptoms, mainly cough, dyspnea, pneumonia and a decrease in the number of lymphocytes circulating in the blood<sup>4,5</sup>. SARS-CoV ultimately resulted in an epidemic with 8098 reported cases and 774 deaths (9.5% fatality rate). Cases of SARS-CoV were identified in 29 countries located in Europe, Asia, North America and South America<sup>6</sup>. The possible dissemination focus was the local market in Guangdong, where live or slaughtered wild animals are sold, the SARS-CoV virus is believed to have crossed the xenographic barrier from the masked palm civet to humans through meat consumption. According to the World Health Organization, as of October 1, 2022, 619,770,633 deaths had been confirmed with 6,539,058 deaths (1% fatality rate)<sup>7</sup>.

In 2012, a new HCoVs of the *Betacoronavirus* genus was isolated in Saudi Arabia and was named MERS-CoV (Medical East respiratory syndrome). MERS-CoV has bats as its natural host, with camels and dromedaries as intermediate hosts. MERS is a disease that presents as symptoms fever, cough, shortness of breath, chills, body aches, general feeling of malaise, diarrhea, nausea and vomiting. Serious complications can result in organ failure, particularly renal failure and pneumonia<sup>8,9</sup>. Data from the World Health Organization, until May 12, 2022, reported that 2591 cases were confirmed with 894 deaths (fatality rate of 34.5%)<sup>10</sup>.

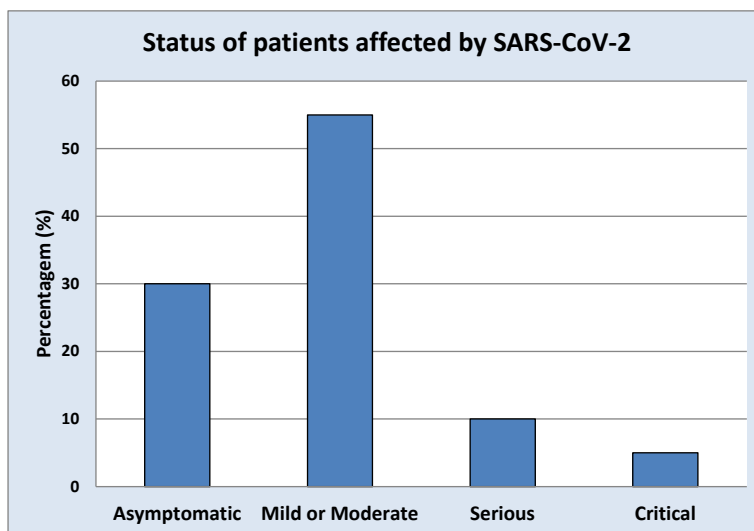
On December 31, 2019, the World Health Organization (WHO) was alerted to several cases of pneumonia in the city of Wuhan, capital of Hubei province, in the People's Republic of China. Although little known in the West, Wuhan has four scientific and technological development parks, more than 350 research institutes, 1,656 high-tech companies and numerous business incubators, in addition to maintaining the largest virus bank in Asia at its location of Chinese for Virus Culture Collection, at the Wuhan Institute of Virology (WIV), considered the most important culture collection center in the country.

The first cases originated in the seafood market in the city of Wuhan, with its incidence increasing exponentially in the first few weeks. On January 7, 2020, the Chinese Center for Disease Control and Prevention confirmed the existence of a new strain of HCoVs, genus *Betacoronavirus*, which was named SARS-CoV-2<sup>11</sup>. In just three months, SARS-CoV-2 has spread throughout the world, which led the World Health Organization to declare, on March 11, 2020, a global pandemic<sup>1</sup>. It is currently believed that the natural host of SARS-CoV-2 is the bat, being the undefined intermediate host.

The clinical picture of SARS-CoV-2 has an incubation period that normally varies between 2 and 5 days. Infected patients tend to present symptoms such as high fever, headache and myalgias. Respiratory symptoms such as dry cough, dyspnea and positive chest x-ray usually develop one week after the onset of the disease. The most susceptible groups are those over 65 years of age and/or with underlying diseases such as hypertension, heart disease, diabetes, kidney disease and respiratory diseases such as pneumonia<sup>12,13</sup>. In more serious cases, patients may present with dysfunction in the blood clotting process, septic shock, metabolic acidosis and multiple organ failure<sup>14</sup>. Data have shown that: 30% of patients are asymptomatic; 55% have

mild or moderate symptoms such as fever, dry cough, headache, tiredness and slight difficulty breathing; 10% show a serious condition, which reaches an average mortality rate of 15%. The severe condition consists of dyspnea, blood oxygen saturation below 93% at rest, PaO<sub>2</sub>/FiO<sub>2</sub> rate below 300 mmHg, respiratory rate above 30/min reaching more than 50% of pulmonary

infiltrate in a period of 24 to 48 hours; and 5% present critical symptoms such as septicemia, need for mechanical ventilation, multiple organ failure or dysfunction, requiring referral to the Intensive Care Unit (ICU). This situation presents a mortality rate of approximately 50%<sup>15-18</sup>.



Graph 1 - Rates of patients affected by SARS-CoV-2<sup>13-16</sup>

## METHOD

The present study is characterized by having been carried out based on a bibliographical research of an exploratory and descriptive nature along with scientific databases indexed in the databases Google Scholar, Scientific Electronic Library Online (SciELO), Latin American Caribbean Literature in Science of Health (LILACS) and Medical Literature Analysis and Retrieval System Online (MEDLINE). For the search, the publication time frame was carried out between the years 2003 and 2022, using the following keywords: secretome, COVID-19 and mesenchymal stem cells.

## RESULT AND DISCUSSION

The SARS-CoV-2 genome is composed of a single strand of 29.9 kb positive-sense RNA, which interacts with nucleoprotein<sup>19</sup>. The SARS-CoV-2 genome has a variable number (6 to 11) of the open reading frames (ORFs), two thirds of which are located in the first ORF (ORF 1a/b) - which translates two polyproteins (pp1a and pp1ab), in addition to encoding 16 non-structural proteins. The remaining ORFs encode structural and accessory proteins. The remaining part of the genome encodes four structural proteins that make up SARS-CoV-2 and the membrane proteins, envelope proteins, nucleocapsid protein, Spike surface glycoprotein and some accessory proteins that interfere with the host's innate immune response<sup>20</sup>. Spike surface glycoprotein, fundamental in the SARS-CoV-2 infection process, is functionally divided into two domains: S1, responsible for binding processes to the ACE2 receptor and S2, responsible for fusion with the cell membrane. The receptor binding domain

(RBD) of SARS-CoV-2 is normally located in the C-terminal domain of S1. The Spike surface glycoprotein is responsible for recognizing the cellular receptor, the angiotensin-converting enzyme 2 (ACE2), fundamental in the process of tropism to the host and the transmission capacity of the virus. Due to the SARS-CoV-2 viral replication mechanism having a high frequency of recombination, high mutation rate and intra and interspecific transmission process, SARS-CoV-2 is capable of giving rise to new strains of coronavirus<sup>21</sup>.

ACE2 is widely present in both type 2 alveolar cells and the capillary endothelium of the lungs, as well as several other organs such as the kidney, liver, cardiovascular system and gastrointestinal tract. However, as the lungs are the first organ to be infected, it is believed that, due to their low regeneration rate, they are extremely affected by SARS-CoV-2<sup>22</sup>.

MSCs (mesenchymal stem cells) are defined as a non-specialized cell population, long and flat, presenting a fibroblastoid morphology, ability to adhere to polymeric surfaces, high proliferation potential, capable of self-renewal, giving rise, according to with the microenvironment in which they are found, multiple cell lineages<sup>23</sup>. In a meeting held by the Mesenchymal and Tissue Stem Cell Committee of the International Society for Cellular Therapy, in 2006, the minimum characteristics that human cell lines, obtained from different sources, to be classified as MSCs, they must present: (a) cells adherent to plastic when maintained in standard culture conditions; (b) expression of CD105, CD73 and CD90, and lack of expression of CD45, CD34, CD14 or CD11b, CD79a or CD19 and HLA-DR and (c) ability to differentiate into osteoblasts, adipocytes and chondroblasts *in vitro*<sup>24</sup>.

Present in all tissues that make up the organism, MSCs are

responsible for maintaining homeostasis and reparative processes in the cellular microenvironment of injured tissues. These occur through cell differentiation, modulation of the immune system, suppressive action of innate and adaptive immune responses, cell renewal, anti-apoptotic action through prevention of cell death via restoration of the local microenvironment, production of apoptosis-inhibiting proteins and decrease expression of apoptotic proteins, inhibition of oxidative stress, responsible for causing a reduction in the rate of cell proliferation, increasing senescence and inhibiting the immunomodulatory effect of MSCs, angiogenic action in which new blood vessels arise from pre-existing vessels and anti-fibrotic action responsible for reducing the formation of scars<sup>25</sup>.

Due to their potential for *in vitro* expansion, ability to treat tissue injuries, maintenance of their immunomodulatory and differentiation properties, even after long periods of

cryopreservation, MSCs present themselves as a potential resource for both trials and clinical therapies. However, for MSCs to perform their role satisfactorily, some factors must be considered, as they directly influence their therapeutic potential. Among these are the quality of the cells to be used, cellular integrity, ability to self-renew, *in vitro*, for a limited time, differentiation potential, donor age, clinical characteristics, senescence rate, paracrine function in addition to the fact of its life useful to vary from species to species.

Studies have demonstrated the benefits of bioactive molecules secreted by MSCs. These regulate, through the action of paracrine or endocrine mediators, the countless physiological processes existing in the organism (Table 2). Thus, bioactive molecules secreted by MSCs, better known as secretome, have been attracting the attention of researchers due to their potential for use in tissue repair and regeneration processes<sup>26-29</sup>.

**Table 2** - Bioactive molecules secreted by MSCs which exert mediating effects via paracrine or endocrine action.

ANGIOGENESIS	ANTI-APOPTOSIS	ANG-1	ANTI-OXIDANT	IMMUNOMODULATION	PROLIFERATION	CHEMOTAXIS
Ang-1	FGF	Ang-1	HO-1	HO-1	FGF	CCLs
FGF	GM-CSF	FGF	IL1 $\beta$	IDO	HGF	CXCLs
HGF	HGF	HGF	STC-1	IL-1ra	IGF-1	G-CSF
IGF-1	IGF-1	KGF		IL-6	KGF	LIF
IL-6	IL-6	MMPs		IL-10	PDGF	M-CSF
MCP-1	STC-1	TIMP-1		LIF	VEGF	MCP-1
PDGF				PGE2		SDF-1
VEGF				STC-1		
				TGF- $\beta$		
				TSG-6		

Angiopoietin-1 (Ang-1); Chemokine ligand (CCL); C-X-C motif Chemokine ligand (CXCL); Fibroblast growth factor (FGF); Granulocyte monocyte colony stimulating factor (GM-CSF); Hepatocyte growth factor (HGF); Hemeoxygenase – 1 (HO-1); Indoleamine 2,3-dioxygenase (IDO); Insulin like growth factor – 1 (IGF-1); Interleukin (IL); IL-1 Receptor antagonista (IL-1Ra); Keratinocyte growth factor (KGF); Leukemia inhibitory factor (LIF); Human cathelicidin (LL-37); Metalloproteinase (MMP); Monocyte chemoattractant protein – 1 (MCP-1); Platelet derived growth factor (PDGF); Prostaglandin E2 (PGE2); Stem cell-derived factor-1 (SDF-1); Stanniocalcin – 1 (STC-1); Tissue inhibitor of metalloproteinase 1 (TIMP-1); Transforming growth factor –  $\beta$  (TGF- $\beta$ ); Tumor necrosis factor-stimulated gene 6 (TSG-6) and Vascular endothelial growth factor (VEGF).

The secretome can be defined as a set of molecules secreted into the extracellular space in specific response to physiological changes or pathological conditions in the cellular environment. Among the biomolecules that can constitute the secretome are soluble proteins, microRNAs, growth factors, antioxidants, nucleic acids, lipids and extracellular vesicles (EV (microparticles, apoptotic bodies and exosomes))<sup>30</sup>.

The therapeutic use of the secretome derived from MSCs (S-CTMs) presents numerous advantages over the traditional cellular approach, including: 1. The secretome can be evaluated for its dosage, safety and efficacy in a similar way to conventional pharmaceutical agents; 2. Its clinical use is more economical and practical as it avoids the need to collect material to isolate MSCs; 3. The application of the secretome optimizes therapeutic safety as it avoids the transplantation of living cell populations, avoiding issues such as immunological compatibility, transmission of infections, tumorigenicity and possible generation of embolism; 4. The biological product obtained may have its molecular composition altered in order to improve the therapeutic effect of the secretome. To this end, the cultivation of MSCs can be subjected to specific environments such as three-dimensional growth, which positively regulates

the production of anti-tumor and anti-inflammatory factors, hypoxic conditions, which increases the production of growth factors and anti-inflammatory molecules, pro-inflammatory stimuli, which induce greater secretion of factors related to immunity, and microparticle engineering; 5. Impossibility of generating endogenous tumors, as they do not have the self-replication potential characteristic of MSCs; 6. Low possibility of emboli formation after intravenous infusion; 7. Optimization of secretome production can be achieved by establishing specific laboratory conditions, reducing costs and minimizing production time and increasing it; 8. Storage can be carried out at lower costs and without the use of cryopreservative agents that are potentially toxic to cells; 9. Storage can be carried out for long periods without losing its therapeutic potential; and 10. It is ideal for emergency therapeutic interventions.

## THERAPEUTIC PERSPECTIVE

The respiratory system is constantly exposed to several factors responsible for altering pulmonary homeostasis, which is maintained through the interaction between alveolar epithelial and immune cells present in the lung microenvironment. Acute

lung injury (ALI) resulting from SARS-CoV-2 infection is responsible for causing diffuse alveolar damage and non-cardiogenic pulmonary edema, clinically characterized by hypoxemic respiratory failure and the presence of bilateral pulmonary infiltrates, requiring the use of a mechanical ventilator<sup>31</sup>. In these cases, the pathophysiology of ARDS (Acute Respiratory Distress Syndrome) is one of the most serious aspects that affect patients infected by SARS-CoV-2, being similar to severe community-acquired pneumonia, caused by viruses and bacteria. Patients who develop the severe form of the disease may present symptoms such as cytokine shock in which there is overproduction of early response pro-inflammatory cytokines, such as tumor necrosis factor (TNF- $\alpha$ ), IL-6 and IL-1 $\beta$ , characterizing a syndrome which promotes increased vascular hyperpermeability, multiple organ failure and eventually death<sup>32</sup>.

Therefore, therapeutic solutions that are immunomodulatory or anti-cytokines become attractive, aiming to stabilize the inflammatory process, such as the application of intravenous immunoglobulins and the use of steroids<sup>33</sup>. The process of repairing lung injury is modulated by a set of factors such as cellular matrix metalloproteinases (MMPs), cytokines and growth factors produced by lung-resident immune epithelial cells, fibroblasts and chondrocytes<sup>34</sup>.

Several experimental and clinical studies have been carried out using the therapeutic potential of MSCs in a safe and effective way. However, issues related to the unwanted differentiation process of transplanted MSCs still remain a problem to be resolved. Breitbach and collaborators observed the formation of encapsulated structures containing calcifications and ossifications in the heart tissue of mice after the MSCs were injected into the infarcted region, suggesting that a process of osteogenic differentiation occurred from the transplanted cells<sup>35</sup>. Liao and collaborators, after the MSCs have been transplanted into hyperlipidemic rats, reported calcification in the injured region of the abdominal aorta<sup>36</sup>. The secretome has shown therapeutic effects similar to those obtained in patients undergoing transplantation with MSCs. This fact leads the secretome to be a safer therapeutic approach, that is, it overcomes the problem related to unwanted differentiation<sup>37-40</sup>.

The beneficial effects obtained from secretome-based therapy have been demonstrated in several experimental models related to respiratory diseases. These include pulmonary arterial hypertension, chronic obstructive pulmonary disease (COPD), idiopathic pulmonary fibrosis (IPF), acute lung injury syndrome (APLS), asthma, pneumonia<sup>41-46</sup>. Therapy through the secretome has proven interesting due to its anti-microbial, anti-oxidant properties, pro- and anti-inflammatory effects, increased phagocytic activity, reduced pulmonary fibrosis, anti-apoptotic effect, in addition to inducing the repair process and regeneration of injured alveolar epithelium<sup>47-48</sup>. Considering the therapeutic potential of the secretome in different types of pathologies, including those related to the respiratory system, it appears as a promising therapeutic perspective for the treatment of pneumonia resulting from SARS-CoV-2 infection<sup>48</sup>.

Among the various symptoms resulting from SARS-CoV-2 infection, pneumonia is one of the most relevant, and in

some cases, it is necessary to implement oxygen therapy based on mechanical ventilation. According to Monsel and collaborators, the administration of bioactive molecules secreted by MSCs in mice affected by bacterial pneumonia reduced the inflammatory process and bacterial load, resulting in a higher survival rate of the animals. The antimicrobial effect was partially attributed to increased phagocytosis of bacteria by monocytes while decreased secretion of pro-inflammatory cytokines as well as increased intracellular ATP levels in type 2 alveolar epithelial cells that were injured<sup>49</sup>.

Putra and collaborators carried out a study involving the therapeutic use of S-CTMs in three patients who had severe COVID-19. The patients were admitted to the intensive care unit (ICU) of three different hospitals in Indonesia, having undergone conventional treatments for the serious condition of COVID-19 infection, in addition to new therapy with secretome<sup>50</sup>.

The first patient, a 54-year-old Indonesian man with severe hypertension, was diagnosed with COVID-19 on August 28, 2020, and admitted with cough and dyspnea. Initial examinations showed a temperature of 36°C, pulse of 102/min, respiratory rate of 32/min and blood pressure of 200/100. Arterial blood gas analysis showed a decrease in oxyhemoglobin saturation (SpO<sub>2</sub>=80.6%; normal reference: 95-100%), partial pressure of CO<sub>2</sub> (PaCO<sub>2</sub>=22.9 mmHg; normal reference: 38-42 mmHg), pressure partial oxygen (PO<sub>2</sub>=37.6 mmHg; normal reference: 70-99 mmHg) and HCO<sub>3</sub><sup>-</sup> (18.9 mmol/L; normal reference: 22-29 mmol/L). Laboratory data reported increased white blood cell count (WBC)(17.2 × 10<sup>9</sup> /L; normal reference: 4-10 × 10<sup>9</sup> /L), monocytes (9%; normal reference: 2-8%) and reduction in lymphocyte count (15%; normal reference: 20-40%). On August 29, 2020, D-Dimer was elevated (1,540 ng/mL; normal reference: 0-231 ng/mL) with increased C-reactive protein (CRP, 61.7 mg/dL; normal reference: 0-8.1 mg/L). Chest X-ray showed bronchopneumonia with bilateral opacities (GGOs) and cardiomegaly condition. On August 30 and 31, 2020, the patient underwent three infusions of 1 mL of S-CTMs, during a 12-hour interval, intramuscularly in the deltoid region, in addition to standard treatment. On September 4, 2020, there was an increase in SpO<sub>2</sub> (99.6%), PaCO<sub>2</sub> (36.2 mmHg), PO<sub>2</sub> (198.7 mmHg) and HCO<sub>3</sub><sup>-</sup> (24.7 mmol/L). Laboratory data showed normal counts of WBC (7.4 × 10<sup>9</sup>/L), monocytes (5%) and lymphocytes (20%) while D-dimer and CRP levels were reduced to 1,297 ng/mL and 2.33 mg/dL, respectively. The chest X-ray showed bronchopneumonia with cardiomegaly. On September 10, the patient tested negative for Covid-19 infection. The chest x-ray showed significant improvement without bronchopneumonia and cardiomegaly being observed. The D-Dimer was reduced (384 ng/mL), and the CRP was at its normal rate (0.31 mg/dL). On September 20th, the patient was discharged from the ICU as he had no cough or dyspnea and his SpO<sub>2</sub> had reached normal levels (98.7%).

The second patient, a 53-year-old Indonesian with type 2 diabetes mellitus, was diagnosed with COVID-19 on November 16, 2020, with cough, dyspnea, chest pain and fatigue. The chest X-ray revealed cardiomegaly with pulmonary edema, bilateral GGOs, elongation and aortic atherosclerosis. Blood gas analysis showed PaCO<sub>2</sub> (29.9 mmHg), PO<sub>2</sub> (177.1 mmHg) and HCO<sub>3</sub><sup>-</sup>

(20.8 mmol/L), but SpO<sub>2</sub> levels were still normal (98%). On November 21, there was a reduction in SpO<sub>2</sub> (90.6%) and PO<sub>2</sub> (57.5 mmHg). Laboratory data showed a normal WBC count ( $6.02 \times 10^9/L$ ), an increase in neutrophils (81%, normal reference: 50-70%) and monocytes (9%) in addition to a decrease in lymphocyte indices (10%). An increase in D-Dimer (880 ng/mL), CRP (160 mg/L) and fasting plasma glucose (FPG, 398 mg/dL; normal reference: 70-140 mg/dL) values was observed. The patient underwent four infusions of 1 mL of S-CTMs, over a 12-hour interval, intramuscularly in the deltoid region on November 21 and 22, 2020, in addition to standard treatment. 6 hours after the fourth infusion of S-CTMs, an increase in SpO<sub>2</sub> (98.7%), PO<sub>2</sub> (138.5 mmHg), pH (7.509) and HCO<sub>3</sub><sup>-</sup> (29.7 mmol/L) was detected. On November 22, chest x-ray showed significant improvement with minimal pulmonary infiltration. On November 23, SpO<sub>2</sub> (95.9%), PaCO<sub>2</sub> (36.1 mmHg) and PO<sub>2</sub> (71.5 mmHg) were normal. Laboratory data showed an increase in neutrophil count (85%), normalization in monocyte count (6%) and reduction in lymphocyte count (9%) as well as D-Dimer (660 ng/mL), fasting plasma glucose (277 mg/dL) and CRP (5.12 mg/dL). On December 5, the patient no longer had cough, dyspnea, chest pain or fatigue, with SpO<sub>2</sub> reaching a concentration of 99.2%. On December 28, the chest X-ray showed normal cardiac and pulmonary physiology, as well as laboratory data showing normal counts of neutrophils (57%) and lymphocytes (27%) and an increase in monocytes (11%).

The third patient, a 72-year-old Indonesian man with mild hypertension, liver failure, stroke sequelae and thalassemia, was diagnosed with COVID-19 on December 16, 2020, and admitted with abdominal pain, diarrhea, anosmia, cough and sore throat. Preliminary examinations demonstrated a temperature of 37.3°C, pulse of 82/min, respiratory rate of 24/min, blood pressure of 140/90 mmHg, SpO<sub>2</sub> of 97%, chest x-ray with bilateral GGOs, reduction in WBC count ( $3.1 \times 10^9/L$ ), increased monocyte count (18.8%) and neutrophil count (53.4%) in addition to normal lymphocytes (26.8%). On December 23, the patient's dyspnea worsened and blood gas analysis revealed a reduction in oxygen saturation (85%) in addition to a decrease in PaCO<sub>2</sub> (30 mmHg), PO<sub>2</sub> (49 mmHg) and HCO<sub>3</sub><sup>-</sup> (19 mmol/L). Chest radiography showed worsening of bilateral GGOs with cardiomegaly and aortic atherosclerosis. Laboratory data showed an increase in the count of neutrophils (72.9%) and monocytes (14.9%), a reduction in lymphocytes (11.7%), an increase in D-Dimer (235 ng/mL) and CRP (118 mg/L). On December 24th and 26th, the patient underwent six infusions of 1 mL of S-CTMs, during a 12-hour interval, intramuscularly in the deltoid region in addition to standard treatment. The day after the first injection of S-CTMs, oxygen saturation increased (98%), temperature was 37°C, pulse was 90/min, respiratory rate was 28/min, and blood pressure was 120/80 mmHg. On December 28, the examination showed a

temperature of 37°C, pulse of 80/min, respiratory rate of 24/min, blood pressure of 120/80 mmHg and normal oxygen saturation (98%). Laboratory data showed normal counts of neutrophils (78.3%), monocytes (7.2%) and lymphocytes (25.8%) in addition to D-Dimer (86.9 ng/mL) and CRP (8.5 mg/dL) decreased. The chest x-ray showed a decrease in bilateral GGOs, cardiomegaly and aortic elongation. On December 30, the patient no longer had abdominal pain, diarrhea, anosmia, cough and sore throat, and the SpO<sub>2</sub> test showed a concentration of 99%. On January 6, 2021, the patient tested negative for COVID-19.

In a study, carried out by Mina Fathi-Kazerooni and collaborators over a period of 28 days, 30 patients were randomly selected to determine the safety and effectiveness of infusions such as S-CTMs. Inclusion criteria were age 25 to 75 years, positive result in the SARS-CoV-2 polymerase chain reaction (PCR), RR > 30 times/min, oxygen saturation of 90% or less, concentration arterial partial pressure oxygen/oxygen level  $\leq 300$  mmHg and pulmonary infiltration greater than 50% in 24-48 h. The 30 selected patients had severe pneumonia due to COVID-19 and were randomized at a 1:1 rate to receive S-CTMs or injectable normal saline (control). The treated group, consisting of 9 men and 6 women, received five intravenous infusions of 5 mL of S-CTMs diluted in 100 mL of saline solution over a period of 5 consecutive days for 60 min. The control group, consisting of 10 men and 5 women, received five infusions of 100 mL of saline solution for 5 consecutive days for 60 min. No adverse effects were observed during the patient follow-up period. Assessment of patients' oxygenation demonstrated that 64% had optimized oxygen levels within 5 days of starting treatment, which suggests that S-CTMs can play a preventive role in the progression of the disease, avoiding the need for invasive oxygen support and mechanical ventilation. A significant reduction in CRP and D-Dimer levels was identified, as well as an increase in the number of lymphocytes and an improvement in hypoxia. The study showed a survival rate of 57% in the group infused with S-CTMs compared to 20% in the control group<sup>51</sup>.

## CONCLUSION

The objective of effective therapy for COVID-19 is based on safety, the potential to inhibit viral replication, in addition to preventing or reversing the condition present in the lung environment. The results presented in the literature so far have demonstrated that infusions of S-CTMs have been shown to be safe and effective in improving hypoxia, restoring immune system function and modulating cytokines in seriously ill patients, which suggests that S-CTMs are a new perspective in the treatment of SARS-CoV-2.

**Author participation:** Enrico Jardim Clemente Santos: Levantamento bibliográfico, redação e revisão. Angela Mazzeo: Levantamento bibliográfico, redação e revisão.

## REFERENCES

1. Munster VJ, Koopmans M, van Doremalen N, van Riel D, de Wit

E. A Novel Coronavirus Emerging in China - Key Questions for Impact Assessment. *N Engl J Med.* 2020;382(8):692-94. Doi: 10.1056/NEJMp2000929.

2. Tyrrell DA, Bynoe ML. Cultivation of viruses from a high proportion of patients with colds. *Lancet*. 1966;1(7428):76-7. Doi: 10.1016/s0140-6736(66)92364-6.
3. Fehr AR, Perlman S. Coronaviruses: an overview of their replication and pathogenesis. *Methods Mol Biol*. 2015;1282:1-23. Doi: 10.1007/978-1-4939-2438-7\_1
4. Chan-Yeung M, Xu RH. SARS: epidemiology. *Respirology*. 2003;8 Suppl(Suppl 1):S9-14. Doi: 10.1046/j.1440-1843.2003.00518.x
5. Yang M, Li CK, Li K, Hon KLE, Ng MHL, Chan PKS, et al. Hematological findings in SARS patients and possible mechanisms. *Int J Mol Med*. 2004;14(2):311-15. doi:[10.3892/ijmm.14.2.311](https://doi.org/10.3892/ijmm.14.2.311)
6. Kahn JS, McIntosh K. History and recent advances in coronavirus discovery. *Pediatr Infect Dis J*. 2005;24(11 Suppl):S223-7, discussion S226. Doi: 10.1097/01.inf.0000188166.17324.60
7. World Health Organization.VPVID-19.
8. Zaki AM, van Boheemen S, Bestebroer TM, Osterhaus AD, Fouchier RA. Isolation of a novel coronavirus from a man with pneumonia in Saudi Arabia. *N Engl J Med*. 2012;367(19):1814-20. Doi: 10.1056/NEJMoA1211721
9. Assiri A, Al-Tawfiq JA, Al-Rabeeh AA, Al-Rabiah FA, Al-Hajjar S, Al-Barrak A, et al. Epidemiological, demographic, and clinical characteristics of 47 cases of Middle East respiratory syndrome coronavirus disease from Saudi Arabia: a descriptive study. *Lancet Infect Dis*. 2013;13(9):752-61. Doi: 10.1016/S1473-3099(13)70204-4
10. World Health Organization. Middle East respiratory syndrome coronavirus (MERS-CoV) [cited 2022 Outubro 28]. <http://www.who.int/emergencies/mers-cov>
11. Lu R, Zhao X, Li J, Niu P, Yang B, Wu H, et al. Genomic characterisation and epidemiology of 2019 novel coronavirus: implications for virus origins and receptor binding. *Lancet*. 2020;395(10224):565-74. Doi: 10.1016/S0140-6736(20)30251-8
12. Wang W, Tang J, Wei F. Updated understanding of the outbreak of 2019 novel coronavirus (2019-nCoV) in Wuhan, China. *J Med Virol*. 2020;92(4):441-7. Doi: 10.1002/jmv.25689
13. Guo YR, Cao QD, Hong ZS, Tan YY, Chen SD, Jin HJ, et al. The origin, transmission and clinical therapies on coronavirus disease 2019 (COVID-19) outbreak - an update on the status. *Mil Med Res*. 2020;7(1):11. Doi: 10.1186/s40779-020-00240-0
14. Wu Z, McGoogan JM. Characteristics of and Important Lessons From the Coronavirus Disease 2019 (COVID-19) Outbreak in China: Summary of a Report of 72 314 Cases From the Chinese Center for Disease Control and Prevention. *JAMA*. 2020;323(13):1239-42. Doi: 10.1001/jama.2020.2648
15. Lauer SA, Grantz KH, Bi Q, Jones FK, Zheng Q, Meredith HR, et al. The Incubation Period of Coronavirus Disease 2019 (COVID-19) From Publicly Reported Confirmed Cases: Estimation and Application. *Ann Intern Med*. 2020;172(9):577-82. Doi: 10.7326/M20-0504
16. Ferguson N, Laydon D, Nedjati-Gilani G, Imai G, Ainslie N, Baguelin K, et al. Impact of non-pharmaceutical interventions (NPIs) to reduce COVID-19 mortality and healthcare demand. Imperial College COVID-19 Response Team. 2020. 16 March. Doi:10.25561/77482
17. Liu Y, Yan LM, Wan L, Xiang TX, Le A, Liu JM, et al. Viral dynamics in mild and severe cases of COVID-19. *Lancet Infect Dis*. 2020;20(6):656-7. Doi: 10.1016/S1473-3099(20)30232-2
18. Wu F, Zhao S, Yu B, Chen YM, Wang W, Song ZG, et al. A new coronavirus associated with human respiratory disease in China. *Nature*. 2020;579(7798):265-9. Doi: 10.1038/s41586-020-2008-3
19. Cui J, Li F, Shi ZL. Origin and evolution of pathogenic coronaviruses. *Nat Rev Microbiol*. 2019;17(3):181-92. Doi: 10.1038/s41579-018-0118-9
20. Su S, Wong G, Shi W, Liu J, Lai ACK, Zhou J, et al. Epidemiology, Genetic Recombination, and Pathogenesis of Coronaviruses. *Trends Microbiol*. 2016;24(6):490-502. Doi: 10.1016/j.tim.2016.03.003
21. Zhou P, Yang XL, Wang XG, Hu B, Zhang L, Zhang W, et al. A pneumonia outbreak associated with a new coronavirus of probable bat origin. *Nature*. 2020;579(7798):270-3. Doi: 10.1038/s41586-020-2012-7
22. Caplan AI, Hariri R. Body Management: Mesenchymal Stem Cells Control the Internal Regenerator. *Stem Cells Transl Med*. 2015;4(7):695-701. Doi: 10.5966/sctm.2014-0291
23. Dominici M, Le Blanc K, Mueller I, Slaper-Cortenbach I, Marini F, Krause D, et al. Minimal criteria for defining multipotent mesenchymal stromal cells. The International Society for Cellular Therapy position statement. *Cytotherapy*. 2006;8(4):315-7. Doi: 10.1080/14653240600855905.
24. Yagi H, Soto-Gutierrez A, Parekkadan B, Kitagawa Y, Tompkins RG, Kobayashi N, et al. Mesenchymal stem cells: Mechanisms of immunomodulation and homing. *Cell Transplant*. 2010;19(6):667-79. Doi: 10.3727/096368910X508762
25. Damania A, Jaiman D, Teotia AK, Kumar A. Mesenchymal stromal cell-derived exosome-rich fractionated secretome confers a hepatoprotective effect in liver injury. *Stem Cell Res Ther*. 2018;9(1):31. Doi: 10.1186/s13287-017-0752-6
26. Julianto I, Rindastuti Y. Topical Delivery of Mesenchymal Stem Cells "Secretomes" in Wound Repair. *Acta Med Indones*. 2016;48(3):217-20.
27. Mitchell R, Mellows B, Sheard J, Antonioli M, Kretz O, Chambers D, et al. Secretome of adipose-derived mesenchymal stem cells promotes skeletal muscle regeneration through synergistic action of extracellular vesicle cargo and soluble proteins. *Stem Cell Res Ther*. 2019;10(1):116. Doi: 10.1186/s13287-019-1213-1
28. Carter K, Lee HJ, Na KS, Fernandes-Cunha GM, Blanco IJ, Djalilian A, et al. Characterizing the impact of 2D and 3D culture conditions on the therapeutic effects of human mesenchymal stem cell secretome on corneal wound healing in vitro and ex vivo. *Acta Biomater*. 2019;99:247-57. Doi: 10.1016/j.actbio.2019.09.022
29. Beer L, Mildner M, Ankersmit HJ. Cell secretome based drug substances in regenerative medicine: when regulatory affairs meet basic science. *Ann Transl Med*. 2017;5(7):170. Doi: 10.21037/atm.2017.03.50
30. Barbas CSV, Matos GFJ. Síndrome do Desconforto Respiratório Agudo: Definição. *Pulmão*. Rio de Janeiro. 2011;20(1) 6p.

31. Ricardo JJ, Ari M. COVID-19 Cytokine storm th interplay between inflamation and coagulation. *Lancet. Respir Med*. 2020;8(6):E46-E47. DOI: [10.1016/S2213-2600\(20\)30216-2](https://doi.org/10.1016/S2213-2600(20)30216-2)
32. Mehta P, McAuley DF, Brown M, Sanchez E, Tattersall RS, Manson JJ. HLH Across Speciality Collaboration, UK. COVID-19: consider cytokine storm syndromes and immunosuppression. *Lancet*. 2020;395(10229):1033-4. Doi: [10.1016/S0140-6736\(20\)30628-0](https://doi.org/10.1016/S0140-6736(20)30628-0)
33. O'Dwyer DN, Gurczynski SJ, Moore BB. Pulmonary immunity and extracellular matrix interactions. *Matrix Biol*. 2018;73:122-34. Doi: [10.1016/j.matbio.2018.04.003](https://doi.org/10.1016/j.matbio.2018.04.003)
34. Breitbart M, Bostani T, Roell W, Xia Y, Dewald O, Nygren JM, et al. Potential risks of bone marrow cell transplantation into infarcted hearts. *Blood*. 2007;110(4):1362-9. Doi: [10.1182/blood-2006-12-063412](https://doi.org/10.1182/blood-2006-12-063412)
35. Liao J, Chen X, Li Y, Ge Z, Duan H, Zou Y, et al. Transfer of bone-marrow-derived mesenchymal stem cells influences vascular remodeling and calcification after balloon injury in hyperlipidemic rats. *J Biomed Biotechnol*. 2012;2012:165296. Doi: [10.1155/2012/165296](https://doi.org/10.1155/2012/165296)
36. Toh WS, Lai RC, Hui JHP, Lim SK. MSC exosome as a cell-free MSC therapy for cartilage regeneration: Implications for osteoarthritis treatment. *Semin Cell Dev Biol*. 2017;67:56-64. Doi: [10.1016/j.semcdb.2016.11.008](https://doi.org/10.1016/j.semcdb.2016.11.008)
37. Damania A, Jaiman D, Teotia AK, Kumar A. Mesenchymal stromal cell-derived exosome-rich fractionated secretome confers a hepatoprotective effect in liver injury. *Stem Cell Res Ther*. 2018;9(1):31. Doi: [10.1186/s13287-017-0752-6](https://doi.org/10.1186/s13287-017-0752-6)
38. Cunningham CJ, Redondo-Castro E, Allan SM. The therapeutic potential of the mesenchymal stem cell secretome in ischaemic stroke. *J Cereb Blood Flow Metab*. 2018;38(8):1276-92. Doi: [10.1177/0271678X18776802](https://doi.org/10.1177/0271678X18776802)
39. Bochon B, Kozubska M, Surygała G, Witkowska A, Kuźniewicz R, Grzeszczak W, et al. Mesenchymal Stem Cells-Potential Applications in Kidney Diseases. *Int J Mol Sci*. 2019;20(10):2462. Doi: [10.3390/ijms20102462](https://doi.org/10.3390/ijms20102462)
40. Liang B, Chen J, Li T, Wu H, Yang W, Li Y, et al. Clinical remission of a critically ill COVID-19 patient treated by human umbilical cord mesenchymal stem cells: A case report. *Medicine (Baltimore)*. 2020;99(31):e21429. Doi: [10.1097/MD.00000000000021429](https://doi.org/10.1097/MD.00000000000021429)
41. Leng Z, Zhu R, Hou W, Feng Y, Yang Y, Han Q, et al. Transplantation of ACE2<sup>+</sup> Mesenchymal Stem Cells Improves the Outcome of Patients with COVID-19 Pneumonia. *Aging Dis*. 2020;11(2):216-28. Doi: [10.14336/AD.2020.0228](https://doi.org/10.14336/AD.2020.0228)
42. Zhu YG, Feng XM, Abbott J, Fang XH, Hao Q, Monsel A, et al. Human mesenchymal stem cell microvesicles for treatment of Escherichia coli endotoxin-induced acute lung injury in mice. *Stem Cells*. 2014;32(1):116-25. Doi: [10.1002/stem.1504](https://doi.org/10.1002/stem.1504)
43. Morrison TJ, Jackson MV, Cunningham EK, Kissenpfennig A, McAuley DF, O'Kane CM, et al. Mesenchymal Stromal Cells Modulate Macrophages in Clinically Relevant Lung Injury Models by Extracellular Vesicle Mitochondrial Transfer. *Am J Respir Crit Care Med*. 2017;196(10):1275-86. Doi: [10.1164/rccm.201701-0170OC](https://doi.org/10.1164/rccm.201701-0170OC)
44. De Castro LL, Xisto DG, Kitoko JZ, Cruz FF, Olsen PC, Redondo PAG, et al. Human adipose tissue mesenchymal stromal cells and their extracellular vesicles act differentially on lung mechanics and inflammation in experimental allergic asthma. *Stem Cell Res Ther*. 2017;8(1):151. Doi: [10.1186/s13287-017-0600-8](https://doi.org/10.1186/s13287-017-0600-8)
45. Broekman W, Khedoe PPSJ, Schepers K, Roelofs H, Stolk J, Hiemstra PS. Mesenchymal stromal cells: a novel therapy for the treatment of chronic obstructive pulmonary disease? *Thorax*. 2018;73(6):565-74. Doi: [10.1136/thoraxjnl-2017-210672](https://doi.org/10.1136/thoraxjnl-2017-210672)
46. Fujita Y, Kadota T, Araya J, Ochiya T, Kuwano K. Clinical Application of Mesenchymal Stem Cell-Derived Extracellular Vesicle-Based Therapeutics for Inflammatory Lung Diseases. *J Clin Med*. 2018;7(10):355. Doi: [10.3390/jcm7100355](https://doi.org/10.3390/jcm7100355)
47. Alcayaga-Miranda F, Cuenca J, Khoury M. Antimicrobial Activity of Mesenchymal Stem Cells: Current Status and New Perspectives of Antimicrobial Peptide-Based Therapies. *Front Immunol*. 2017;8:339. Doi: [10.3389/fimmu.2017.00339](https://doi.org/10.3389/fimmu.2017.00339)
48. Sengupta V, Sengupta S, Lazo A, Woods P, Nolan A, Bremer N. Exosomes Derived from Bone Marrow Mesenchymal Stem Cells as Treatment for Severe COVID-19. *Stem Cells Dev*. 2020;29(12):747-54. Doi: [10.1089/scd.2020.0080](https://doi.org/10.1089/scd.2020.0080)
49. Monsel A, Zhu YG, Gennai S, Hao Q, Hu S, Rouby JJ, et al. Therapeutic Effects of Human Mesenchymal Stem Cell-derived Microvesicles in Severe Pneumonia in Mice. *Am J Respir Crit Care Med*. 2015;192(3):324-36. Doi: [10.1164/rccm.201410-1765OC](https://doi.org/10.1164/rccm.201410-1765OC)
50. Putra A, Widyatmoko A, Ibrahim S, Amansyah F, Amansyah F, Berlian MA, et al. Case series of the first three severe COVID-19 patients treated with the secretome of hypoxia-mesenchymal stem cells in Indonesia. *F1000Res*. 2021;10:228. Doi: [10.12688/f1000research.51191.2](https://doi.org/10.12688/f1000research.51191.2)
51. Fathi-Kazerooni M, Fattah-Ghazi S, Darzi M, Makarem J, Nasiri R, Salahshour F, Dehghan-Manshadi SA, et al. Safety and efficacy study of allogeneic human menstrual blood stromal cells secretome to treat severe COVID-19 patients: clinical trial phase I & II. *Stem Cell Res Ther*. 2022;13(1):96. Doi: [10.1186/s13287-022-02771-w](https://doi.org/10.1186/s13287-022-02771-w)

Received: 2023, April 26

Accepted: 2023, December 22