

**STUDY OF THE DISTRIBUTION
OF SODIUM DIATRIZOATE
LABELLED WITH ^{131}I , ON BLOOD,
LIVER AND SPLEEN OF DOGS.**

BENEDICTO WLADEMIR DE MARTIN
Professor Adjunto
Faculdade de Medicina Veterinária e
Zootecnia da USP

MASAO IWASAKI
Professor Livre Docente
Faculdade de Medicina Veterinária e
Zootecnia da USP

JOSÉ MARIA FERNANDES NETO
Físico do Centro de Medicina Nuclear
Faculdade de Medicina da USP

DE MARTIN, B.W.; IWASAKI, M.; FERNANDES NETO, J.M.
Study of the distribution of sodium diatrizoate labelled with ^{131}I ,
on blood, liver and spleen of dogs. *Rev.Fac.Med.vet.Zootec.Univ.*
S.Paulo, 21(2):107-11, 1984.

SUMMARY: The distribution of sodium diatrizoate labelled with ^{131}I , on blood, liver and spleen of dogs, was studied in dogs, though determinations, up to 60 minutes after intravenous injection, of the referred substance. In the blood circulation it was observed a progressive decrease of the contrast medium, but the same fact didn't occur in the liver and spleen, where the administered substance showed constant concentrations. 15 minutes after the injection. Thus renal excretion associated with the parcial retenaion of the contrast medium in the tissues observed in the first 15 minutes, determined different distribution levels, allowing a better radiographic visualization at this time of the liver and spleen as well as the organs of the urinary system.

UNITERMS: Dogs⁺; Radioisotopes⁺; Radiographic contrast;
Sodium diatrizoate; Blood⁺; Liver⁺; Spleen⁺

INTRODUCTION

In the radiodiagnostic study of the urinary system, contrast techniques are usually indicated, and diatrizoate is the most employed among the contrast mediums.

When employed intravenously, this substance is almost totally eliminated by glomerular filtration, admitting that its excretion reaches 65% in two hours, and 88% in six hours (COTRIM¹).

In 1957 MC CHESNEY & HOPPE⁴ in a study about tissue distribution and excretion of sodium diatrizoate in dogs, observed that, injecting 2 ml/kg of the referred substance in a 50% solution, two thirds were excreted in two hours, 88% in six hours and 2% in twenty hours in the feces. In cats, using 0.5 ml/kg, 54% were excreted in an hour, 80% in three hours and 92% in five hours. When discussing tissue distribution in cats, by means of chemical methods, they stated that at intervals of 30 and 60 minutes after injection, sodium diatrizoate was found in high quantities in the muscles, plasma and in small but significant quantities in the liver, kidneys and in the contents of the intestinal tract. These studies by the authors, suggested that the substance would be retained in the extracellular fluid, to be later removed and transported to the kidneys where it would be excreted.

In 1975 FOURNEAUX², using the same contrast agent to study the excretory urography by perfusion in dogs, suggests that the opacifications observed in the liver, spleen and suprarenal gland could just be occasional findings, and that high quantities to the injected contrast agent would bring difficulties to the study of the organs of the urinary system.

On the other hand, studying excretory urography in dogs and cats using 2 ml/kg of sodium diatrizoate 50%, we verified that after 15 minutes of the intravenous injection, we obtained radiographs in which the spleen and liver as well as the organs of the urinary system were more easily visible. This property made it possible to spread this radiographic technique to be used as an auxiliary method of study of a great number of pathologies of the abdominal cavity. In view of these observations, we proposed to study the distribution of sodium diatrizoate labelled ^{131}I in the blood stream, liver and spleen with the objective of determining the behavior of the contrast agent and therefore to elucidate the radiographic findings.

MATERIAL AND METHOD

1. Animals

To make up the group of experimental animals, five dogs, of mixed breed and normal clinical state were selected

and submitted to a water diet during 24 hours. A laxative was administered to promote cleaning of the colon and rectum.

The animals were anesthetized with sodium pentobarbital previously potentialized with xylazine chloridrate, in order to restrain them during the exams.

2. Equipment

The determination of blood concentrations of sodium diatrizoate* labelled ^{131}I was obtained with the spectrometer system, coupled to a well detector.

The graphic outline of the referred drug concentrations, in the liver and spleen was obtained by means of a detection system, associated to a graphic registrar for dynamic function, containing two cylindrical collimators, 5 cm in diameter and 9 cm in depth.

3. Laboratory procedure

After keeping the animals in left lateral recumbency, the collimators were adapted, directing them to the hepatic and splenic regions, after having identified these organs by means of X-rays and abdominal palpation.

Samples of 5 ml of labelled ^{131}I were injected at a medium dose of 7 $\mu\text{Ci/kg}$ of weight.

The samples of 5 ml of blood were collected by cardiac puncture, 5, 15, 30 and 60 minutes after the injection of the radioactive drug, during which period, the graphic outline of the concentrations in the liver and spleen was processed on a paper which moved at a speed of 30 cm/h^{-1} .

RESULTS

The medium levels of the distribution of the contrast agent with ^{131}I in the blood circulation determined 5, 15, 30 and 60 minutes after the intravenous injection, when compared with the standard, were respectively 46.4% ($S = 5.75$), 29.4% ($S = 5.45$), 24.1% ($S = 4.68$) and 16.8% ($S = 2.93$). (Tab. 1)

The graphic outline obtained by means of collimation of the liver and spleen presented similar behavior. The graphic profiles showed the immediate arrival of the contrast agent into these organs, reaching maximum concentrations, approximately one second after the injection. From this point, the decunation of the curves began more sharply in the first five minutes and still lasted for 15 minutes. The interval between the 15 and 60 minutes, showed minimum variations in the curve levels (Fig. 1 and 2).

For comparative analysis of the distribution of the contrast agent labelled ^{131}I in percentual levels in the

blood, we represented graphically the above results transforming the values found in the graphic outlines, and superposing then to those obtained in the liver and spleen of animal n^o 5, used as standard. (Fig. 3)

DISCUSSION

The opacifications of the organs of the abdominal cavity explored by us in previous research (IWASAKI³), as well as those mentioned by FOURNEAUX², occurred because of the distribution of the contrast agent in several tissues, although the frequent indication in X-ray exams is due to its property of being rapidly eliminated by the kidneys (COTRIM¹). The results of this research coincided with the observations of MC CHESNEY & HOPPE⁴, as the medium levels of contrast agent distribution in the blood stream reflected the speed of its renal excretion. With regards to the liver and spleen, the graphic outlines showed a partial retention of contrast in these organs, which in the opinion of these authors took place at the level of extracellular fluid.

When we check the graphic curves of the results referring to the blood and tissue distribution, we notice and accentuated fall in the contrast concentrations in the blood from the maximum concentration point up to the first 5 minutes. But, when we check the graphic curves of the distribution of the labelled contrast agent in the liver and spleen after 10 minutes, these curves fall discreetly up to the end of the experiment. These observations have permitted us to suggest that in X-rays taken 15 minutes after the contrast injection, the mechanisms involving excretion by the kidneys during this period of time determine different level distributions, so as to allow better visualization of the liver and spleen, apart from the organs of the urinary system.

DE MARTIN, B.W.; IWASAKI, M.; FERNANDES NETO, J.M.
Estudo sobre a distribuição sanguínea, hepática e esplênica do 3,5-diacetamido-2,4,6-tri-iodo benzoato de sódio marcado com ^{131}I , em cães. *Rev.Fac.Med.vet.Zootec.Univ.S.Paulo*, 21 (2):107-11, 1984.

RESUMO: Estudou-se a distribuição sanguínea, hepática e esplênica do 3,5-diacetamido 2,4,6-tri-iodo benzoato de sódio marcado com ^{131}I , em cães, com determinações até 60 minutos após a injeção endovenosa da referida substância, usualmente empregada como contraste radiográfico. Na corrente sanguínea observou-se decréscimo progressivo da concentração do contraste, não ocorrendo o mesmo no fígado e baço, onde a substância administrada mostrou concentrações constantes após 15 minutos da injeção. Assim, a

*Hypaque 50% - Winthrop products Inc.

excreção pelos rins, associada à retenção parcial do contraste nos tecidos, observadas nos primeiros 15 minutos, determinaram níveis de distribuição diferentes, de forma a proporcionarem melhor visibilização nas radiografias efetuadas nesse tempo, do fígado, do baço,

além dos órgãos do sistema urinário.

UNITERMOS: Cães⁺; Radioisótopos⁺; Contraste radiográfico; Diatrizoato de sódio; Sangue; Fígado; Baço⁺

TABLE 1 – Level determinations (in percentage) of blood distribution in mixed breed dogs of sodium diatrizoate labelled ^{131}I , at 5, 15, 30 and 60 minutes after intravenous injection, São Paulo, SP, 1981.

| Animal | Weight (kg) | 5 Minutes | 15 Minutes | 30 Minutes | 60 Minutes |
|-----------------------------|----------------|--------------|---------------|---------------|---------------|
| 01 | 12.4 | 44.4 | 29.1 | 27.8 | 19.1 |
| 02 | 18.7 | 52.1 | 29.5 | 25.1 | 16.1 |
| 03 | 8.5 | 52.6 | 35.7 | 26.7 | 18.8 |
| 04 | 11.0 | 43.5 | 20.9 | 16.0 | 12.0 |
| 05 | 8.5 | 39.4 | 32.0 | 24.8 | 18.0 |
| MEAN | | 46.4 | 29.4 | 24.1 | 16.8 |
| STANDARD DEVIATION | | 5.75 | 5.45 | 4.68 | 2.93 |
| VARIABILITY COEFFICIENT (%) | | 12.39 | 18.54 | 19.42 | 17.44 |

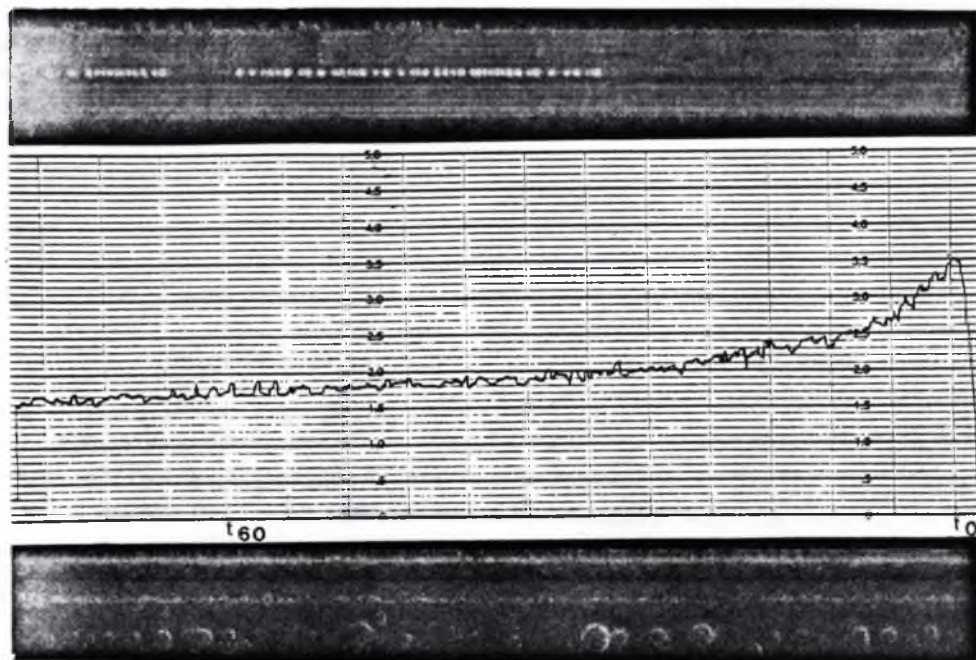


FIGURE 1 – Graphic outline of liver distribution of sodium diatrizoate labelled ^{131}I , during 60 minutes. (animal n^o 5)

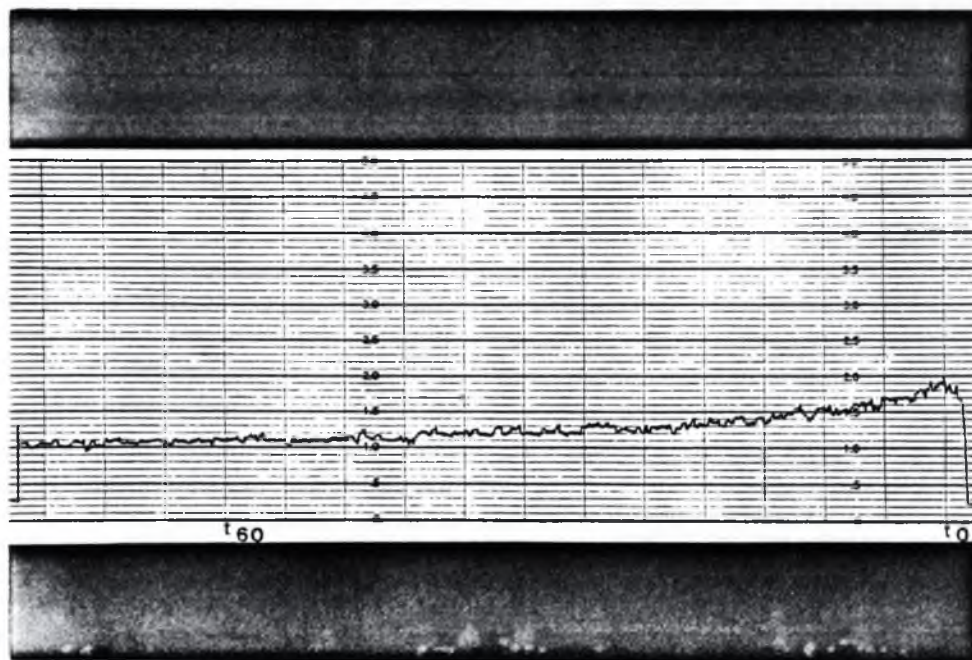


FIGURE 2 – Graphic outline of spleen distribution of sodium diatrizoate labelled ^{131}I , during 60 minutes. (animal n^o 5)

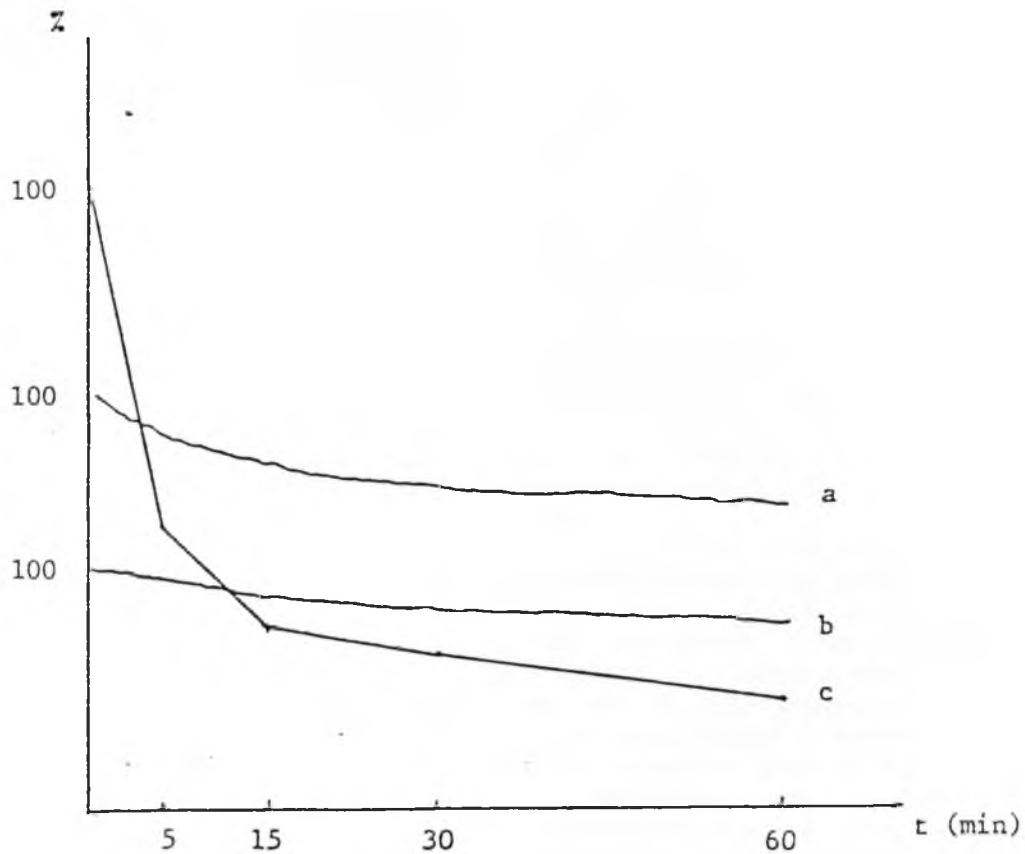


FIGURE 3 – Comparative graphic of levels determination of blood circulation (c) of sodium diatrizoate labelled ^{131}I , during 60 minutes of animal n^o5, superposed to values found in the graphic outlines, obtained in the liver (a) and spleen (b) of the same animal (n^o 5).

BIBLIOGRAPHY REFERENCES

- 1 – COTRIM, E.S. Contrastes radiopacos. In: CORBETT, C.E. *Farmacodinâmica*. São Paulo, Artes Médicas, 1973. p.697-702.
- 2 – FOURNEAUX, E. *Urographie par perfusion chez le chien*. Alfort, 1975. (Thèse pour le doctorat – École Nationale Vétérinaire d'Alfort)
- 3 – IWASAKI, M. Estudo do aparelho urinário e de patologias abdominais em cães e gatos, mediante emprego da urografia excretora. São Paulo, 1977. (Tese de doutoramento – Instituto de Biociências da USP)
- 4 – MC CHESNEY, E.W. & HOPPE, J.O. Studies of the tissue distribution and excretion of sodium diatrizoate in laboratory animals. *Amer. Roentgenol.*, 78:137-44, 1957.

Recebido para publicação em: 16/03/81
Aprovado para publicação em: 01/04/85