

## JORGE LÔBO'S DISEASE. OBSERVATIONS ON ITS EPIDEMIOLOGY AND SOME UNUSUAL MORPHOLOGICAL FORMS OF THE FUNGUS

Leonidas Braga DIAS<sup>(1)</sup>, Mário Machado SAMPAIO<sup>(2)</sup> and Domingos SILVA<sup>(3)</sup>

### SUMMARY

Two cases of Jorge Lôbo's disease are described: they were from the same household and from the same locality of the Amazon Region of Brazil. Observations are made on the histology of the lesion and developmental forms of the fungus as seen in histological sections of biopsied material and cultures. The fungus in one of them presented unusual morphological aspects. Infections were established after the inoculation of material into the cheek-pouch of hamsters. The known distribution of the disease (about 69 cases) is mapped throughout the Brazilian Amazon Region.

### INTRODUCTION

While there exist numerous good descriptions of Jorge Lôbo's disease, we feel that the following two case reports may help to broaden our knowledge of the distribution of this interesting mycotic entity within the Amazon Region of Brazil.

Usually, reported cases are isolated ones. Rarely has any reference been made to the epidemiology in respect of human populations or households, with the exception perhaps of the reports of PEREIRA FILHO<sup>13</sup> and MACHADO<sup>10</sup> who discussed such aspects in their descriptions of "Blastomycosis of the Xingu Indians" and "leper of the Caia-bis". The two cases described here are therefore of particular interest in that both were from the same family, living in the same house.

In addition, the following descriptions of growth forms of the fungus as seen in the human tissues and in culture are worthy of note as, to our knowledge, there exist no previous records of this nature.

### CASE REPORT I

On admission, at the Department of Dermatology of the "Faculdade de Medicina da Universidade Federal do Pará", in November 17, 1967, R.M.M., a farmer, was 35 years old, melanodermic, male, married, native of the State of Pará, Brazil and resident at "Vila de Santana do Capim, Município do Capim", State of Pará, Brazil. He dated the onset of this present illness as about twenty years ago, commencing as a small nodule on the dorsal side of the first phalanx of the 3rd finger of the right hand. This lesion grew slowly, coincident with the growth of new nodules in its neighbourhood, until it reached the present size and aspect. From time to time some of the nodules ulcerated.

The dermatological examination revealed a lesion, 4.0 × 3.0 cm in diameter, on the median part of the dorsal side of the right hand and extending to the first phalanx of the third finger. It had a tumourlike, mammillated appearance, resulting from the confluence of hard, brilliant, cheloid nodu-

(1) Seção de Patologia do Instituto Evandro Chagas (FSESP)

(2) Departamento de Histologia e Embriologia

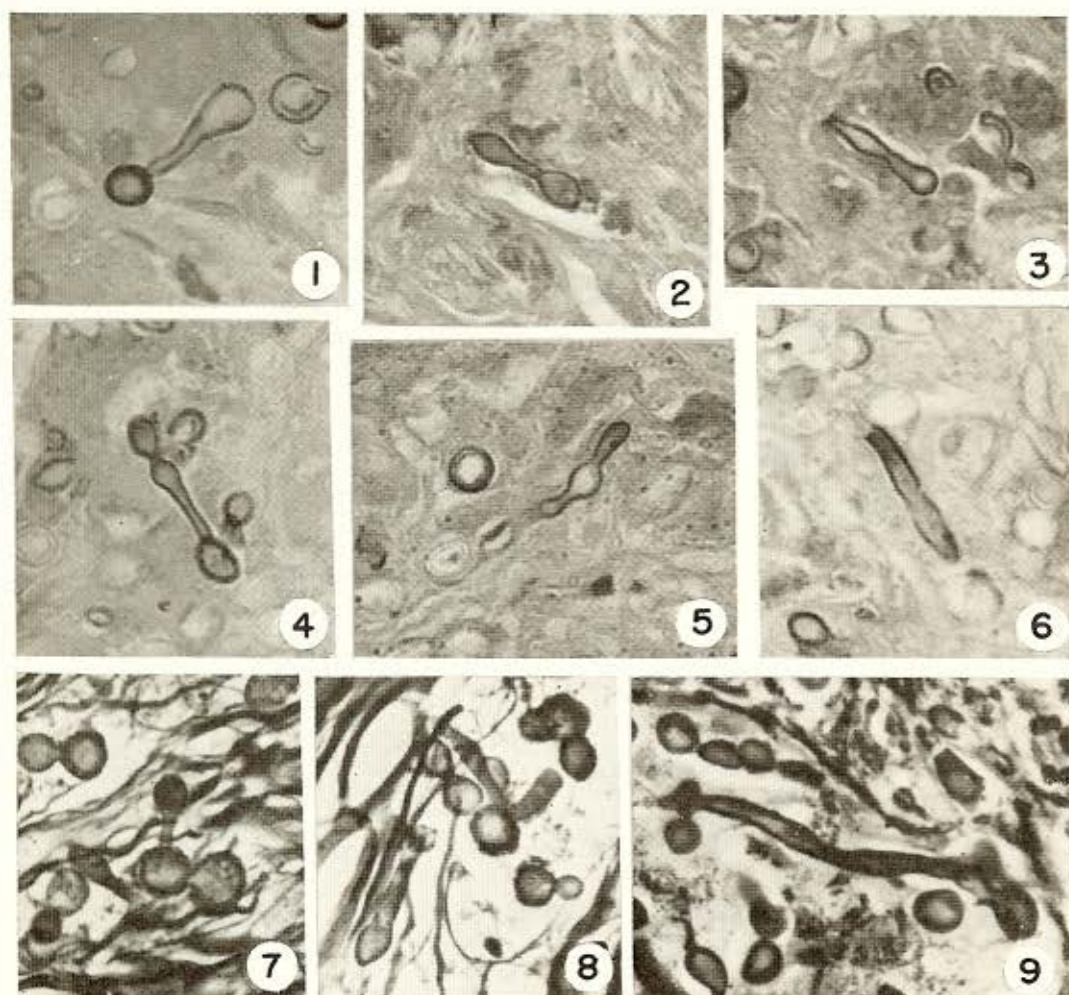
(3) Departamento de Dermatologia da Faculdade de Medicina da Universidade Federal do Pará, Pará, Belém, Brazil

les some of which were ulcerated. A further subcutaneous nodule was located about 6.0 cm above the principal lesion and another was palpated on the superior third on the anterior border of the right forearm. Both nodules, about 1.0 cm long, were firm and movable. Finally, a third hard nodule was also felt about 4.0 cm above the epitrochlea, over the humeral vessels. It was approximately  $1.0 \times 1.5$  cm long.

Diagnosis of Jorge Lôbo's disease was made by the macroscopic appearance of the lesion and confirmed by histological exami-

nation of a biopsy. Sections showed a thin atrophic epidermis with flattened dermal papillae. The superficial and deep derma were substituted by a proliferative process with fibrotic tendencies; it was populated with innumerable histiocytes and giant cells containing fungal elements identical to those known as responsible for Jorge Lôbo's disease. There was a predominance of spherical parasites, sometimes in chains; these possessed a double, refractile wall and were all of approximately the same size. Other "dumbbell", "skittle-shaped" or even more

PLATE I

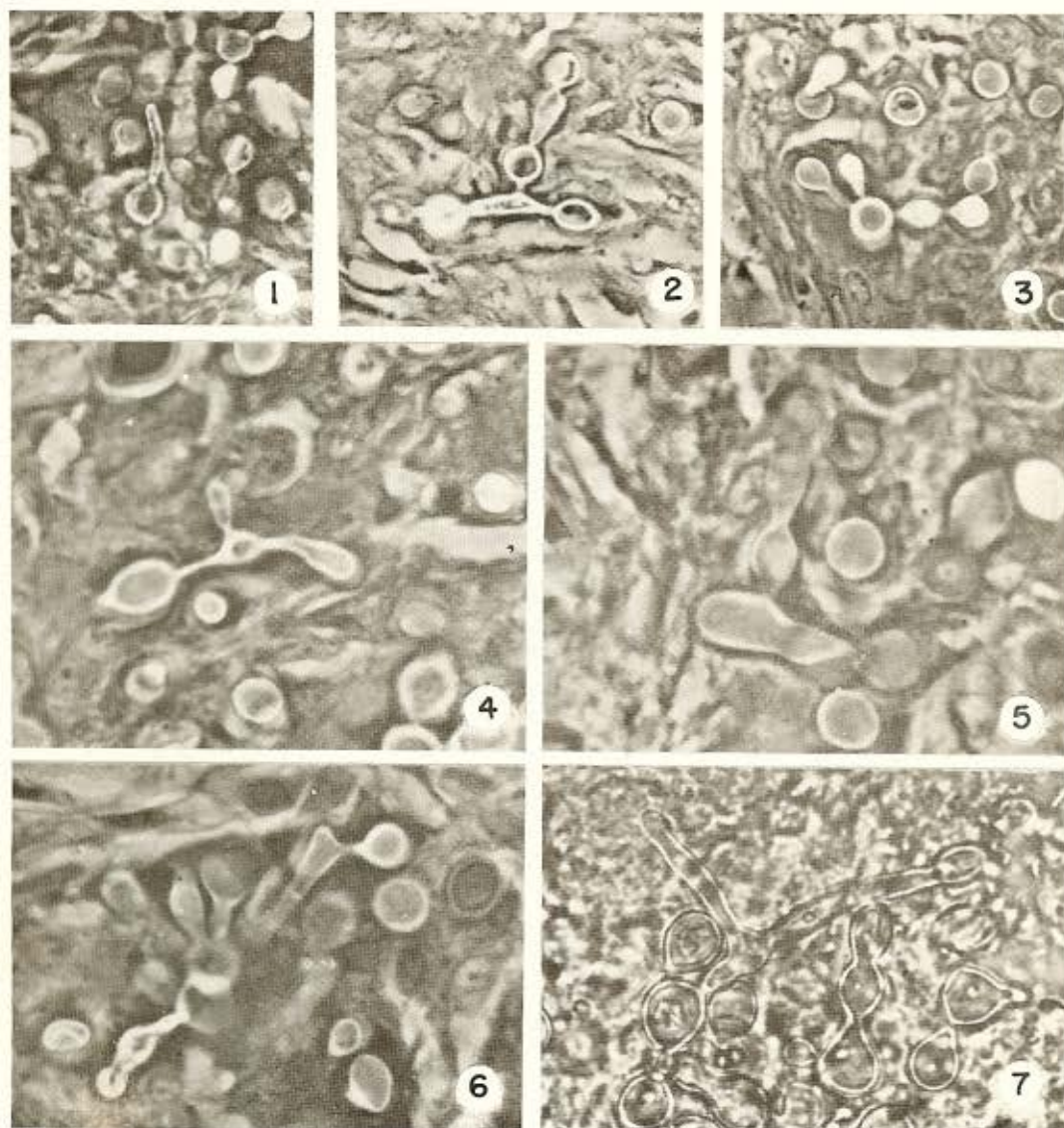


Jorge Lôbo's Disease. Histological sections of human skin lesions showing fungus in the tissue. Figs. 6 to 9: Formation of non-septate hyphae. Gomori's aldehyde fuchsin staining (1 to 6) and Gomori's silver staining (7 to 9). 400  $\times$

bizarre forms were also found (Plate I) and are presumably due to elongation of the round forms. In addition, some parasites were found with non-septate hyphae (Plate I, 6 and 9). Again, multiple budding of the parasites was also noted, with two, three or more rarely four gemmulae of variable size

(Plate II). The accompanying inflammatory process also invaded the subcutaneous tissue. Here, parasitized histiocytes were found singly or in groups in the adipose tissue or areas of this tissue which had already been substituted by the inflammatory process.

PLATE II



Jorge Lôbo's Disease. Histological sections of human skin lesions. Fig. 1: Fungus with developing hyphae. Figs. 2 to 6: Multiple budding and other growth phases. Gomori's aldehyde fuchsin staining (phase microscopy), Figs. 1 to 6. Figs. 1 to 3, 400 $\times$ . Figs. 4 to 6, 560 $\times$ . Fig. 7: Phase microscopy of fresh tissue section showing formation of non-septate hyphae. 560 $\times$ .

Similar findings were noted throughout the entire tumourlike lesion which was removed together with its satellite nodule (followed by successful skin grafting) on February 22, 1968. The satellite nodule proved to be a productive lesion in the adipose tissue with innumerable parasitized histiocytes. Other cells showed clear, foamy cytoplasm containing a "creamy" substance staining metachromatically with Gomori's aldehyde fuchsin. There was a great tendency to fibrosis.

The histology of the nodule of the forearm was similar to that just described. The epitrochlean nodule was found to be a lymph node with its hilum occupied by swollen histiocytes, as described above, and with many containing parasites. In the cortical region there were granulomata with parasitized giant cells, while the marginal sinus showed a few parasitized histiocytes.

Culture of the fungus was tried in SA-BOURAUD-glycose medium with negative results up to 60 days later. Macerates and scrapings of the cut surface of the biopsy, or from the entire removed lesion, were maintained between slides and coverslips in saline plus glycerol (50:50) or coconut water and glycerol (50:50). The cultures

were observed for about three months, at room temperature, and frequently showed growth of the fungus by simple and multiple budding or hyphae formation similar to that seen in sections of the original lesion (Plate III).

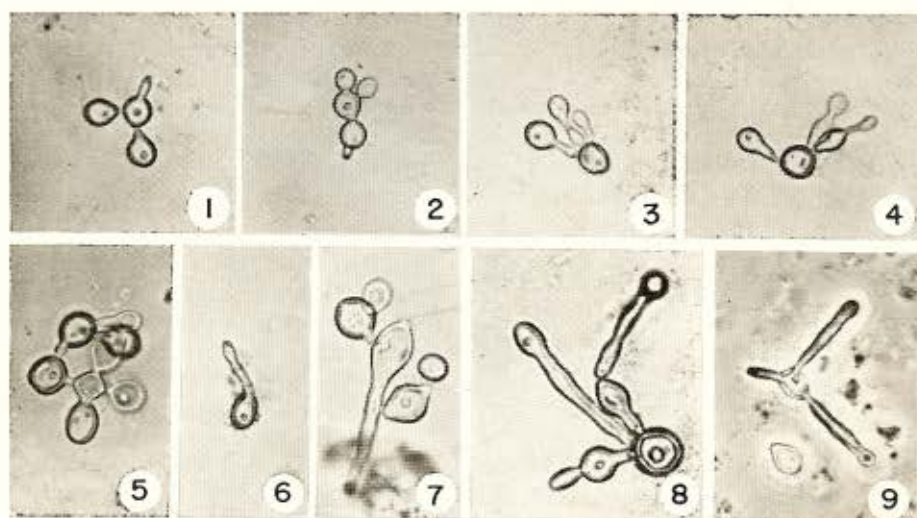
Adult albino mice were inoculated intradermally (foot-pad and ears) and intraperitoneally with material obtained from the main lesion and from the nodules. In addition, three day-old mice received intracerebral and intraperitoneal inoculations of the same suspensions. No evidence of infections was noted up to 60 days later.

Adult hamsters *Mesocricetus auratus* were inoculated subcutaneously into the foot-pad and the ears and also into the lower part of the cheek-pouch. No infections resulted in the foot-pad or ears, but small positive lesions appeared in the cheek-pouch tissue (SAMPAIO and DIAS, in press).

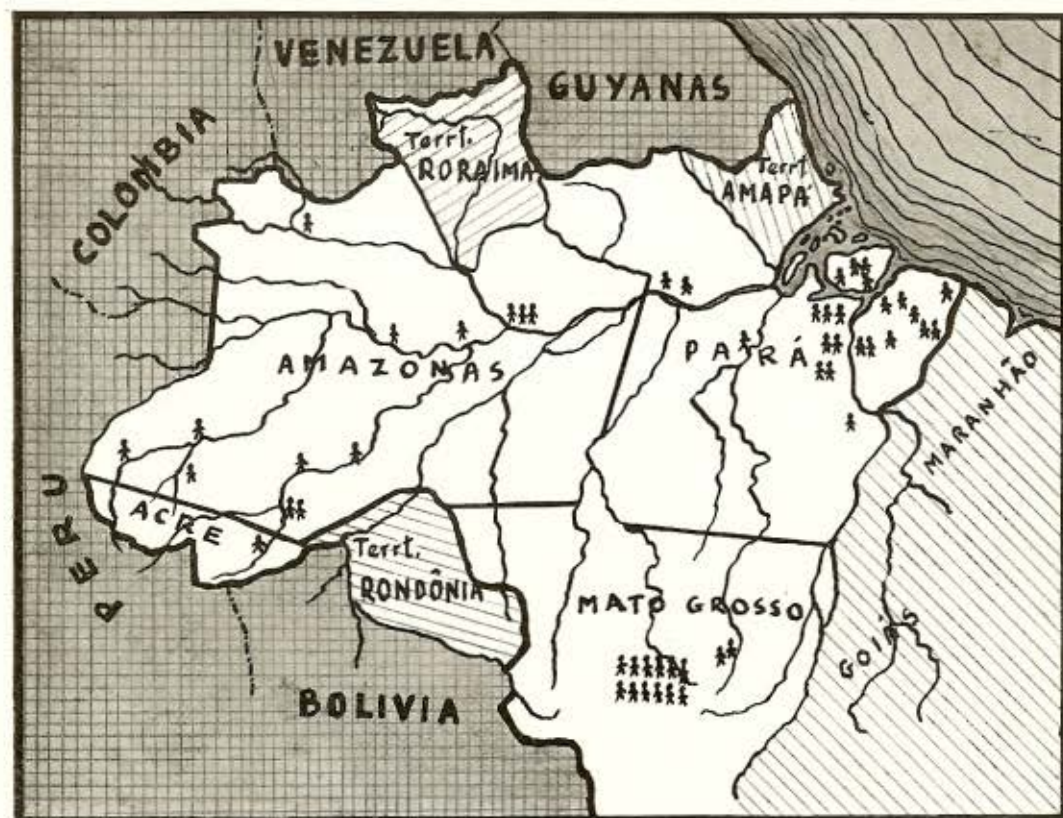
#### CASE REPORT II

On admission on April 25, 1968, at the Department of Dermatology of "Faculdade de Medicina da Universidade do Pará, Belém, Brazil", J.A.S., was a farmer, 40

#### PLATE III



Jorge Lôbo's Disease. Growth phases of fungus maintained in cultures between slide and coverslip, showing multiple budding (except Fig. 6) and hyphae-formation in 6 to 9. Figs. 1 to 3 and 6 and 9, 320 $\times$ . Figs. 4 and 5, 400 $\times$ . Figs. 7 and 8, 480 $\times$ .



Map 1

years old, melanodermic, single, native of the State of Pará, Brazil, and resident at "Vila de Santana do Capim, Município do Campim", State of Pará. He dated the onset of his present illness about 10 years ago. A verrucose lesion, painful to palpation but not itching, appeared on the posterior medial region of the left arm. This small lesion grew slowly into a hard nodule with a brilliant surface. Other similar lesions appeared around the original nodule. A further one developed on the postero-medial region of the right arm, and another in the sacral region.

Our examination revealed a plaque-like lesion on the postero-medial region of the left arm. It measured about  $3.0 \times 3.0$  cm, and was multilobulated, hard, and flat. Small nodules of the same type were scattered around the periphery.

On the postero-medial region of the right arm was another single cheloid lesion measuring about 1.5 cm in diameter and yet another measuring 2.5 cm, in the sacral region. The tributary lymph nodes of the regions showed no alterations at examination.

The lesion of the right arm was removed for microscopic examination. Histological sections showed a markedly atrophic epidermis with ulcerated zones covered by scales of cornified cells and leucocyte-fibrinotic exudate containing parasitic fungus. The superficial dermis was represented by an inflammatory tissue rich in histiocytes and giant cells. These cells were distributed irregularly and without granulomatous aspect. Large collagenous fibres crisscrossed the lesion, with mononucleated cells and plasma cells predominating. The histo-

cytes contained large numbers of fungal elements showing the formation of two, three or more buds. Ovoid parasites were also seen with single protrusions, apparently the beginning of hyphae formation. Longer hyphae were very rarely found.

Adult hamsters were inoculated into the lower part of the cheek-pouch and were sacrificed at intervals up to 150 days. The resulting infections are discussed in the subsequent paper SAMPAIO & DIAS<sup>14</sup>.

#### DISCUSSION

PEREIRA FILHO<sup>13</sup> and MIRANDA (quoted by AZULAY<sup>3</sup>) reported a high incidence of Jorge Lôbo's disease among Indians of the upper Xingu River (Central Brazil), and two of these Indians were taken to the "Carlos Chagas Hospital — Instituto Oswaldo Cruz, Rio de Janeiro", where diagnosis was confirmed. MACHADO<sup>10</sup> described 12 cases which he examined and diagnosed as Jorge Lôbo's disease among the Caiabís Indians (Peixe River, State of Mato Grosso, Central Brazil), and he tried to analyse the epidemiological features of the disease.

Apart from these workers, past Authors have not clearly indicated the exact origin of the cases described and it is difficult to appreciate fully the epidemiology of this disease in the Amazon Region of Brazil. Thus MORAES<sup>12</sup> refers to two cases from the "Município of Manaus" (State of Amazonas) and LEITE<sup>7</sup> describes two cases from the "Município de Baião" (State of Pará). In both reports there are no references to social relations or Kinship between the patients.

In Map 1, therefore, we have tried to map more accurately 52 out of the 69 reported Brazilian cases (SILVA<sup>15, 16</sup>; LÔBO<sup>9</sup>; LEITE<sup>7</sup>; ANDRADE et al.<sup>1</sup>; MICHALANY & LAGO NEGRO<sup>11</sup>). It can be seen that they are largely concentrated in two areas. Climatologically the areas are hot and humid with temperatures varying between 19°C-34°C (average about 24°C and 27°C, respectively). Variations of temperature are greater in the State of Acre, due to the influence of cold waves ("friagem") originating from the Andes.

It is of interest that the two cases reported here were from the same locality (Capim) of the State of Pará. Both were from the village of Santana do Capim, and Case I was married to the sister of Case II and lived in the same house.

There is nothing to indicate how these men may have become infected. The patients deny any traumatic accidents, insect bites or other agent as the starting-point of their lesions which persisted for 20 and 10 years respectively. Their common profession (farmers) gave no clue, nor is there any evidence to suggest that one man may have acquired his infection from the other, although the disease of Case I was 10 years older than that of Case II. The patients know of no other cases in their village. R.M.M. clearly appreciated that his brother-in-law had contracted the same infection and brought him to us for examination.

During its long and protracted evolution, Jorge Lôbo's disease presents a tendency to expansion and recidivation, sometimes involving large cutaneous areas. Unusually there are multiple lesions in distinctly separate areas as well as subcutaneous and lymph-node metastasis, as are observed in the two cases described here. Case I had a definite metastatic tendency, with lymph-node involvement and presence of lesions in the course of lymphatic drainage. Case II, on the other hand, exhibited only superficial lesions in three different parts of the body, and these were no doubt due to direct inoculation of the parasite into the skin at those points. The protracted duration of this disease makes it distinctly possible that transfer was made from one site to the others.

Since the original description of LÔBO<sup>8</sup>, most Authors have noted the characteristic round form of the parasite within the tissues, its relatively constant size and its extraordinary abundance in the lesions. "Dumbell" "chains" and "lemon-shaped" parasites have been described, the first ones generally being regarded as a reproductive form of the parasite. Very rarely (CARNEIRO<sup>4</sup>, LEITE<sup>6</sup>, AZULAY et al.<sup>2</sup>, CORRÊA<sup>5</sup>), references are made to multiple budding, and TEIXEIRA<sup>17</sup> remarks that he never

observed parasites with simultaneous double budding. A fine needle-like striation of the external capsule was observed for the first time by FIALHO (quoted by TEIXEIRA<sup>17</sup>) and confirmed by TEIXEIRA<sup>17</sup>. Distortions due to capsular shrinkage have attracted the attention of many Authors and may account for the "demilune" or "caliciform" shapes sometimes described.

We can find no reference to the forms we have described in Case I, in which some of the parasites showed filamentous hyphae. The apparently greater reproductive capacity of the parasite in the present cases is perhaps a manifestation of a better adaptation of the parasite to its host, or an expression of increased pathogenicity of the fungus. This possibly explains the metastatic tendency of the parasite in Case I and the multiple distribution of lesions in Case II. In spite of this apparent increased reproductive capacity, the parasite could not be grown by the usual culture methods and the cultures between slides and coverslips yielded but meagre results. They did permit, however, observations on the slow growth, and on the reproduction which was similar to that seen in histological sections (Plate III). There is no doubt that the forms seen were derived from parasites morphologically identical to those of the parasite known to cause Jorge Lôbo's disease.

The failure of this fungus to grow in traditional culture media renders its classification difficult and it is hoped that the growth forms described here might contribute something towards the orientation of further studies.

#### RESUMO

*Doença de Jorge Lôbo. Observações epidemiológicas e sobre formas pouco comuns do fungo*

Descrevem-se dois casos da Doença de Jorge Lôbo, pertencentes à mesma família e da mesma localidade da Amazônia Brasileira. Fazem-se observações histológicas da lesão e sobre formas de multiplicação do fungo no material de biopsia e cultura. O parasita em um dos casos apresenta aspectos morfológicos singulares. O material de biopsia inoculado no tecido conjuntivo da

bolsa jugal de hamsters determinou a formação de lesões específicas. Em mapa da Região Amazônica Brasileira mostra-se a distribuição de 69 casos revistos da Doença de Jorge Lôbo incluindo os desta publicação.

#### ACKNOWLEDGMENTS

The Authors wish to express their gratitude to Doctor Ralph Lainson of the Wellcome Parasitology Unit, Instituto Evandro Chagas, Belém, Pará for reviewing the manuscript and for supplying the hamsters used in this work. Thanks are also extended to Mrs. Esmeralda Alfaia Costa for her help in the technical work and to Mr. Candido Paiva Sodr e of the Museu Paraense E. Goeldi for his help with the photographs.

#### REFERENCES

1. ANDRADE, L. M. C.; AZULAY, R. D. & CARNEIRO, J. — Micose de Jorge Lôbo (Estudo Histopatol gico). *Hospital* (Rio) 73:1173-1184, 1968.
2. AZULAY, R. D.; MIRANDA, J. & AZULAY, J. D. — Doen a de Jorge Lôbo (15.º caso da literatura). *Hospital* (Rio) 51:685-691, 1957.
3. AZULAY, R. D. — Caso de doen a de Jorge Lôbo. *An. Brasil. Dermat. Sifil.* 30: 47-48, 1955.
4. CARNEIRO, L. S. — *Contribui o ao estudo microbiol gico do agente etiol gico da doen a de Jorge Lôbo*. Tesis. Recife, Imprensa Industrial, Pernambuco, Brasil, 1952.
5. CORR EA, P. — Blastomycosis queloidiana. *Rev. Latinoamericana Anat. Pat.* 2:139-143, 1958.
6. LEITE, J. M. — *Doen a de Jorge Lôbo (Contribui o ao seu estudo anatomo-patol gico)*. Tesis. Bel m, *Rev. Vet.*, Par , Brasil, 1954.
7. LEITE, J. M. — Doen a de Jorge Lôbo (Estudo cl nico-patol gico, com apresenta o de cinco casos). *Atas do Simp sio s bre a Biota Amaz nica. Patologia* 6:161-176, 1967.
8. L BO, J. — Um caso de blastomicose produzido por uma esp cie nova, encontrado em Recife. *Rev. M d.* (Pernambuco) 1:763-765, 1931.

---

DIAS, L. B.; SAMPAIO, M. M. & SILVA, D. — Jorge Lôbo's disease. Observations on its epidemiology and some unusual morphological forms of the fungus. *Rev. Inst. Med. trop. São Paulo* 12:8-15, 1970.

---

9. LÔBO, J. — Blastomicose queloidiforme. Doença de Jorge Lôbo. *J. Brasil. Med.* 11: 120-137, 1966.
10. MACHADO, P. A. — Contribuição para o estudo da epidemiologia da Blastomicose queloidiana de Jorge Lôbo. XVI Congr. Brasil. Higiene. Curitiba, Paraná, Brasil, 1967.
11. MICHALANY, J. & LAGO NEGRO, B. — Corpos asteróides na Blastomicose de Jorge Lôbo. A propósito de um novo caso. *Rev. Inst. Med. trop. São Paulo* 5:33-36, 1963.
12. MORAES, M. A. P. — Blastomicose tipo Jorge Lôbo (6 casos novos encontrados no Estado do Amazonas; Brasil). *Rev. Inst. Med. trop. São Paulo* 4:187-197, 1962.
13. FERREIRA Filho, M. J. — Os fungos da Doença de Adolpho Lutz, da Doença de Jorge Lôbo e o da Blastomicose dos índios do Alto Xingu. *Rev. Med.* (Rio Grande do Sul) 14:10-65, 1957.
14. SAMPAIO, M. M. & DIAS, L. B. — (In press).
15. SILVA, D. — Oito casos novos da micose queloidiforme de Jorge Lôbo. *Anais Brasil. Dermat.* 40:307-326, 1965.
16. SILVA, D. — Personal information, 1968.
17. TEIXEIRA, G. A. — Doença de Jorge Lôbo. Aspectos microscópicos. *Hospital* (Rio) 62:813-827, 1962.

---

Recebido para publicação em 27/8/1969.