

II — THE AVIRULENCE OF THE CULTIVATED Y STRAIN OF *TRYPANOSOMA CRUZI*

Humberto MENEZES (1)

SUMMARY

The Author tries to demonstrate through a new series of experiments in mice that the cultivated Y strain of *Trypanosoma cruzi* loses its disease-producing capacity.

INTRODUCTION

In a previous paper⁷ we have shown the incapability of an avirulent (cultivated) Y strain of *Trypanosoma cruzi* to induce experimental trypanosomiasis in laboratory animals.

We will try to bring more evidence of that avirulence through a new series of experiments that will be described in this paper.

MATERIAL AND METHODS

1) Ten white mice with a mean body weight of 12 g received, each, by intramuscular route, every 3 days, 0.001 mg/g of prednisolone (Δ 1,4 — pregnadiene — 11 β , 17 α , 21 triol — 3,20 — dione)*.

Another group of 10 mice, with the same characteristics, was injected only with the steroid.

On the 15th day, these animals received intraperitoneally about $2,2 \times 10^7$ of live trypanosomes from a culture of *T. cruzi*, Y strain, 36 days old, in Packchianian medium.

The parasites were washed several times and finally suspended in saline solution.

Both groups continued to receive every 3 days, the same dose of prednisolone until the 42nd day of the experiment.

Parasites were searched in the blood, in the "vaccinated" group 8, 15 and 30 days after the "vaccination".

Forty five days after the beginning of the experiment a culture of blood and of a macerate of fragments of heart and spleen of each "vaccinated" animal was done in liquid Warren medium.

Fragments of heart and liver from animals of both groups were fixed in 10% formalin for histologic examination.

2) A lot of 10 mice with 12 g of body weight received simultaneously $2,2 \times 10^7$ of live parasites, as in the preceding group, and 0.001 mg/g of prednisolone. The hormone was injected in the same dosage every 3 days until the 30th day.

One control group of 10 mice, with the same body weight, was injected only with the prednisolone in the same manner and dosage.

A blood search for parasites in the "vaccinated" group was done on the 8th and 30th day after "vaccination".

On the 33rd day all the animals were killed by medular section and fragments of the heart and liver were saved for histologic examination.

Presented, partially, before the "V Congresso da Sociedade Brasileira de Medicina Tropical, São Paulo", February 1969.

(1) U.S.P. Departamento de Patologia. Faculdade de Medicina, Ribeirão Preto. São Paulo, Brasil

(*) Deltacortril. Pfizer

3) Ten white mice weighing 12 g each, received a similar dosage of the same "vaccine" used in the previously "vaccinated" groups.

A search for parasites was carried out in the same periods as described above.

Fifteen days after the "vaccination" 0.001 mg/g of prednisolone, was injected into these animals and in 10 more controls, every 3 days, until the 42nd day.

Histologic examination was made from heart and spleen of all the animals from both groups.

4) A group of 20 white mice with 10 g of weight, each, was treated by 0.1 mg/g of prednisolone.

Ten of these mice were injected simultaneously with 4×10^7 live trypanosomes from a culture of the Y strain of *T. cruzi*, 28 days old.

The hormonal treatment was continued in both groups every 3 days at the same dosage until the death of the animals.

Parasites were searched on the 8th and 15th day in the blood of animals of the "vaccinated" lot.

From the control group, 1 animal was killed on the 23th day of the corticoid treatment, while in the "vaccinated" group 2 were killed on the 18th and 2 on the 21st day, by bleeding.

Hemoculture in liquid Warren medium and histologic examination were performed on these animals.

All the other mice died before the 30th day.

5) Twenty mice weighing 10 g each, received by subcutaneous route, 0.1 mg/g prednisolone every 3 days.

After the fifth injection, 10 of the 20 animals were "vaccinated" with 4×10^7 of live cultivated Y strain trypanosomes.

Steroid injections were given to both groups with the same dosage and interval until the death of the animals, with the exception of 1 mouse of the "vaccinated" lot that was killed on the 19th day, for histologic examination.

6) Splenectomy was performed on 21 white male mice with 10 g of body weight.

Six days later, into each of eleven of these mice, 8×10^8 of live cultivated trypanosomes were injected by subcutaneous route.

Ten splenectomized mice were kept as a control over the splenectomy.

Ten normal mice with the same characteristics as above, received the same dose of the same "vaccine" and served as a control over the "vaccine".

A search for parasites in the "vaccinated" animals with and without splenectomy was performed on the 8th, 15th and 30th days.

A culture of blood and macerate of fragments of viscerae was carried out on the 30th day, from each animal of the 2 "vaccinated" groups.

Histologic sections of the heart and liver of the same mice were also examined.

7) a) Five litter mates of normal white mice 1 day old with 1 g of body weight, were inoculated, each, with $3,2 \times 10^6$ of live *Trypanosoma cruzi*, Y strain, from a culture 20 days old, in Packchanian medium. Parasite search by thick drops of blood was done on the 8th and 15th day. After 15 days of the "vaccination" all the animals were bled to death and the serum examined for trypanosomes, following the Strout technique⁵¹. The centrifuged serum was injected (0.1 ml) intraperitoneally into each of five baby mice 1 day old. Fragments of the heart and liver of the animals were fixed in 10% formalin solution for histologic examination. b) Twenty four hours after the inoculation, one of the new baby mice was found dead and partially devoured by the mother. On the 8th day search for parasites was done on the remaining mice, by the technique of the thick drops of blood. On the 15th day a new search was carried out, this time by the Strout technique. Into each 1 day old mouse of a new series, 0.1 ml of the centrifuged serum was injected. c) The third series of baby mice 1 day old was submitted to the same kind of examinations as the previous one and on the 15th day a new group of seven mice 1 day old received each 0.1 ml of the centrifuged serum. Fragments of heart and liver were fixed in 10% formalin solution for histologic sections. d) From this new series of 7 baby mice the mother killed and

ate 4 in the 24 hours that followed the flagellates injection. The remaining 3 had the same treatment as previously described. e) On the 15th day a fifth series of 6 baby mice, 1 day old, was injected, each, with 0.1 ml of the centrifuged serum of the preceding mice, but 14 hours later the mother killed 4 of the 6 little mice.

The two mice that remained alive had the blood examined for parasites on the 8th day, and in the 15th day they were bled to death. The whole blood was cultivated in the Warren liquid medium (3 tubes for each animal). Macerate of fragments of heart, liver and spleen were also cultivated in the same medium.

8) a) Each animal of a group of 6 baby mice, 1 day old, was injected intraperitoneally, with 3.2×10^6 trypanosomes from a culture of *Trypanosoma cruzi*, Y strain, in Packchavian medium. The culture was 20 days old and the parasites were suspended in 0.1 ml of saline solution. A blood examination for parasites was made on the 8th day. On the 15th day Xenodiagnosis (10 triatomid bugs) was done on four of the 6 mice (See 9). All the animals were killed on the 15th day by medular section and the viscerae (heart, liver, spleen) were macerated in saline solution with penicillin and streptomycin. The macerate was centrifuged at low speed while the supernatant was separated and centrifuged at high speed. The sediment was examined for parasites and 0.1 ml was injected into each of 5 mice 1 day old. b) From this new series of five mice only 3 survived the 24 hours that followed the injection. Eight days later a blood search for parasites was done and after 15 days the blood search was repeated this time by the Strout technique. A new macerate of viscerae was made as in the preceding group and 0.1 ml of it was injected into each mouse of another series of 7 baby mice, 1 day old. c) The mother killed 3 of the 7 mice and the remaining 4 were submitted to the same kind of examinations as the animals of the previous group. A new macerate of heart, liver and spleen was prepared and injected into 7 new mice 1 day old. d) From this fourth series of animals only six survived until the 15th day, when a new macerate was made and injected into a new group of 7 mice

1 day old. Parasites were searched in thick drops of blood on the 8th day and by the Strout technique, on the 15th. e) From this fifth and last group only 5 animals survived until the 15th day, when all were bled to death and the whole blood was cultivated in Warren liquid medium (3 tubes for each animal). Fragments of heart, and liver were fixed in 10% formalin for histologic examination.

9) a) The ten triatomid bugs (*Rhodnius prolixus*) that were fed on the blood of the four mice of experiment 8a were examined for trypanosomes 30 days later. The intestinal contents of the bugs were suspended in saline solution with penicillin and streptomycin (penicillin 100 UI, streptomycin/100 mg/ml) and injected into 7 mice 1 day old (0.1 ml to each baby mice). b) From this group only 3 survived after 24 hours and to these a blood search for parasites was done on the 8th day, and on the 15th day a group of 5 nymphs of *R. prolixus* was fed, for 30 minutes, on each animal. c) After a period of 30 days the reduviidae were examined for trypanosomes.

RESULTS

1) All the direct search for parasites in the blood, and cultures of blood and viscerae from the animals of the whole group were negative. The histologic examination demonstrated very slight lympho-histiocytic infiltration in the heart of 80% of the "vaccinated" and prednisolone treated animals, but without parasites. In the liver of the animals of the same group a similar infiltration was observed in 90% of the cases.

In the prednisolone control group the same inflammatory cellular infiltration was found in 40% of the hearts and in 100% of the livers. No mortality was observed in either group during the 30 day period of the experiment.

2) The searches for parasites have all been negative. The histologic sections have shown the same kind of inflammatory infiltration in the heart of 80% and in the liver of 100% of the "vaccinated" mice. No parasites could be detected. In the prednisolone group similar cellular infiltration was seen respectively in 50% and 90% of hearts and livers.

The mortality rate was 10% in the "vaccinated" mice and 20% in the control group. All three animals died from bronchopneumonia.

3) The blood examinations for parasites in the "vaccinated" mice were consistently negative. No mortality was observed in either group during the 45 days period. Histologically only slight histio-lymphocytic infiltration was seen in the hearts of 60% of the "vaccinated" animals and in 100% of the prednisolone control group.

Cellular inflammatory infiltration in the liver was observed in 100% of the animals of both groups but was more intensive in the control mice. No parasites were seen in the heart and liver sections of the "vaccinated" animals.

4) Hemoculture of one of the two animals (21st day) was positive for *Trypanosoma cruzi* and the sediment of the centrifuged culture medium was inoculated into 8 mice 15 days old. The inoculum was 0.1 ml for each animal by intraperitoneal route. No parasites were seen in the blood of these mice on the 8th, 15th and 30th day after the inoculation.

The histologic examination of the heart and liver of the positive animal has shown the same unspecific infiltration by lymphocytes and histiocytes as observed in the control and in the other "vaccinated" groups. No parasites were identified. The search for parasites in all the other animals of the group was always negative. The mortality rate was 100% among the "vaccinated" prednisolone treated mice and 90% among the prednisolone control group.

The hearts of 40% of the animals of the first group presented great acute inflammatory reaction with micro-abscesses (Fig. 1A). No parasites were found.

In the liver the inflammatory infiltration was much more severe (Fig. 1B). The search for parasites was equally negative in the liver.

The same kind of lesions, but less severe, were observed in both heart and liver of the prednisolone control animals.

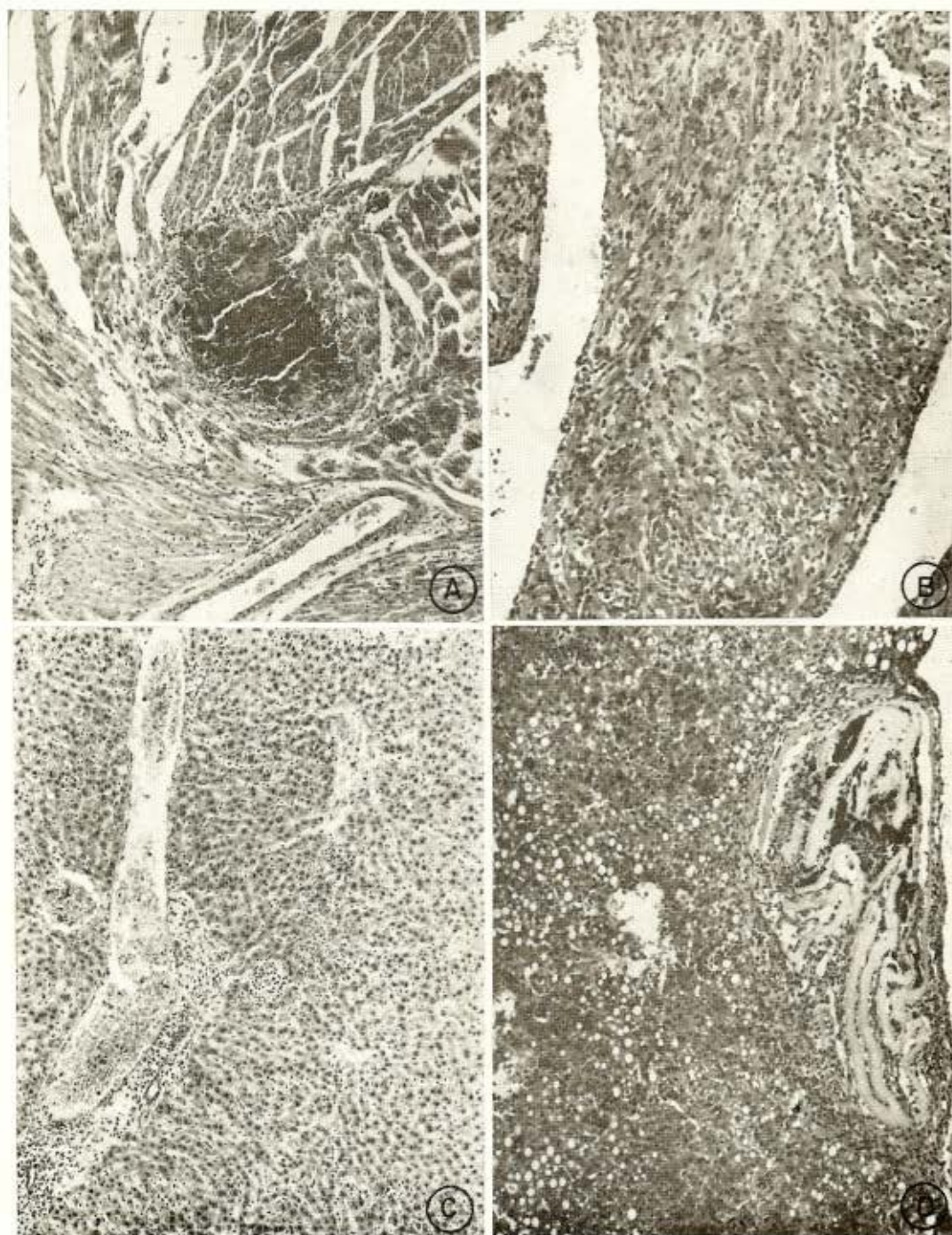
5) The search for parasites were consistently negative and within 20 days all the animals of both group died.

The histopathology of the heart and liver was similar to that of the two previous groups. No parasites could be seen in the "vaccinated" animals.

6) Parasitemias were negative in the two "vaccinated" groups, with and without splenectomy. Cultures of blood and viscerae of the same animals were negative too. Few very small foci of histio-lymphocytic infiltration were seen in the hearts of 45% of the splenectomized-vaccinated mice while in those splenectomized, 80% have shown the same kind of infiltration. The controls of the "vaccine" have had such small heart inflammatory infiltration in 60%. The livers of 80% of the mice of the first group had moderate inflammatory cellular infiltration in the portal spaces and parenchyma and those of the second and third groups 10% and 80% respectively. The mortality rate at the end of the 30th day was 10%, 0% and 10%, respectively for the first, second and third groups.

7) a) Four of the five mice of this group presented negative parasitemias by the Strout technique. One had a positive blood examination for trypanosomes (1 flagellate in 1,000 microscopic fields, oc. 10x obj. 40x). The serum of this animal mixed with those of the other four mice was injected into a new serie of five 1 day old mice. The histologic examination of the heart of the positive animal has shown a very intensive and extensive myocarditis. Parasites were searched for unsuccessfully in serial sections of the organ (Fig. 1C).

In the liver the inflammatory cellular infiltration was equally severe with some degree of parenchymatous steatosis and the presence of remnants of an unidentified parasite (Fig. 1D). No leishmanoids could be seen. In the heart and liver of the other mice only small and scanty foci of lympho-histiocytic infiltration could be detected. b) The parasitemias of all the four remaining mice of this group were negative on the 8th and 15th day. The histologic examination was negative except for few small lympho-histiocytic infiltration foci in the liver parenchyma. c) All the examinations were negative. d) The searches for parasites and the histopathology



Figs. 1 A) — Heart micro-abscess in the mice COR 4A/2, "Vaccinated" and treated with Prednisolone (0.001 mg/g/3 days). The animal died 21 days after the beginning of the corticoid treatment. 125 X. B) — Liver cellular infiltration in the same animal. 125 X C) — Difuse lympho-hystiocitic infiltration in the myocardium of the mice Fr 32A/3, "Vaccinated" with $3,2 \times 10^6$ parasites when 1 day old. No parasites found. Killed at the 15th day. 230 X. D) — Liver of the same mouse with cellular inflammatory infiltration, steatosis and the remnants of an unidentified parasite. 140 X.

were negative in all the animals. e) The parasitemias on the 8th and 15th day were negative as were the cultures of blood and macerate of viscerae on the 15th day.

8) a) The cultures of viscerae and the parasitemias were all negative. b) The same results were obtained in the animals of this group. c) Negative results. d) All the tests were negative. e) The parasitemias and cultures were negative. Histologic examination has shown normal heart and liver.

9) a) The Xenodiagnosis was negative. b) The parasitemias on the 8th and 15th day were negative. c) The last Xenodiagnosis was negative too.

10) a) The ten triatomid bugs (*Rhodnius prolixus*) that were fed on the blood of the four mice of experiment 8a were examined thirty days later for trypanosomes.

The intestinal content of the bugs was negative for parasites, on microscopic examination. Despite this negative result, it was suspended in saline solution with 100 UI penicillin and 100 mg streptomycin per ml, and injected into 7 mice 1 day old, 0.1 ml to each, by peritoneal route. b) The mother killed and devoured 4 of the 7 litters. The remaining 3 had negative parasitemias on the 8th and 15th day when each of them had blood sucked by five nymphes of *R. prolixus* during 30 minutes. c) These bugs were negative for trypanosomes after 30 days.

COMMENTS AND CONCLUSIONS

The important role of the corticosteroids in lowering the resistance of mice and rats to experimental trypanosomiasis has been shown extensively^{1, 5, 9, 14, 16}.

In our experiments, mice "vaccinated" with cultivated Y strain of *Trypanosoma cruzi* and subjected to prednisolone injections prior to, simultaneously with, and after, "vaccination" presented consistent negative parasitemias and cultures, except in one mouse that had a positive hemoculture on the 21st day of "vaccination" but, as in other similar situations^{7, 8} the inoculation of the cultivated trypanosomes into very young mice gave negative results.

The effects of splenectomy in infectious diseases, especially in those produced by

protozoa, are still a matter of dispute but we have shown that splenectomy seems to increase susceptibility of mice to a further infection with a virulent strain of *Trypanosoma cruzi*⁶.

In the present experiment the splenectomy had no effect on the "vaccination" of the animals.

The inoculation of baby mice is well known to every body that works in a Parasitology Laboratory as a very efficient means of obtaining good infections and/or to exacerbate virulence of *Trypanosoma cruzi*.

The sequential inoculations of very young mice with blood or with macerate of viscerae followed by negative xenodiagnosis, culture and parasitemias, seems to us an unquestionable evidence that the cultivated Y strain of *Trypanosoma cruzi* became avirulent in the tested animals.

The one positive hemoculture observed in one mouse did not indicate an active infection since the parasites could not be transferred to other very young mice.

As previously explained^{7, 8} these flagellates certainly represent trypanosomes inoculated as "vaccine", 21 days previously that remained in the blood stream without invading the cells.

It must be emphasized that the number of parasites injected was $3,2 \times 10^6$ per g (an inoculum extremely high) and that the number of parasites in the mouse centrifuged serum was extremely low (1 in 1,000 microscopic fields).

After submitting the Y cultivated strain of *Trypanosoma cruzi* to important tests to exacerbate the virulence of the parasites and/or to decrease the resistance of the vertebrates to them, we can say in conclusion that, at least until now, the parasites had lost their virulence in laboratory animals.

RESUMO

II — A avirulência da cepa Y do *Trypanosoma cruzi*, mantida *in vitro*

O Autor apresenta uma nova série de testes para demonstrar que a cepa Y do *Trypanosoma cruzi* mantida em cultura por longo tempo, perdeu sua virulência para animais de laboratório.

ACKNOWLEDGMENTS

To Dr. Fábio Vicchi for the ECG interpretations, to Dr. Rosa Albuquerque for the cultures and xenodiagnosis examinations and Mrs. Helio R. Rocha and William F. M. Rego for the technical assistance.

REFERENCES

1. AGOSIN, M.; CHRISTEN, R.; JARPA, A. & ATIAS, A. — Cortisona y enfermedad de Chagas experimental. *Biología* 14:29-54, 1951.
2. COURA, J. R.; FERREIRA, L. F.; RUBENS, J.; PEREIRA, N. C. & DA SILVA, J. R. — Trypanosoma do "completo cruzi" em reservatório silvestre no Estado de Guanabara. Estudo de sua patogenicidade. *Rev. Inst. Med. trop. São Paulo* 8:125-133, 1966.
3. GALLIARD, H.; LAPIÈRE, J. & COSTA, M. — Contribution à l'étude d'une souche pathogène de *T. cruzi* (souche Tuiahuén, Chili). II — Prémunition croisée entre souches hétérologues. Revell de l'infection chronique par la cortisone. *Ann. Parasit. Hum. Comp.* 37:504-513, 1962.
4. GLOBE, F. C. & SINGER, I. — The reticuloendothelial system in experimental malaria and trypanosomiasis. *Ann. New York Acad. Sci.* 88:149-171, 1960.
5. JARPA, A.; AGOSIN, M.; CHRISTEN, R. & ATIAS, A. — Ensayos de quimioterapia de la enfermedad de Chagas experimental. VII — Cortisona y Fosfato de Pentaquina. *Bol. Inform. Parasit. Chile* 6:25-27, 1951.
6. MENEZES, H. — Splenectomy and experimental infection of mice by a virulent strain of *Trypanosoma cruzi*. *Rev. Soc. Brasil. Med. Trop.* 3:185-194, 1969.
7. MENEZES, H. — I — The avirulence of the cultivated Y strain of *Trypanosoma cruzi*. *Rev. Inst. Med. trop. São Paulo* 12:64-68, 1970.
8. MENEZES, H. — Active immunization of dogs with a non virulent strain of *Trypanosoma cruzi*. *Rev. Inst. Med. trop. São Paulo* 11:258-263, 1969.
9. NEGhme, A.; BADINEZ, O.; JARPA, A.; THIERMANN, E.; AGOSIN, M. & CHRISTEN, R. — Acción de la cortisona sobre la trypanosomosis chagásica experimental del ratón suprarrenoprivo y total. *Bol. Inform. Parasit. Chile* 7:4-6, 1952.
10. PIZZI, T. & CHEMKE, J. — Acción de la cortisona sobre la infección experimental de la rata por *T. cruzi*. *Biología* 21:31-58, 1955.
11. RUBIO, M. — Acción de la cortisona sobre la virulencia y localización tisular de una nueva cepa de *T. cruzi*. *Biología* 21:75-89, 1955.
12. SENECA, H. & ROCKENBACH, — Fatal *T. cruzi* infection in the white rat. *Science* 116:14-15, 1952.
13. SHERMAN, I. W. & RUBLE, J. A. — Virulent *T. lewisi* infection in cortisone treated rats. *J. Parasit.* 53:258-262, 1967.
14. SNELL, J. F. — The reticuloendothelial system: I. Chemical methods of stimulation of the reticuloendothelial system. *Ann. New York Acad. Sci.* 88:56-77, 1960.
15. STROUT, R. G. — A method for concentrating homoflagellates. *J. Parasit.* 48:100, 1962.
16. WOLF, A.; KABAT, E. A.; BEZER, A. E. & FONSECA, R. C. — Activation of trypanosomiasis in rhesus monkeys by cortisone. *Fed. Proc.* 10:375, 1951.

Recebido para publicação em 31/7/1969.