

FATAL MUMPS MENINGOENCEPHALITIS. ISOLATION OF VIRUS FROM HUMAN BRAIN (CASE REPORT)

Cid Vieira Franco de GODOY, Thales de BRITO, Arary da Cruz TIRIBA
and Claudio Mendes de CAMPOS

SUMMARY

Recovery of mumps virus from human brain collected at necropsy from patient with a rare case of fatal mumps meningoencephalitis is reported. Pathological alterations of various organs in this disseminated infection are described. Isolation of mumps virus directly from human brain suggests direct activity of the potentially neurotropic agent on CNS.

INTRODUCTION

Central nervous system is frequently involved in mumps virus infection (BANG & BANG¹). This involvement can develop meningoencephalitis and cases of such condition have been reported (DONAHUE³, GODOY et al.⁵, LENNETTE et al.⁷, RITTER¹¹, THOMAS & SASLAW¹⁴). Mumps virus has been isolated from cerebrospinal fluid (MEYER⁹, GODOY et al.⁵) but not reported directly from human brain. CHU et al.² isolated the virus from monkey brain following experimental infection by parotid duct injection, suggesting therefore that the virus could also be found in human brain. However, there still remains an overt question whether nervous system involvement is due to the agent "per se" or to an auto-immune mechanism, as pathological findings are similar to lesions encountered in allergic meningoencephalitis.

The purpose of this paper is to describe isolation of mumps directly from human brain from a fatal case of disseminated mumps virus infection.

MATERIAL AND METHODS

1) *Case report* — The patient, a 20 year old man, was admitted at "Emílio Ribas" Hospital with a history of bilateral parotitis,

persisting for 15 days and high temperature for 7 days. At admission, the patient assumed a passive attitude, partially conscious, presenting toxemia, 39°C temperature, 14 × 10 cm of Hg arterial pressure, bilateral orchitis, discrete meningeal signs and hipotonic reflexes. Clinical diagnosis was mumps meningoencephalitis. Clinical course was fulminating with coma and death within three days after admission.

Cerebrospinal fluid cell count revealed 85 lymphocytes per mm³ and a glucose of 61 mg per cent. Bacteriological examination of cerebrospinal fluid sediment and cultures for bacteria, including *Mycobacterium tuberculosis* and fungus were negative.

Post mortem examination was performed 4 hours after death and specimens from brain and testis were collected for virus isolation.

2) *Isolation test* — A 10% triturated brain suspension in Hanks solution was centrifuged at 4°C for 20 minutes at 3,000 rpm and the supernatant was again centrifuged at 25,000 rpm for 30 minutes at 4°C. Supernatant and sediment of the first and second centrifugations received an antibiotic solution so that each milliter of the suspensions contained 5 micrograms of Amphotericin B, 100 units of cristaline penicillin and 100 micrograms of Streptomycin.

These four suspensions were inoculated in amniotic sac of 10 days old embryonated hen's eggs, 10 eggs for each suspension. After 5 days at 36°C, amniotic fluid was collected from all surviving eggs (previously chilled 18 hs at 4°C) and titrated for hemagglutinating activity with a 1% chick red cell suspension. Five serial passages in amniotic fluid were tried before discarding any material as negative.

A separate compartment in our laboratory was reserved exclusively for the present isolation procedures. All other virus activities were interrupted in this compartment while isolation was being tried.

3) *Serologic tests* — Identification of isolated hemagglutinating agent was performed by hemagglutinating inhibition tests (GODOY³) with polyethylene batoques in plastic plates (MONTEIRO & PEREIRA¹⁰). Tests were done with rabbit mumps immune serum, comparing simultaneously Enders strain of mumps virus, with antigen titrations (isolated agent and ENDERS strain), serum control and red cell control.

RESULTS

1) *Autopsy report* — Only the positive findings will be mentioned. The body was of a well developed and well nourished young man. There was a patchy consolidation of both lungs. Both parotid and submaxillary glands were not enlarged or congested. The brain was edematous and congested weighing 1,575 g. Cervical cord appeared also congested. The pia-arachnoid at the basis of the brain was diffusely opacified.

Both testis were markedly enlarged and cut surface revealed large and confluent streaks of hemorrhage in the swollen parenchyma.

Microscopic examination — Lungs — There were patchy and confluent areas of typical bronchopneumonia. Pancreas exhibited small foci of degenerated acinar cells and no interstitial inflammation. Testis — Both showed extensive areas of hemorrhage and marked lymphocytic and mononuclear cell infiltrate. The contour of the seminiferous

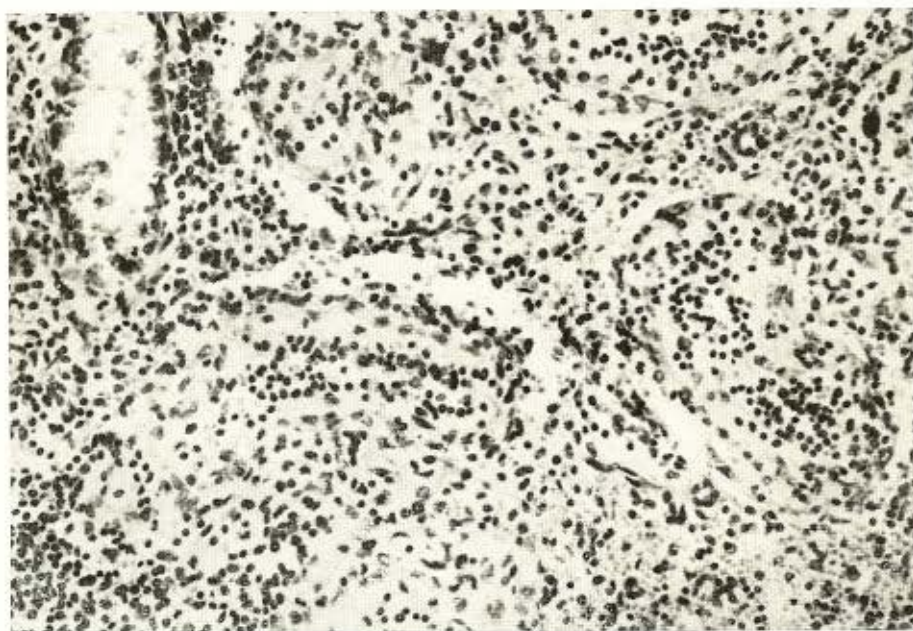


Fig. 1 — Extensive mononuclear interstitial inflammation of the testis. The contour of the seminiferous tubules is still preserved. H.E., 300 ×

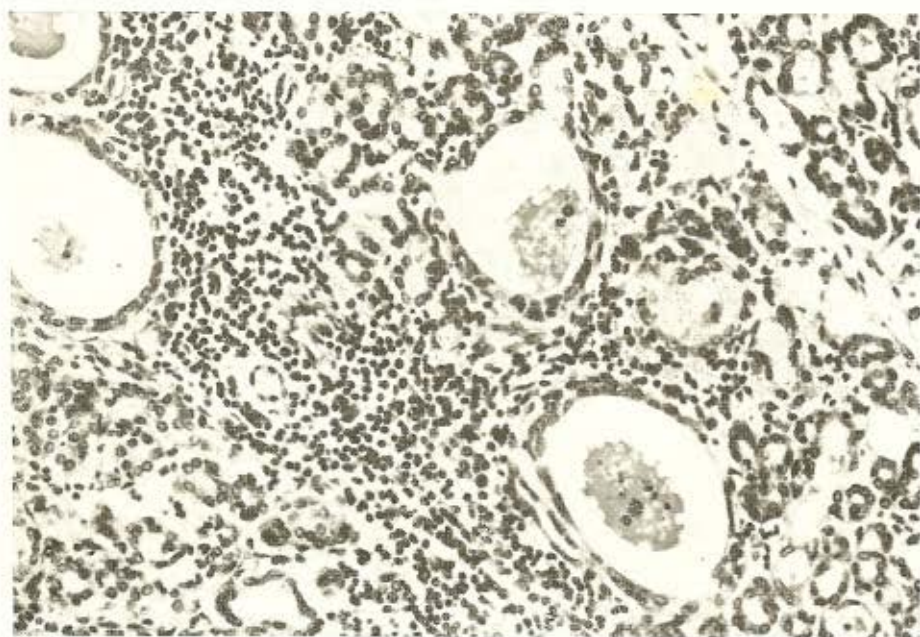


Fig. 2 — Parotid gland showing extensive mononuclear interstitial inflammatory infiltrate around of ducts. Many of them were distended with plugs of inspissated secretion and nuclear debris. H.E., 300 ×

rous tubules were still present but without any germinal activity (Fig. 1).

Parotid gland: There was an extensive interstitial infiltration with lymphocytes and mononuclears (Fig. 2). This was most marked about the ducts, many of which were distended with plugs of inspissated secretion and nuclear debris. The epithelium lining the ducts, although flattened, was intact. The infiltration had resulted in some compression of the acinar tissue, but this tissue did not appear to be extensively involved. In the cytoplasm of the flattened epithelial cells was seen an oval homogeneous basophilic deposition about the size of the nucleus. Such corpuscles were also occasionally observed among the eosinophilic secretion inside the ducts, both by hematoxylin eosin and by a modified eosin stain used for NEGRI bodies in rabies (MASSIGNANI & MALFERRARI⁸).

Brain and cervical cord — There was a moderate diffuse infiltration of the meninges of the brain with lymphocytes and mononuclears (Fig. 3). Throughout the brain but

chiefly at the cerebrum (white matter), basal nuclei, midbrain, pons and the cervical medulla. There were diffuse congestion and interstitial edema, the small vessels exhibiting inflammatory cuffs made up of lymphocytes and mononuclear cells. Small perivascular demyelination with attendant reaction on the part of the glial and mesodermal elements was also seen around the small veins of the white matter (Figs. 3 and 4). Throughout in the brain and cervical cord diffuse and intense glial reaction was seen, with

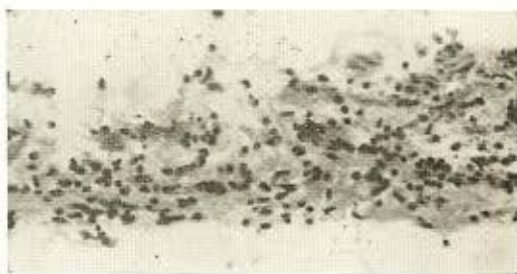


Fig. 3 — Mononuclear inflammatory infiltrate in the meninge. H.E., 300 ×

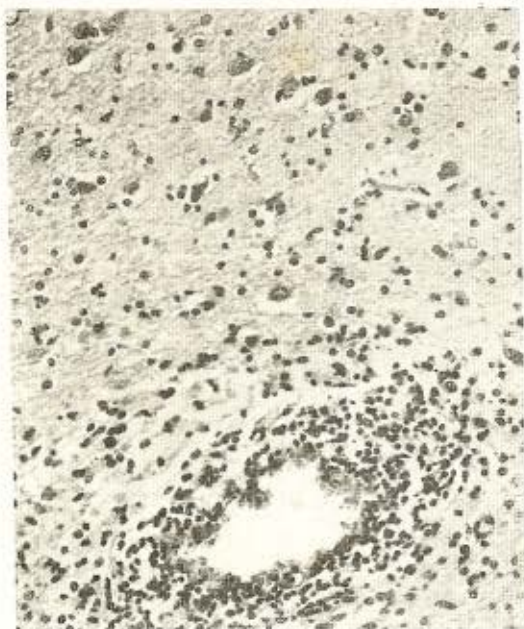

Fig. 4 — Small vessel showing a cuff of mononuclear inflammatory cells and demyelination. Glial reaction, made up mostly of microglial elements, is also seen. H.E., 300 ×

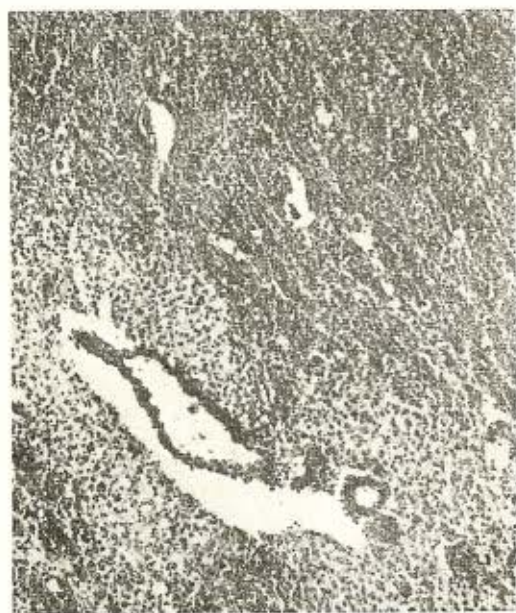

Fig. 5 — Area of demyelination is seen around a vessel of the white matter. Weil stain, 300 ×

a predominance of the microglia. Neurons were not markedly altered.

2) *Virus isolation* — Attempts of virus isolation from three of the four brain suspensions after five serial passages in amniotic fluid were negative. One of the suspensions (supernatant of the first centrifugation) revealed hemagglutination in undiluted amniotic fluid from the second egg passage. Hemagglutination in amniotic fluid diluted $\frac{1}{2}$ and $\frac{1}{4}$ was demonstrated in the third and fourth passages respectively. The fifth egg passage was positive in amniotic fluid diluted $\frac{1}{8}$ and in allantoic fluid diluted $\frac{1}{4}$ and sixth passage allantoic fluid gave $\frac{1}{64}$ hemagglutination titer.

3) *Serologic identification of isolated agent* — Hemagglutination inhibition tests with the isolated agent and ENDERS strain of mumps virus (using 8 units of each virus) revealed identical antigenic behaviour of the isolated virus and mumps virus. Same titers of hemagglutination-inhibition with mumps rabbit serum was obtained with both antigens.

DISCUSSION

Laboratory methods, using virological techniques of isolation and serology have been of great aid in the recognition of involvement of organs other than parotid in mumps virus infection. Meningoencephalitis is considered one of the frequent "complications" of the disease, easily explained by the potentially neurotropic activity of the virus and the systemic character of the disease. Similarity of lesions in the nervous system with those observed in allergic encephalitis (areas of desmyelination of perivascular localization) have supported an auto-immune mechanism theory to explain central nervous disturbances in mumps infection. Experiments on hamsters by JOHNSON⁶ and monkeys by CHU et al.² with recovery of mumps virus from brain tissue, however, has given support to direct action of so-called neurotropic strains of the virus producing meningoencephalitis. Up to date there were no reports of isolation from human brain to strengthen this hypothesis. In the present

case, a rare form of fatal mumps meningoencephalitis with disseminated infection and damage to many organs, virus isolation from human brain has been successful. This fact emphasizes the direct action of the agent on central nervous system. Preliminary identification of the virus does not demonstrate antigenic difference with ENDERS strain of mumps virus. Pathologic alterations were essentially similar to those previously described by DONAHUE³ and SCHWARZ et al.¹³. The findings of an allergic encephalitis could be explained by ROBBINS'¹² and SCHWARZ' et al.¹³ suggestion that the virus invade the central nervous system of specially vulnerable people with the release of unidentified products of damaged neurons or myelin. Such substances act as antigens and result in the formation of antibodies which in turn act in the central nervous system to produce the perivascular demyelination seen in post infectious encephalitis.

CONCLUSIONS

- 1) A virus was isolated from human brain of a patient with fatal mumps meningoencephalitis.
- 2) Identification of the virus by serologic methods did not reveal any difference with ENDERS strain of mumps virus.
- 3) Implications on the direct action theory of mumps virus in meningoencephalitis is discussed.

RESUMO

Meningoencefalite fatal por caxumba. Isolamento do vírus de cérebro humano

Isolamento de vírus da caxumba diretamente do encéfalo humano, a partir de paciente com caso raro de meningoencefalite e infecção disseminada por este agente, é objetivo desta comunicação. Lesões anatomo-patológicas são descritas nos vários órgãos.

Esta primeira descrição de isolamento do vírus de cérebro humano, vem reforçar a

hipótese de ação direta sobre o S.N.C., relegando para plano secundário a suspeita de ação indireta do agente, produzindo "encefalite alérgica".

REFERENCES

1. BANG, H. O. & BANG, J. — Involvement of the central nervous system in mumps. *Acta Med. Scand.* 113:487-505, 1943.
2. CHU, T. H.; CHEEVER, F. S.; COONS, A. H. & DANIELS, J. B. — Distribution of mumps virus in the experimentally infected monkey. *Proc. Soc. Exp. Biol. & Med.* 76:571-574, 1951.
3. DONAHUE, W. L. — The pathology of mumps encephalitis with report of a fatal case. *J. Pediatrics* 19:42-52, 1941.
4. GODOY, C. V. F. de — *Contribution to the Immunology of mumps virus infections*. Doctorate thesis. São Paulo, Faculdade de Medicina da Universidade de São Paulo, Brasil, 1967.
5. GODOY, C. V. F. de; PEREIRA, O. A. de C.; FAVA NETTO, C.; CARVALHO, R. P. de S. & BUENO, A. C. — Aseptic meningitis. Isolation of mumps virus from cerebrospinal fluid and serological study. *Rev. Inst. Med. trop. São Paulo* 11:7-10, 1969.
6. JOHNSON, R. T. — Mumps virus encephalitis in the hamster. *J. Neuropath. Exp. Neurol.* 27:80-95, 1968.
7. LENNETTE, E. H.; CAPLAN, G. E. & MAGOFFIN, R. L. — Mumps virus infection simulating paralytic poliomyelitis; a report of 11 cases. *Pediatrics* 25:788-797, 1960.
8. MASSIGNANI, A. M. & Malferrari, R. — Phosphotungstic acideosin combined with hematoxylin as a stain for Negri bodies in paraffin sections. *Stain Techn.* 36:5-8, 1961.
9. MEYER Jr., H. M.; JOHNSON, R. T.; CRAWFORD, I. P.; DASCOMB, H. E. & ROGERS, N. G. — Central nervous system syndromes of viral etiology. A study of 713 cases. *Amer. J. Med.* 29:334-347, 1960.
10. MONTEIRO, E. V. L. & PEREIRA, O. A. de C. — Polyethylene insert to prepare plates for hemagglutination and complement fixation test. *Rev. Inst. Med. trop. São Paulo* 3:209-212, 1967.

GODOY, C. V. F. de; BRITO, T. de; TIRIBA, A. da C. & CAMPOS, C. M. de — Fatal mumps meningoencephalitis. Isolation of virus from human brain (Case report). *Rev. Inst. Med. trop. São Paulo* 11:436-441, 1969.

11. RITTER, B. S. — Mumps meningoencephalitis in children. *J. Pediat.* 52:424-433, 1958.
12. ROBBINS, F. C. — Evidence for and against the immunologic nature of experimental "allergic" and post-infectious encephalomyelitis. In *Allergic Encephalomyelitis*. KIES, M. W. & ALVORD, E. C. Ed. Springfield, Charles C. Thomas, 1959, pp. 467-483.
13. SCHWARZ, G. A.; YANG, D. C. & NOONE, E. L. — Meningoencephalomyelitis with epidemic parotitis: clinicopathologic report. *Arch. Neurol.* (Chicago) 2:453-462, 1964.

Recebido para publicação em 12/6/1969.