

EXPERIMENTAL LIFE CYCLE OF *LAGOCHILASCARIS MINOR* LEIPER, 1909

Dulcinéa Maria Barbosa CAMPOS(1), Lindomar G. FREIRE FILHA(2), Miguel Alípio VIEIRA(1),
Julieta Machado PAÇÓ(1) & Moacir A. MAIA(1)

SUMMARY

The life cycle of *Lagochilascaris minor* was studied using material collected from human lesion and applying the experimental model: rodents (mice, hamsters), and carnivorae (cats, dogs).

In mice given infective eggs, orally, hatch of the third stage larvae was noted in the gut wall, with migration to liver, lungs, skeletal musculature and subcutaneous tissue becoming, soon after, encysted.

In cats infected with skinned carcasses of mice (60 to 235 days of infection) it was observed: hatch of third stage larvae from the nodules (cysts) in the stomach, migration through the oesophagus, pharynx, trachea, related tissues (rhino-oropharynx), and cervical lymphonodes developing to the mature stage in any of these sites on days 9-20 post inoculation (P.I.).

There was no parasite development up to the mature stage in cats inoculated orally with infective eggs, which indicates that the life cycle of this parasite includes an obligatory intermediate host.

In one of the cats (fed carcass of infected mice) necropsied on day 43 P.I., it was observed the occurrence of the self-infective cycle of *L. minor* in the lung tissues and in the cervical region which was characterized by the finding of eggs in different stages of development, third stage larvae and mature worms.

It's believed that some component of the carnivorae gastrointestinal tracts may preclude the development of third stage larvae from *L. minor* eggs what explains the interruption of the life cycle in animals fed infective eggs. It's also pointed out the role of the intermediate host in the first stages of the life cycle of this helminth.

KEY WORDS: *Lagochilascaris minor*; Experimental life cycle; Transmission mechanisms.

INTRODUCTION

There are five species known as *Lagochilascaris*: *L. minor* Leiper, 1909 found in man, cat and dog; *L. major* Leiper, 1910 and *L. buckleyi* Sprent, 1971 found in wild felidae; *L. turgida* (Stossih, 1902) Travassos, 1924 and *L. sprenti* Bowman et al., 1983 found in marsupials.

From the sanitary medical point of view, *L. minor* is the one that interests the most once it is the etiological agent of human lagochilascariasis.

Several clinical problems are described due to localization of the helminth in different sites, such as: nasal sinus^{2,9,30}, middle ear^{4,7,8,10,19,22,24}, rhino and oropharynx⁴, cervical region^{1,6,8,9,10,12,17,20,23}, sacral region¹⁶, dental alveolus²⁶, lungs^{18,22,25}, and central nervous system^{19,22,25}. Human infection is geographically limited to: Mexico¹⁵, Colombia¹, Venezuela^{22,30}, Costa Rica², Trinidad^{13,23}, Tobago⁹, Surinam²⁰, and Brazil^{4,5,6,7,8,10,11,12,17,18,19,24,25,26} being Brazil

(1) Professors of the Parasitology Department/IPTESP/UFG.

(2) CNPq fellow.

Address for correspondence: Instituto de Patologia Tropical e Saúde Pública/UFG. Caixa Postal 131. 74.000. Goiânia, GO, Brasil.

the leading country in the world with 74.2% of the cases¹¹. There are still doubts about the identification of the natural reservoirs of this parasite from unquestionable wild origin and pathogenic to man. Hypothesis have been formulated^{10,27,29}, and experiments have been developed^{3,12,14}, in the attempt to clarify its mechanisms of transmission and its life cycle.

These aspects related to the lack of knowledge about the biology of *L. minor* have led us to write the present paper. For the first time the experimental life cycle of this helminth is reported, after successive passages through intermediate and definite host, having as a starting point material from human origin.

MATERIALS AND METHODS

Parasites

Uterine eggs collected from female *L. minor* obtained from patients (named A.C.S., 22 years old and H.G.S., 11 years old, from Conceição do Araguaia and Marabá-PA, respectively) were maintained in culture in formaldehyde solution at 1% at room temperature for 30 days so that the infective larvae could develop. This suspension of embryonated eggs was transferred to graduate centrifuge tubes and after regulating the volume, three equal amounts of 0,001ml were drawn out and the eggs counted on microscopic slides, to determine the concentration of eggs per ml.

Animals

Ninety mice, male and female inbred C57BL/6, one hamster (*Cricetus cricetus*), forty seven cats (*Felis domestica*) and one dog (*Canis familiaris*) were used. The forty seven cats were divided into two sub-groups: Group 1 (G1) represented by forty three cats and Group 2 (G2) by four cats.

Experimental infection

Each rodent was infected, orally, with 1000 embryonated eggs. The mice were examined at 4, 6, 7.5, 12, 24 hr. P.I., daily until day 8 P.I. and monthly until day 235 P.I., making a total of 90 animals. The hamster's analysis was performed on day 325 P.I.

Forty-three cats from sub-group G1 were fed with carcasses of infected mice receiving each animal 40 to 85 nodules containing larvae

of *L. minor* encysted in the skeletal musculature, sub-cutaneous tissue or in the rodent's viscera. These cats were examined at 3, 6, 12, 24 hr. P.I., daily until day 20 P.I. and at different intervals until day 76 P.I. Aside from the others, one cat was infected skinned mice carcasses containing 135 nodules of *L. minor*.

Each animal of sub-group G2 received orally 2000 infective eggs. The animals of this sub-group were examined on days 1, 4, 37 and 41 P.I.

The dog was infected with skinned mice carcasses containing 78 encysted larvae and examined on day 74 P.I.

Necropsies

All the animals were killed by anaesthesia of ether or chloroform. The tissues from the digestive, circulatory, respiratory, urinary, and genital systems, in addition to the skeletal muscles, subcutaneous tissues, brain and lymphatic ganglions were thoroughly examined. The tissues which presumably harboring recent infections (around 2 weeks) were cut with scissors being one part examined by pressing them into two glass slides and the other part submitted to the BAERMANN-MORAES' method. In order to make researches on the encapsulated larvae, animal tissues harboring older infections were submitted to histological sections of material collected and stained with Hematoxilin-Eosin, or nodules were counted by observing viable larvae.

Larvae and adult worms recovered from animals were fixed in hot 10% formolsaline then processed in acetic acid, and in Faia creosote.

Measuring

Measuring was made through the micrometrical technique when adult worms, eggs, and developing larvae were outlined by means of the clear chamber. The figures could be measured through the micrometrical scale shown on the slide.

RESULTS

Rodents' Infection: Migration and Description of Third Stage Larvae.

In mice given infective eggs of *L. minor* hatch of larvae was noted in the gut wall around

4 hr P.I., and migration to the liver beginning at 6 hr P.I., and to the lungs around 24 hr P.I. Within 72 to 96 hr there was an outstanding reduction in number of larvae in the liver and a considerable increase of the same in the lungs. Third stage larvae recovered from the liver and lungs of mice, examined 24 to 48 hr P.I., are similar morphologically to those obtained from eggs in culture for 30 days, the only difference being the lack of the two sheaths. After day 7 or 8 P.I., third stage larvae were found almost exclusively in the musculature and subcutaneous tissues, becoming, soon after, encysted (Fig. 1). Fibrous capsules around larvae were noted microscopically being the nodule wall constituted by lymphoplasmocitary infiltrate, epithelioid cells and neutrophils (Fig. 2). Encysted larvae were found in the heart, urinary vesicle, subpleural lung parenchyma (Fig. 3), and among hepatic lobes of infected mice (Fig. 4).

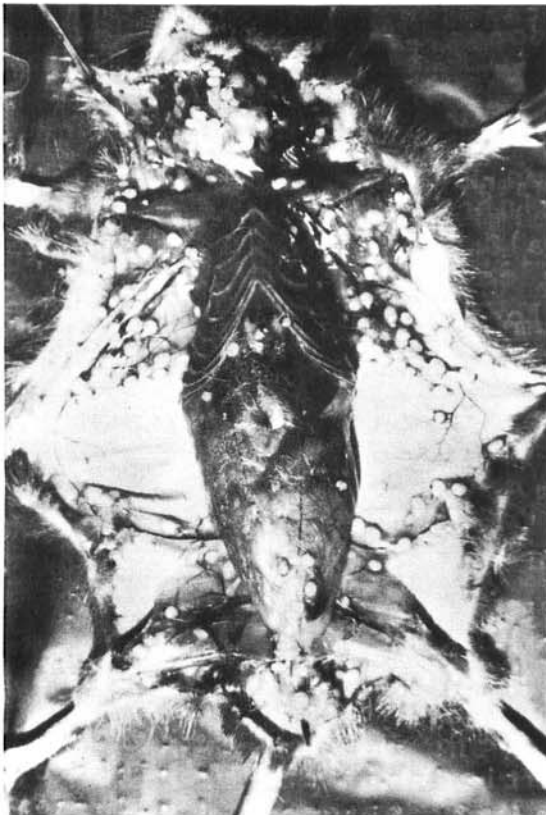


Fig. 1 - Granulomatous nodules containing third stage larvae in the muscles and cellular subcutaneous tissue of a mouse infected with *L. minor* eggs and examined on day 90 P.I.

Third stage larvae recovered from skeletal musculature and subcutaneous tissue of mice on day 96 to 330 P.I., reached a mean length of 8,93mm (Table 1). They presented two small projections on the anterior end, little conspicuous lips (Fig. 5), and did not have post-labial groove or furrow, which is an outstanding feature of a mature worm. The nerve ring is at 0,25mm from the anterior end. The excretory system is represented by the excretory pore, excretory duct and excretory cell, which divides itself into two, one on each side of the body becoming narrower towards the posterior region of the oesophagus. The digestive tube is represented by the oesophagus, which is wider on the final end, the intestine, the rectum and anus. Posterior end had a rounded terminal protuberance or knob (Fig. 5A) as did the third stage larvae found in the egg. It was possible to determine the sex of third stage larvae according to criteria established by SPRENT²⁹.

The female larva has the genital rudiment bilobed (Fig. 6) while the male larva has a genital rudiment batonlike (Fig. 7).

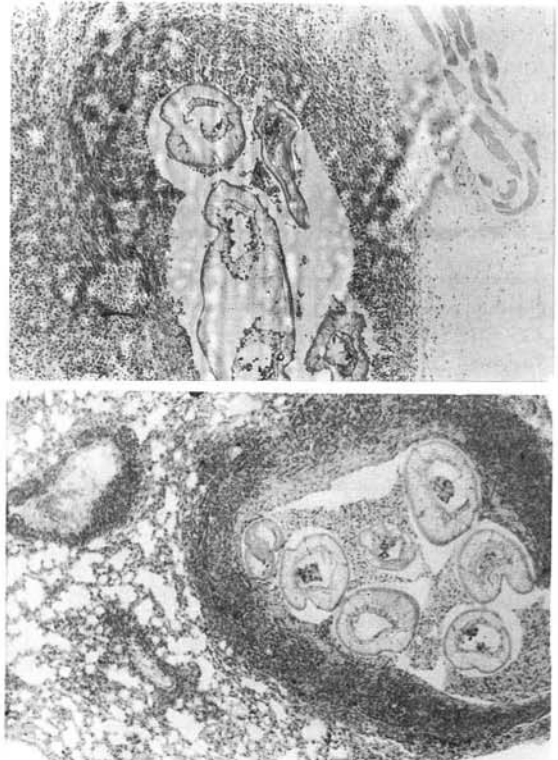


Fig. 2, 3 - Section of muscle (above) and lung (below) from mice infected with *L. minor* eggs, examined on day 90 P.I. showing larvae surrounded by a granulomatous reaction (x 40).

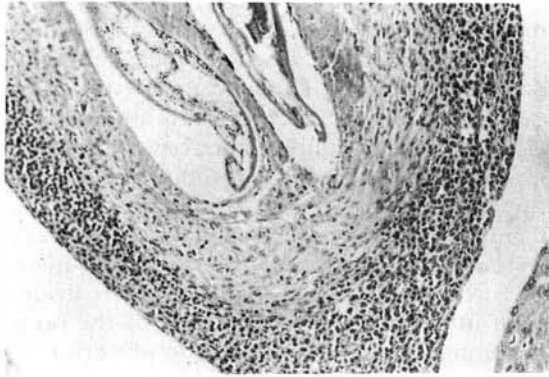


Fig. 4 - Granulomatous lesion in hepatic lobes of a mouse examined on day 90 P.I. Note the parasite in its center epithelioids cells, neutrophils and peripheral lymphoplasmocitary infiltrate (10 x 10).

In 13 (14%) out of 90 infected mice and examined on day 20 to 125 P.I., the parasite developed up to the mature stage inside big abscesses in different sites, such as: cervical, axillary, cephalic, thoracic and lombar regions or in the feet containing a single specimen in each abscess.

Third stage larvae, encysted in the skeletal musculature, were recovered from only one infected hamster and examined on day 325 P.I. (Table 1).

Parasite Development in the Definitive Host: Description of Fourth Stage Larvae.

Only a single third stage larva of *L. minor* was recovered from the lungs of one of the four cats infected orally with eggs and examined on day 41 P.I. However, in cats infected with mice carcasses, we noted third stage larvae hatch of the nodules in the stomach, migration to upper part of the digestive tracts developing to the mature stage on day 9 to 20 P.I., in the rhinoropharynx tissues: soft palate (uni and bilateral lesions), tonsil, pharynx, trachea; oesophagus; cervical lymphonodes; mastoid; middle ear; and nasal sinus. Third stage larvae were found in these animals 3 hr P.I. almost exclusively in the stomach - some in the oesophagus and oropharynx. After 6 hr P.I. there was predominance of third stage larvae in the rhinoropharynx and smaller number in the stomach. Fourth stage larvae were observed on day 2 to 8 P.I. and mature worms on day 9 to 20 P.I. Third and fourth molts can occur in any of the above mentioned sites but rarely in the stomach.

Fourth stage larvae are different from their previous stage by the clearness of the subventral and dorsal lips, each one with its respective papillae and separated from the rest

TABLE 1

Minimum, maximum, and average values (mm) of *L. minor* third stage larvae, recovered from mice, hamster, and cats infected for experiment at different intervals of time.

Quantitative	Mice			Hamster			Cats		
	96-330 days PI			325 days PI			3,6,12 h PI		
Measurable	N=22			N=9			N=67		
Elements	Vmin	\bar{X}	Vmax	Vmin	\bar{X}	Vmax	Vmin	\bar{X}	Vmax
Total length	6.12	8.93	10.89	7.12	8.80	10.43	4.75	9.88	13.36
Length of oesophagus	0.58	0.74	0.87	0.58	0.76	0.87	0.41	0.88	0.87
Diameter*	0.11	0.2	0.34	0.17	0.19	0.24	0.14	0.20	0.3
Nerve ring**	0.21	0.25	0.33	0.22	0.28	0.31	0.19	0.25	0.31
Excretory pore***	0.25	0.29	0.36	0.31	0.34	0.38	0.23	0.30	0.40
Genital primordium****	1.06	1.96	3.63	3.68	4.37	5.06	0.63	3.89	5.28
Distance from anus to end of tail	0.07	0.13	0.86	0.07	0.09	0.11	0.05	0.10	0.15

* Union: Oesophagus/intestine.

** Distance from nerve ring to anterior end.

*** Distance from excretive pore to anterior end.

**** Distance from genital primordium to posterior end.

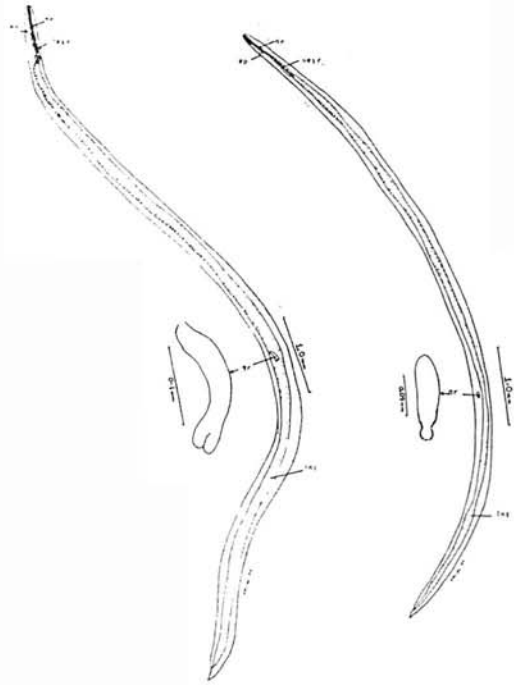
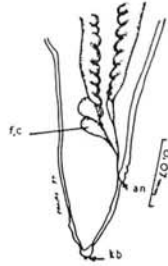
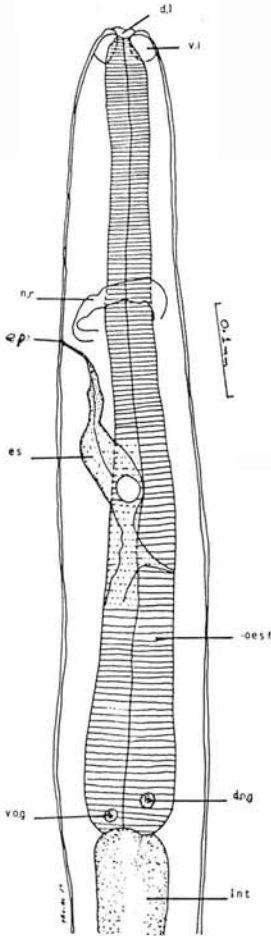


Fig. 6 - Third stage female larva recovered from cat 3 hr P.I. Note the shape of genital rudiment.
 Fig. 7 - Third stage male larva recovered from cat 6 hr P.I. Note the shape of genital rudiment.

Fig. 5 - Anterior end of third stage larva recovered from mouse on day 90 P.I.
 Fig. 5.A - Posterior end of same larva. Note terminal protuberance (kb).

of the body by the post-labial groove or furrow (Fig. 8); there is no knob in the posterior end. In the female larva, which can reach the length of 11,06mm (Table 2) the vulva is connected to the vagina and proceeds backwards continuing as the first uterine branches (Fig. 9). The male larva can reach the total length of about 10,47mm (Table 2) and the primordium of the spicules is clearly shown in the tail region (Fig. 10). The development of the testicular loops starts in the region corresponding roughly to one third of the body length (Fig. 11). Measurements made on mature parasites are shown in Table 3.

The experimental infection caused by *L. minor* in cats results in the development of tumorlike masses that change into structures resembling tunnels. Tumors in the rhino-oropharynx and in the cervical musculature can develop a fistula to the lumen of the digestive tract, respiratory branches or the cutaneous surface (Fig. 12). Eggs may be found in the lesion sites and in faeces when the abscesses have developed a fistula to the lumen of the digestive tract. In an animal infected with 40 nodules an abscess developed in cervical region and a fistula towards the cutaneous region draining purulent secretion. At necropsy on day 43 P.I. it was observed the occurrence of the self-infective cycle of *L. minor*: in addition to mature worms, there were eggs with 2, 4 and 8 blastomeres, eggs containing larvae and third stage larvae in the tissues of the neck and lungs.

The cat infected with skinned mice carcass containing 135 *L. minor* nodules died on day 6 P.I., showing signs of neurological impairment demonstrated by difficulty in locomotion and drooping the head to the left side. At necropsy third and fourth-stage larvae were found (mi-

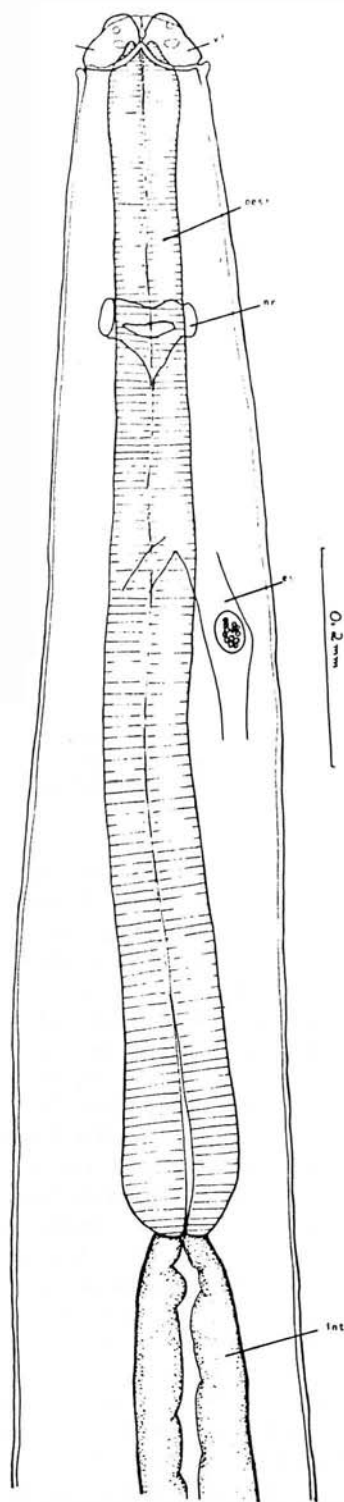


Fig. 8 - Anterior end of fourth stage larva recovered from cat on day 6 P.I.

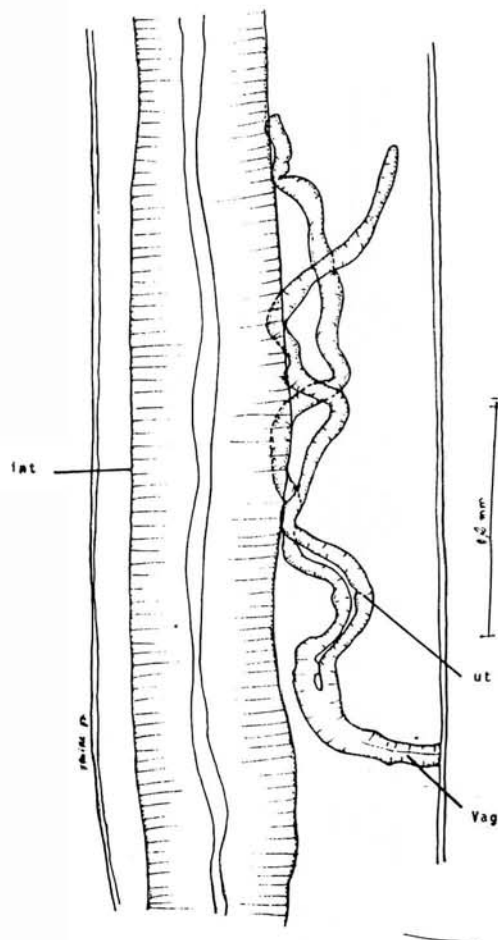


Fig. 9 - Genital development fourth stage female larva recovered from cat on day 4 P.I.

grating) in the brain and in the eye globe.

During necropsy of the only infected dog were found two nodules, one in the muscles of the cervical region making a tunnel towards the thoracic region and another in the palate. Both nodules were filled of mature worms immersed in a purulent secretion.

This way, the parasite cycle started being kept in laboratory by cultivating eggs in formaldehyde solution at 1%, infecting mice with infective eggs, and infecting cats, the definitive host, with encysted larvae in carcasses of infected mice.

DISCUSSION

In previous papers concerning experimental reproduction of the life cycle of *L.*

minor; LITTLE¹⁴ found some larvae in the mice inoculated. LEÃO et al¹² recovered only one worm in the cervical nodule of an infected monkey. BRUIJNING³ did not find any evidences of infection in the inoculated guinea pigs and cats.

It's likely that something related to the nature of the inoculum, such as non-infective eggs (BRUIJNING³ used one-week culture-eggs) or insufficient inoculum (small amounts of material) justify the negative or inconclusive results.

TABLE 2

Minimum, maximum, and average value (mm) of *L. minor* fourth stage larvae, recovered from *F. domestica* from the 2nd to the 8th day being infected for experiment.

Quantitative	Fourth Stage Larvae					
	Males			Females		
Variants & Identification by stage & sex	N = 66			N = 97		
Measurable	N = 66			N = 97		
Elements	Vmin	\bar{X}	Vmax	Vmin	\bar{X}	Vmax
Total Length	8.41	10.47	13.86	8.81	11.06	13.36
Oesophagus Length	0.63	0.87	1.12	0.23	0.88	1.25
Lip Length	0.02	0.036	0.05	0.02	0.035	0.05
Lip Width	0.02	0.04	0.06	0.01	0.039	0.06
Diameter*	0.15	0.24	0.30	0.19	0.26	0.31
Nerve Ring**	0.22	0.27	0.39	0.22	0.27	0.36
Excretory Pore***	0.24	0.33	0.46	0.27	0.33	0.42
Distance-Anus/Tail end	0.07	0.09	0.15	0.09	0.13	0.16

* Union: Oesophagus/intestine.

** Distance from nerve ring to anterior end.

*** Distance from excretory pore to anterior end.

TABLE 3

Minimum, maximum and average value (mm) of adult worms recovered from *F. domestica* infected for experiment.

Quantitative	Adult Worms					
	Males			Females		
Variants & Identification by Stage & Sex	N = 54			N = 60		
Measurable	N = 54			N = 60		
Elements	Vmin	\bar{X}	Vmax	Vmin	\bar{X}	Vmax
Total Length	11.22	14.44	18.48	10.56	15.25	20.95
Oesophagus length	0.91	1.25	1.68	0.91	1.31	1.87
Lip length	0.06	0.067	0.09	0.05	0.07	0.11
Lip width	0.05	0.069	0.09	0.04	0.07	0.10
Interlip	0.02	0.04	0.08	0.02	0.04	0.08
Diameter*	0.11	0.32	0.47	0.08	0.31	0.46
Nerve ring**	0.26	0.32	0.43	0.23	0.33	0.41
Excretory pore***	0.28	0.39	0.48	0.28	0.49	0.51
Distance-Anus/Tail end	0.08	0.11	0.19	0.12	0.16	0.28
Distance-Vulva to posterior end	-	-	-	4.95	7.20	10.89
Vagina length	-	-	-	0.16	0.94	3.31
Ejaculatory duct length	0.50	0.86	1.06	-	-	-
Spicules length	0.21	0.41	0.68	-	-	-

* Union: Oesophagus/intestine.

** Distance from nerve ring to anterior end.

*** Distance from excretory pore to anterior end.

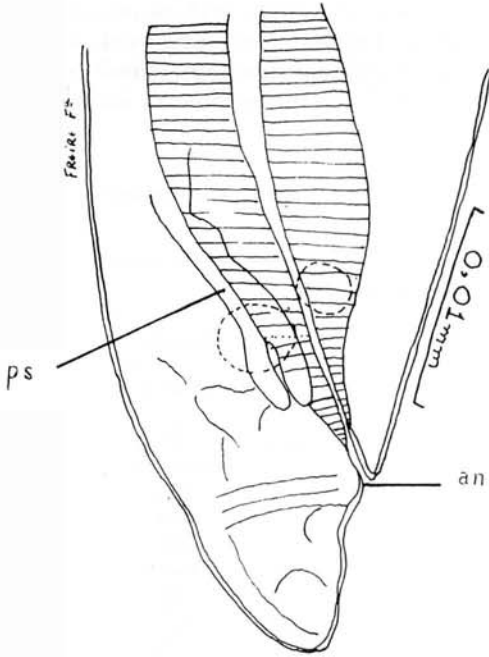


Fig. 10 - Posterior end of fourth stage male larva recovered from cat on day 6 P.I. Note the primordium of spicules (ps).

CAMPOS et al⁵ reported the occurrence of two cuticular molts in the *L. minor* eggs what suggested that third stage larvae would be the infective stage for this parasite as in other Ascarididea. Results from the present study confirm such observations and indicate that the life cycle of *L. minor* includes an obligatory intermediate host. In mice infected with eggs, third stage larvae hatch from the eggs, migrate, and become encysted and viable for approximately one year. In cats, definitive hosts, the parasite reaches the mature stage rapidly (on days 9 to 20 P.I.) if fed carcasses of infected mice. In cats inoculated with infective eggs sexual maturity of *L. minor* does not occur indicating the necessity of an intermediate host.

The ability of the *Lagochilascaris* to reach maturity in the intermediate host is pointed out. SMITH et al²⁸ reported the finding of mature worms in 16,4% of 55 mice infected orally with eggs of *L. sprenti*. We found mature worms in 14% of 90 mice infected orally with eggs of *L. minor*.

As for the hypothesis related to the transmissive mechanism in the lagochilascariasis,

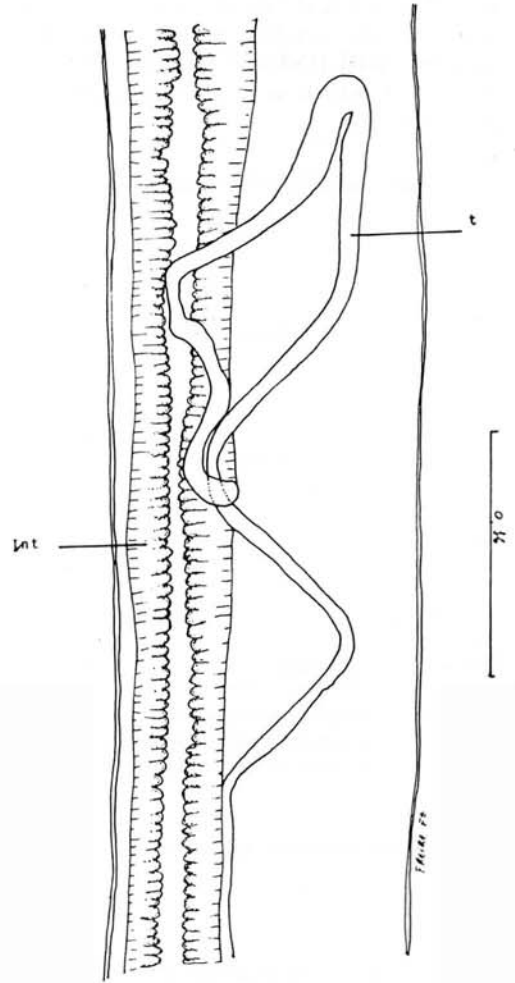


Fig. 11 - Development of testicular loops of fourth stage male larva recovered from cat on day 6 P.I.

SPRENT²⁹ suggested that the life cycle of *L. minor* was similar to the life cycle of *Ascaris lumbricoides*, from the time of ingestion of the eggs until the arrival of second stage larvae in the lungs, where the second molt would occur. From the lungs, third stage larvae would go to the trachea and instead of being swallowed as in the life cycle of *A. lumbricoides*, they would settle in the tonsils, nasal sinus, and related tissues.

According to FRAIHA et al¹⁰, human infection would result from ingestion of infective larvae in water contaminated with faeces of the natural host containing eggs of the parasite.

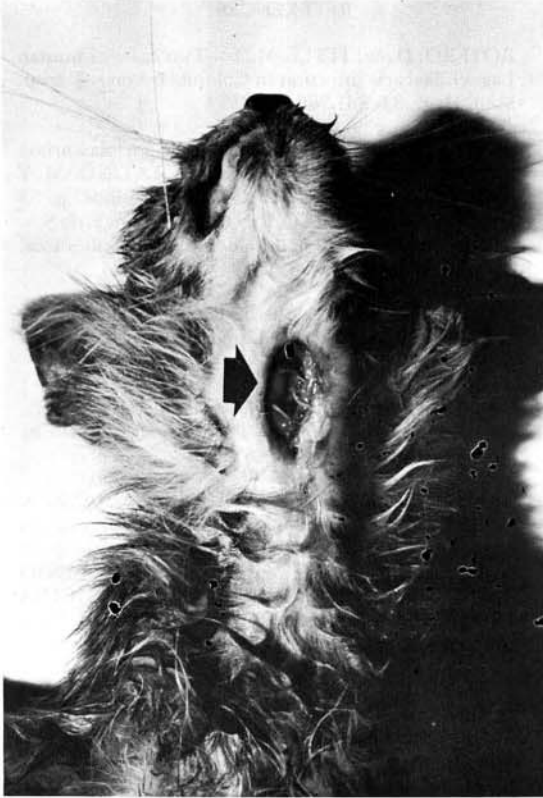

Fig. 12 -- Cervical abscess containing mature worms of *L. minor* in an infected cat and examined on day 16 P.I.

SMITH et al²⁸ reported the obligation of an intermediate host in the development of *L. sprenti*. Opossums, definitive hosts, do not become infected when fed embryonated eggs. The parasite only develops to the mature stage if opossums are fed skinned mice carcasses containing encysted larvae.

Based on his findings SMITH et al²⁸ suggested that human infections would result from ingestion of contaminated raw meat of a mammal; larvae in the meat could migrate from the stomach to the related tissues communicating with the pharynx where mature worms have been found in man: i.e., tonsils, nasal sinus, middle ear and the mastoid process.

Obviously, the pattern of infection by *L. minor* in animals used in this study follows the same pattern of infection by *L. sprenti* reported by SMITH et al²⁸.

How can we explain the necessity of an intermediate host in the life cycle of *L. minor*, and the occurrence of the self-infective mechanism noted in this experiment and in some

cases of human infection^{4,11,17}? We believe that there is a component in the carnivora's digestive tract that may preclude the development of larvae of *L. minor* eggs, and that the passage through the intermediate host's organism is relevant regarding to infectivity, resistance, and later development of larvae. Observations reinforcing this hypothesis relate to the steps of development in the life cycle of *A. lumbricoides*. This parasite does not need an intermediate host, however only larvae which have gone moulting to fourth stage in the lungs resist the action of the gastric juices of the vertebrate host²⁷.

Despite the possibility of occurrence of the self-infective mechanism in human and experimental lagochilascariasis, we believe that the ingestion of embryonated eggs (SPRENT'S hypothesis) and ingestion of larvae (FRAIHA'S hypothesis) are not means of human lagochilascariasis transmission.

The results from the present study confirm from the experimental point of view, the hypothesis formulated by SMITH et al²⁸. The human infection would result from eating raw or under-cooked-meat of wild rodents infected containing encysted larvae. These larvae would hatch from nodules in the stomach and would move upward to the digestive tract reaching the mature stage in the rhino-pharyngeal and neighboring tissues, as it was noted in the experimental infection. It's also accepted the existence of a natural life cycle involving wild rodents and carnivora in the transmission of this parasitosis.

RESUMO

Ciclo evolutivo experimental de *Lagochilascaris minor*, Leiper 1909.

A partir de material colhido de lesões humanas estudou-se o ciclo evolutivo de **Lagochilascaris minor** empregando-se o modelo experimental: roedores (camundongos, hamster) e carnívoros (gatos, cão).

Em camundongos inoculados com ovos infectantes, por via oral, observou-se eclosão de larvas de 3^o estágio na parede do intestino, migração das mesmas para o fígado, pulmão, musculatura esquelética e tecido subcutâneo tornando-se em seguida encistadas.

Em gatos alimentados com carcaças de camundongos infectados (60-235 dias de in-

fecção) observou-se: eclosão de larvas de 3º estágio do interior dos nódulos (cistos) no estômago, migração através do esôfago, faringe, traquéia, e tecidos vizinhos (rino-orofarínge), linfonodos cervicais alcançando a fase adulta, em qualquer uma destas localizações, 9-20 dias pós inoculação.

Não houve evolução do parasito até a fase adulta em gatos inoculados com ovos infectantes, por via oral, dado que reforça a necessidade do hospedeiro intermediário neste ciclo evolutivo.

Em um dos gatos (alimentados com carcaças de camundongos infectados) necropsiado 43 dias pós inoculação, observou-se a ocorrência do ciclo auto-infectante de *L. minor* o que foi caracterizado pelo encontro de ovos em várias fases de evolução, larvas de 3º estágio e vermes adultos em tecidos do pulmão e região cervical. Acredita-se que algum componente do trato digestivo de carnívoros possa inviabilizar larvas de 3º estágio do interior de ovos *L. minor*, justificando a interrupção do ciclo evolutivo quando tais animais são inoculados com ovos infectantes. Ressalta-se o papel do hospedeiro intermediário nas primeiras fases do ciclo evolutivo deste helminto.

ACKNOWLEDGEMENTS

The authors thank Professor Maurício Barcelos for his histopathological analysis of the material and also Mrs. Paulina L. Evangelista for her care and concern with animals raised in laboratory.

Key to lettering of figures

an.- anus
d.l.- dorsal lip
d.o.g.- nucleus of dorsal oesophageal gland
e.p.- excretory pore
e.s.- excretory system
f.c.- flat cells
g.r.- genital rudiment
int.- intestine
n.r.- nerve ring
oesf.- oesophagus
P.I.- Post inoculation
p.s.- primordia of spicules
t.- testes
k.b.- knob
ut.- uterine branch
vag.- vagina
v.o.g.- nucleus of subventral oesophageal gland
v.l.- subventral lips.

REFERENCES

1. BOTERO, D. & LITTLE, M.D. - Two cases of human *Lagochilascaris* infection in Colombia. *Amer. J. trop. Med. Hyg.*, 33: 381-386, 1984.
2. BRENES, M.R.R. & BRENES, A.F. - *Lagochilascariase* humana en Costa Rica. In: CONGR. LATINOAM. Y NAC. MICROB., Costa Rica, 1961. *Resumos*. p. 35 apud FRAIHA, H.; LEÃO, R.N.Q. & COSTA, F. do S.A. - *Lagochilascariase* humana e dos animais domésticos. *Zoon. Rev. Int.*, 1: 25-33, 1989.
3. BRUIJNING, C.F.A. - Notes on *Lagochilascaris minor* Leiper, 1909. *Docum. Med. geogr. trop.*, (Amst.), 9: 173-175, 1957.
4. CAMPOS, D.M.B. - *Lagochilascaris*. In: NEVES, D.P., ed. *Parasitologia Humana*. 8ª ed. São Paulo, Rio de Janeiro, Atheneu, 1991. p. 482-486.
5. CAMPOS, D.M.B.; VIEIRA BRESSAN, M.C.R. & ROSA, S.Z. - Considerações sobre evolução do *Lagochilascaris minor* Leiper, 1909. I - Número de mudas de larvas no interior do ovo. In: CONGRESSO DA SOCIEDADE BRASILEIRA DE MEDICINA TROPICAL, 25., Florianópolis, 1989. *Resumos*. Florianópolis, 1989. p. 198.
6. CHIEFFI, P.P.; FRUCCHI, H.; PROENÇA, N.G.; PEREIRA, W.A. & PASCHOALOTTI, M.A. - Infecção cutânea por *Lagochilascaris minor* - tratamento e cura rápida pelo Levamisol. *An. bras. Derm.*, 56: 141-144, 1981.
7. CORRÊA, M.O.A.; HYAKUTAKE, S.; BRANDI, A.J. & MONTEIRO, C.G. - Novo caso de parasitismo humano por *Lagochilascaris minor* Leiper, 1909. *Rev. Inst. Adolfo Lutz*, 38: 59-65, 1978.
8. COSTA, H.M.A.; SILVA, A.V.M.; COSTA, P.R. & ASSIS, S.B. - *Lagochilascaris minor* Leiper, 1909 (Nematoda - Ascaridae) de origem humana. *Rev. Inst. Med. trop. S. Paulo*, 28: 126-130, 1986.
9. DRAPER, J.W. - Infection with *Lagochilascaris minor*. *Brit. med. J.*, 1: 931-932, 1963.
10. FRAIHA, H.; ROCHA, M.P.C.; ARAÚJO, O.J.; BARROS, V.L.R.S.; PRIMO, A.; MORAES, M.A.P.; CONCEIÇÃO, J.R. & OLIVEIRA, J.E.G. - Patologia amazônica exótica. II: Infecção humana por *Lagochilascaris minor* Leiper, 1909 (Nematoda, Ascarididae). Registro de três novos casos e formulação de nova hipótese para o mecanismo de infecção. In: CONGRESSO DA SOCIEDADE BRASILEIRA DE PARASITOLOGIA, 8; CONGRESSO DA FEDERACIÓN LATINOAMERICANA DE PARASITÓLOGOS, 6. & JORNADA PAULISTA DE PARASITOLOGIA, 5. São Paulo, 1983. *Resumos*. São Paulo, 1983. p.146.
11. FRAIHA, H.; LEÃO, R.N.Q. & COSTA, F. do S.A. - *Lagochilascariase* humana e dos animais domésticos. *Zoon. Rev. Int.*, 1: 25-33, 1989.
12. LEÃO, R.N.Q.; LEÃO-FILHO, J.; BRAGA-DIAS, L. & CALHEIROS, L.B. - Infecção humana pelo *Lagochi-*

- lascaris minor Leiper, 1909. Registro de um caso observado no Estado do Pará (Brasil). *Rev. Inst. Med. trop. S. Paulo*, 20: 300-306, 1978.
13. LEIPER, R.T. - A new nematode worm from Trinidad. *Proc. Zool. Soc. London*, 4: 742-743, 1909.
14. LITTLE, M.D. - Life cycle of *Lagochilascaris minor*. *J. Parasit.*, 50: 34, 1964.
15. MARTINEZ, M.R. - Parásitos animales de la región buconasofaríngea. *Rev. Assoc. Dental Mexicana*, 37: 340-369, 1980 apud FRAIHA, H.; LEÃO, R.N.Q. & COSTA, F. do S.A. - *Lagochilascariase* humana e dos animais domésticos. *Zoon. Rev. Int.*, 1: 25-33, 1989.
16. MONTEIRO, M.R.; ALBUQUERQUE, H.P.C.; SOUZA, J.M.; ABDON, N.P.; FRAIHA NETO, H.; SOUZA, J.R. & ALMEIDA, A.J.L. - Comprometimento do sacro na lagoquilascariase. In: CONGRESSO DA SOCIEDADE BRASILEIRA DE MEDICINA TROPICAL, 24., Manaus, 1988. Programa e resumos. Manaus, 1988. p.98.
17. MORAES, M.A.P.; ARNAUD, M.V.C. & LIMA, P.E. - Novos casos de infecção humana por *Lagochilascaris minor* Leiper, 1909, encontrados no Estado do Pará, Brasil. *Rev. Inst. Med. trop. S. Paulo*, 25: 139-146, 1983.
18. MORAES, M.A.P.; ARNAUD, M.V.C.; MACEDO, R.C. & ANGLADA, A.E. - Infecção pulmonar fatal por *Lagochilascaris* sp, provavelmente *Lagochilascaris minor* Leiper, 1909. *Rev. Inst. Med. trop. S. Paulo*, 27: 46-52, 1985.
19. OBEID, J.N.; FRAIHA NETO, H.; VIEIRA, F.P. & ABREU, E.P. - *Lagochilascariase* com envolvimento cerebelar. In: CONGRESSO DA SOCIEDADE BRASILEIRA DE MEDICINA TROPICAL, 21. São Paulo, 1985. Programa e resumos. São Paulo, 1985. p.80.
20. OOSTBURG, B.F.J. & VARMA, A.A.O. - *Lagochilascaris minor* infection in Surinam. *Amer. J. trop. Med. Hyg.*, 17: 548-550, 1968.
21. OOSTBURG, B.F.J. - Thiabendazole therapy of *Lagochilascaris minor* infection in Surinam. *Amer. J. trop. Med. Hyg.*, 20: 580-583, 1971.
22. ORIHUELA, R.; BOTTO, C.; DELGADO, O; ORTIZ, A.; SUAREZ, J.A. & ARGUELLO, C. - Relatos de casos *Lagochilascariasis* humana en Venezuela: Descripción de un caso fatal. *Rev. Soc. bras. Med. trop.*, 20: 217-221, 1987.
23. PAWAN, J.L. - Another case of infection with *Lagochilascaris minor* Leiper, 1909. *Ann. trop. Med. Parasit.*, 21: 45-47, 1927.
24. ROCHA, M.P.C.; FRAIHA NETO, H. & BARRETO NETTO, A.C.P. - Infecção de ouvido médio e mastóide por *Lagochilascaris minor* Leiper, 1909 (Nematoda, Ascarididae). Relato de um caso do sul do Estado do Pará, Amazônia, Brasil. *Hiléia méd.* (Belém), 6: 3-14, 1984.
25. ROSEMBERG, S.; LOPES, M.B.S.; MASUDA, Z.; CAMPOS, R. & VIEIRA BRESSAN, M.C.R. - Fatal encephalopathy due to *Lagochilascaris minor* infection. *Amer. J. trop. Med. Hyg.*, 35: 575-578, 1986.
26. SANTOS, M.A.Q.; CAMPOS, D.M.B.; KOMMA, M.D. & BARNABÉ, W. - *Lagochilascaris minor* Leiper, 1909 em abscesso dentário, em Goiânia. *Rev. Pat. trop.*, 16: 1-6, 1987.
27. SCHMIDT, G.D. & ROBERTS, L.S. - *Foundations Parasitology*. 2. ed. London, C.V. Mosley Company, 1981. cap. 27, p. 483-493.
28. SMITH, J.L.; BOWMAN, D.D. & LITTLE, M.D. - Life cycle and development of *Lagochilascaris sprenti* (Nematoda: Ascarididae) from opossums (Marsupialia: Didelphidae) in Louisiana. *J. Parasit.* 69: 736-745, 1983.
29. SPRENT, J.F.A. - Speciation and development in the genus *Lagochilascaris*. *Parasitology*, 62: 71-112, 1971.
30. VOLCAN, G.S.; OCHOA, F.R.; MEDRANO, C.E. & VALERA, Y. de. - *Lagochilascaris minor* infection in Venezuela: report of a case. *Amer. J. trop. Med. Hyg.*, 31: 1111-1113, 1982.

Recebido para publicação em 24/10/1991
Aceito para publicação em 01/07/1992