

CUTANEOUS *NOCARDIA ASTEROIDES* INFECTION OF NONTRAUMATIC ORIGIN

Jorge O. LOPES (1), Maria C. BASSANESI (2), Sydney H. ALVES (1), Adenilde SALLA (1), Jeni P. BENEVENGA (1)
& Milton S. CASTRO (1)

SUMMARY

This paper reports a case of cutaneous infection of nontraumatic origin caused by *Nocardia asteroides* in a hospitalized patient with chronic obstructive pulmonary disease. Diagnosis was established by direct and histological examination, cultures from exudate and biopsy specimen. We discuss the classification of clinical forms of *Nocardia* infections affecting the skin.

KEYWORDS: Cutaneous infection; Chronic obstructive pulmonary disease; *Nocardia asteroides*; Nontraumatic origin.

INTRODUCTION

The concept of nocardiosis as an exotic disease that only affects immunologically incompetent patients by advance malignancy, is a mistake⁸, since the soil-inhabitants aerobic actinomycetes of the *Nocardia* genus are increasingly recognized agents of infection in normal and compromised hosts⁴. The term, compromised host, is usually applied to an individual with impairment of immunological function, but it should be applied to a patient in whom non-immunological mechanisms of defense are impaired, such as, the mechanical clearance of the lung in chronic obstructive pulmonary disease (COPD)²⁸. The lung in the patient with COPD is a common site of infection resulting from inhalation of spores, and the frequent coexistence of nocardiosis with other lung chronic diseases, has contributed to the erroneous concept that nocardiae are frequently saprophytes of the human respiratory tract²⁰. Primary pulmonary nocardiosis is usually an acute or subacute

disease, but the symptoms may be of a minor, transient, benign or chronic nature, without clinical evidence of disease. However, dissemination from a pulmonary focus may occur, even in the absence of overt lung symptomatology, causing metastatic lesions anywhere in the body, including the skin²². *Nocardia* infections affecting the skin have usually been considered under the clinical form known as nocardial mycetoma, but as a result of the improvement of diagnostic methods, the number of other clinical forms has increased⁴. We report a case of cutaneous infection of nontraumatic origin caused by *N. asteroides* in a hospitalized patient with COPD, and we discuss the classification of the clinical forms of *Nocardia* infections affecting the skin.

CASE REPORT

A 74-year-old white man, born and living in the rural area of Santa Maria, RS, Brazil, was hospitalized at the Santa Maria University Hospital on May 5, 1992.

(1) Serviço de Micologia, Hospital Universitário, Universidade Federal de Santa Maria, RS, Brasil.

(2) Serviço de Micologia, Instituto de Pesquisas Biológicas, Secretaria da Saúde e Meio Ambiente, Porto Alegre, RS, Brasil.

Correspondence to: Jorge O. Lopes, Departamento de Microbiologia e Parasitologia, Universidade Federal de Santa Maria, 97119-970 Santa Maria, RS, Brasil.

The patient with COPD presented in a poor condition, with intense dyspnea, fever, nausea, vomit, abdominal pain and urinary retention. On the 6th day of hospitalization, pustulous lesions on an erythematous base appeared on the right elbow, with edema extended up to the hand (Fig. 1). No lymphadenopathy was detected. The exudate collected from vesicles revealed gram positive, no acid-fast, slender ramified fragmented filaments consistent with an actinomycete (Fig. 2). A biopsy performed on May 21, revealed leucocytoclastic vasculitis, but with the modified Gram's stain (Brown & Brenn), delicate branched filaments and chains of bacillary bodies were seen. Exudate and a fragment of biopsy specimen were cultivated on Sabouraud's dextrose agar incubated at 25 and 37°C aerobically. Colonies appeared on the 5th day and were glabrous, folded, granular and orange in color, covered later by an overgrowth of short white aerial mycelium. The identification of the actinomycete as *N. asteroides* was confirmed by the National Laboratory for Bacteriology, Canada. Despite the diagnosis of nocardiosis, the cutaneous lesion was treated with potassium permanganate solution and a topical cream containing antibiotic, showing slow improvement. Unfortunately no further diagnostic procedures were performed to confirm the endogenous origin of the lesions. The patient was discharged from the hospital without a specific therapy for nocardiosis.

DISCUSSION

Cutaneous manifestation of nocardiosis may be the result of primary inoculation or of the seeding of the skin from a systemic infection. *Nocardia* infections affecting the skin are becoming more common as a result of the improvement of diagnostic methods, but attempts to classify the clinical forms reveals differences among authors¹³. We think that these infections may be considered under three distinct clinical forms: (1) acute primary cutaneous infection, (2) chronic primary cutaneous infection or nocardial mycetoma and (3) disseminated infection with skin involvement. In the acute primary cutaneous infection, the lesion follows inoculation and the agent grows in tissue usually as slender branching filaments. These cases appeared early as pyoderma, cellulitis, pustules or localized abscesses^{10, 12, 13, 18, 26, 27}, similar in appearance to diseases caused by common pyogenic organisms. The histologic pattern is a mixed pyogenic and granulomatous reaction. Later it may develop the chancriform and lymphocutaneous syndrome^{11, 15, 17, 21, 30}, mimicking sporotrichosis, that is usually caused by *N. brasiliensis*^{15, 17, 18, 21, 22, 30}, but may also be caused by *N. asteroides*¹¹ and *N. otitidisca-viarum*¹⁰. The chancriform syndrome as described by WILSON²⁹, is the clinical picture to be expected if a fungus, capable of causing deep mycoses, is acquired by direct cutaneous inoculation. This syndrome is cha-

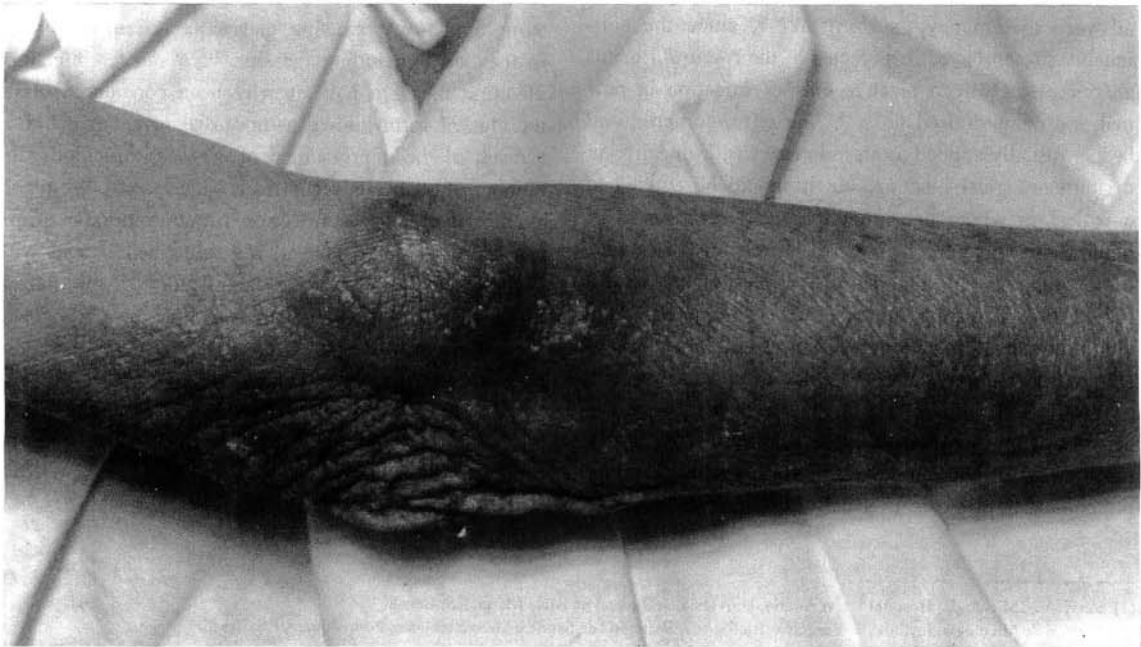

Fig. 1 - Cutaneous *N. asteroides* infection of nontraumatic origin: pustulous lesion on an erythematous base.

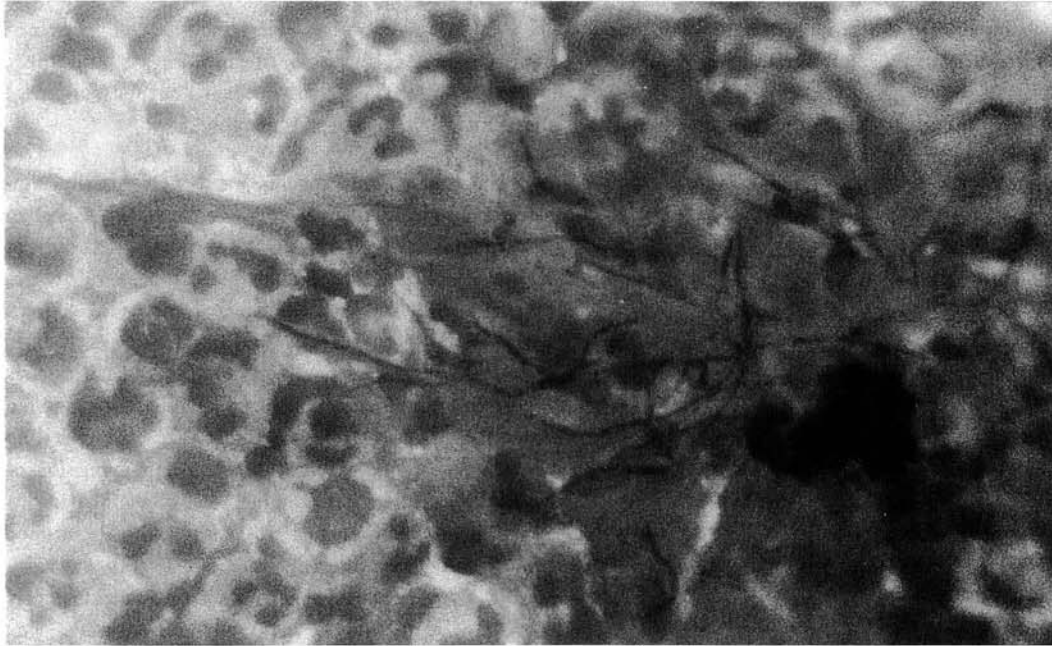


Fig. 2 - Cutaneous *N. asteroides* infection: gram positive, no acid-fast, slender ramified fragmented filaments. Gram, x 630.

racterized by initial multiplication of the agent at the site of inoculation for only a few days. Then, a specific resistance of the host causes an intense infiltration of leukocytes, induration and inflammation, with involvement of regional lymphatics. At this time, the concentration of microorganisms in the lesion decreases and the diagnosis by direct examination becomes difficult. In addition, the discard of routine cultures after 48 to 72 hours makes the observation of many slowgrowing isolates of *Nocardia* impossible²⁶. According to SATTERWHITE & WALLACE²⁶, the absence of grains in this clinical form of nocardiosis may reflect only a shorter duration of illness and less extensive disease, rather than a distinct clinical and histopathologic condition. These authors described a case of acute primary cutaneous nocardiosis of three weeks duration caused by *N. brasiliensis* presented as pyoderma with lymphocutaneous involvement and grains disclosed in a biopsy specimen. RIPPON²², described a case of primary cutaneous infection by *N. brasiliensis* in which the serpiginous lesion developed after trauma, resulted in sinus tract and grains as in mycetoma. LONDERO et al.¹⁴, reported a case of two months duration resulting in subcutaneous nodule with sinus tract and grains caused by *N. brasiliensis*. Although correctly diagnosed, an incorrect treatment made this acute primary cutaneous infection to evolve to

a mycetoma, with swelling and bone involvement of the foot. VASARINSH²⁷, reported a case of primary cutaneous nocardiosis recurrent after surgical excision, without swelling and sinus tract, where *N. asteroides* appeared as grains. CONTI-DIAZ⁷, named premycetomatous lesions, three cases of lymphangitic nocardiosis of the arms and one abscess of the shoulder caused by *N. brasiliensis* and suggested that the absence of grains in these lesions justified the term premycetomatous. However, in cases of SATTERWHITE & WALLACE²⁶, RIPPON²² and VASARINSH²⁷, the clinical form was classified as primary cutaneous infection, even in the presence of grains in the lesions. We think that the host/parasite relationship may play an important role in the establishment of the clinical form, specially involving the cell-mediated immunity and the pathogenic power of different strains^{4, 8}.

The chronic primary cutaneous nocardiosis or nocardial mycetoma also follows inoculation of the actinomycete in the skin or subcutaneous tissue, and may represent the end-stage of the acute primary cutaneous infection²², or premycetomatous form⁷, misdiagnosed and incorrectly treated. The initial lesion noticed by the patient is often a small painless subcutaneous nodule of traumatic origin. The lesion spreads into deeper adjacent or lymphocutaneous tissues,

enlarges and ruptures to the surface forming sinus tracts and causing disfiguring swelling, that may involve lymphatics and bones. The histologic pattern is a suppurative chronic reaction with grains formation. CONTI-DIAZ ⁷ suggests that the early diagnosis of mycetomas and related diseases is the result of a prompt medical consultation. Unfortunately, the great incidence of mycetoma in tropical and subtropical regions may be due to long duration of the illness, because in these countries, mycetoma rarely appears for medical advice in the early acute primary form and when it occurs, the diagnosis is rarely performed. Nocardial mycetoma is usually caused by *N. brasiliensis* ²², but may also be caused by *N. asteroides* ²⁴, *N. otitidiscaviarum* ¹ and *N. transvalensis* ⁹.

In disseminated nocardiosis nearly 9 to 33% of the patients may present single or multiple lesions of the skin or subcutaneous tissue ^{8, 11, 23}. In early stages, these cases appear as pustules ^{2, 5, 6, 25}, cellulitis ¹², abscesses ^{6, 23} and subcutaneous nodules ¹⁶, or may evolve to sinus tracts formation ^{8, 22}. The actinomycete grows in tissue as slender branching filaments, and the histologic pattern is a mixed pyogenic and granulomatous reaction. This clinical form may be caused by *N. asteroides* ^{5, 22, 25}, *N. brasiliensis* ¹⁶ and *N. otitidiscaviarum* ^{2, 6}. Usually,

there is evidence of an underlying visceral focus and absence of local trauma of the skin ²³, and these conditions may suggest us the hematogenous origin of the skin lesion in the present report.

Nocardiae infections in Brazil were usually considered as nocardial mycetoma. The first two Brazilian cases of pulmonary nocardiosis were diagnosed only in 1978 ¹⁹, while in the United States, probably between 500 and 1000 cases are recognized each year ³, from which 85% are serious pulmonary or systemic infections. In a recent report of nine cases of nocardiosis occurred among renal transplant recipients in Ribeirão Preto, SP, SANTAMARIA SABER et al. ²³, founded all patients with pulmonary involvement. Dissemination of *Nocardia* infection was common, with central nervous system involvement in four patients (44%); skin in three (33%), and pericardium in one. The overall mortality rate was 77%, and in five patients who died the diagnosis was late, and for the others the diagnosis was accomplished at necropsy.

Coexistence of systemic nocardiosis with diseases that are more easily diagnosed result in further diagnostic procedures that are not performed ⁸. However, it is very important to recognize that skin lesions of

TABLE I
Nocardia infections affecting the skin: distinguishing features of the clinical forms (Adapted from HAY ¹²).

Clinical features	Acute primary cutaneous	Chronic primary cutaneous	Disseminated infection
History of trauma	common	common	rare
Site involved	exposed areas	exposed areas	anywhere
Number of lesions	usually single	usually single	single or multiple
Draining sinuses	usually absent	present	usually absent
Swelling	absent	present	absent
Parasitic pattern	usually filamentous rarely grains	grains	filamentous
Histologic pattern	mixed pyogenic and granulomatous reaction	suppurative chronic reaction	mixed pyogenic and granulomatous reaction
Other site involved	lymphatics, subcutaneous tissue	lymphatics, subcutaneous tissue, bone	lung, brain, kidney, pleura, chest wall, others
Predisposing factors	rare	rare	common
Distribution	worldwide	tropical and subtropical regions	worldwide
Species involved	<i>N. brasiliensis</i> <i>N. asteroides</i> <i>N. otitidiscaviarum</i>	<i>N. brasiliensis</i> <i>N. asteroides</i> <i>N. otitidiscaviarum</i> <i>N. transvalensis</i>	<i>N. asteroides</i> <i>N. brasiliensis</i> <i>N. otitidiscaviarum</i>

nontraumatic origin caused by nocardiae, may be the result of the dissemination from the lung or other deep focus, and this point should be emphasized when considering investigation and management of patients with lung diseases. The distinction between the clinical forms of *Nocardia* infections affecting the skin is possible to be made with considerable degree of accuracy (Table 1). Unfortunately, this distinction is usually disregarded until the worsening of the symptoms confirms the diagnosis, since interpretation of the isolation of a microorganism from clinical material, depends on a careful integration of clinical and laboratory parameters.

RESUMO

Infecção cutânea de origem não traumática por *Nocardia asteroides*

É relatado um caso de infecção cutânea de origem não traumática por *Nocardia asteroides* em paciente hospitalizado com doença broncopulmonar obstrutiva crônica. O diagnóstico foi feito pelo exame direto e histológico e culturas do exsudato e fragmento de biópsia. É discutida a classificação das formas clínicas das infecções por *Nocardia* que afetam a pele.

ACKNOWLEDGEMENTS

The authors are indebted to Dr. Kathryn Bernard, National Laboratory for Bacteriology, Health and Welfare, Canada, for *N. asteroides* confirmatory identification.

REFERENCES

- ALTERAS, I. & FEURMAN, E.J. - The second case of mycetoma due to *Nocardia caviae* in Israel. *Mycopathologia* (Den Haag), 93: 185-187, 1986.
- ARROYO, J.C.; NICHOLS, S. & CARROLL, G.F. - Disseminated *Nocardia caviae* infection. *Amer. J. Med.*, 62: 409-412, 1977.
- BEAMAN, B.L.; BURNSIDE, J.; EDWARDS, B. & CAUSEY, W. - Nocardial infections in the United States, 1972-1974. *J. infect. Dis.*, 134: 286-289, 1976.
- BEAMAN, B.L.; BOIRON, P.; BEAMAN, L. et al. - *Nocardia* and nocardiosis. *J. med. vet. Mycol.*, 30 (suppl. 1): 317-331, 1992.
- BOIRON, P.; LAFAURIE, C.; RABBACHE, A. et al. - Urease-negative *Nocardia asteroides* causing cutaneous nocardiosis. *J. clin. Microbiol.*, 28: 801-802, 1990.
- CAUSEY, W.A.; ARNELL, P. & BRINKER, J. - Systemic *Nocardia caviae* infection. *Chest*, 65: 360-362, 1974.
- CONTI-DIAZ, I.A. - Micetomas y procesos premicetomatosos en el Uruguay. *Mycopathologia* (Den Haag), 72: 59-64, 1980.
- CURRY, W.A. - Human nocardiosis. A clinical review with selected case reports. *Arch. Intern. Med.*, 140: 818-826, 1980.
- GUGNANI, H.C.; OJNKWU, J.O. & SUSEELAN, A.V. - Mycetoma of the thumb caused by *Nocardia transvalensis*. *Mycopathologia* (Den Haag), 80: 55-60, 1982.
- HACHISUKA, H.; ICHIKI, M.; YOSHIDA, N.; NAKANO, S. & SASAI, Y. - Primary subcutaneous abscess caused by *Nocardia otitidiscaviarum*. *J. Amer. Acad. Derm.*, 21: 137-139, 1989.
- HAIM, S. & MERZBACH, D. - Primary chancriform syndrome caused by *Nocardia asteroides*. *Mykosen*, 22: 360-363, 1979.
- HAY, R.J. - Nocardial infection of the skin. *J. Hyg. (Lond.)*, 91: 385-391, 1983.
- HIRUMA, N.; KAWADA, A.; ISHIBASHI, A. & MIKAMI, Y. - Localized cutaneous nocardiosis in Japan. *Mycopathologia* (Den Haag), 117: 133-138, 1992.
- LONDERO, A.T.; RAMOS, C.D. & MATTE, S.W. - Micetomas actinomicóticos no Rio Grande do Sul - relato de quatro casos. *Mem. Inst. Oswaldo Cruz*, 81: 73-77, 1986.
- MACKINNON, J.E.; CONTI-DIAZ, I.A.; GEZUELE, E. & GIORDANO, M.H. - Nocardiosis linfangítica. *Torax*, 17: 84-86, 1968.
- MAHVI, T. - Disseminated nocardiosis caused by *Nocardia brasiliensis*. First case report in the United States. *Arch. Derm.*, 84: 426-431, 1964.
- MOORE, M. & CONRAD, A.H. - Sporotrichoid nocardiosis caused by *Nocardia brasiliensis*. *Arch. Derm.*, 95: 390-393, 1967.
- MOORE, M.; LANE, C.W. & GAUL, L.E. - Nocardiosis of the knee by *Nocardia brasiliensis*. *Arch. Derm.*, 70: 302-310, 1954.
- PETRILLO, V.F.; SEVERO, L.C.; LONDERO, A.T. & PORTO, N.S. - Pulmonary nocardiosis. Report of the first two Brazilian cases. *Mycopathologia* (Den Haag), 66: 17-20, 1978.
- RAICH, R.A.; CASEY, F. & HALL, W.H. - Pulmonary and cutaneous nocardiosis. *Amer. Rev. resp. Dis.*, 83: 505-508, 1960.
- RAPAPORT, J. - Primary chancriform syndrome caused by *Nocardia brasiliensis*. *Arch. Derm.*, 93: 62-64, 1966.
- RIPPON, J.W. - Nocardiosis. In: RIPPON, J.W. *Medical Mycology. The pathogenic fungi and the pathogenic actinomycetes*. 3. ed. Philadelphia, W.B. Saunders, 1988. p 53-68.
- SANTAMARIA SABER, L.T.; FIGUEIREDO, J.F.C.; SANTOS, S.B. et al. - *Nocardia* infection in renal transplant recipient: diagnostic and therapeutic considerations. *Rev. Inst. Med. trop. S. Paulo*, 35: 417-421, 1993.
- SANYAL, M.; THAMMAYYA, A. & BASU, N. - Actinomycetoma caused by organisms of the *Nocardia asteroides* complex and closely related strains. *Mykosen*, 21: 109-121, 1978.
- SHAPIRO, P.E. & GROSMAN, M.E. - Disseminated *Nocardia*

- asteroides* with pustules. *J. Amer. Acad. Derm.*, 20: 889-892, 1989.
26. SATTERWHITE, T.K. & WALLACE, R.J. - Primary cutaneous nocardiosis. *J. Amer. med. Ass.*, 242: 333-336, 1979.
27. VASARINSH, P. - Primary cutaneous nocardiosis. *Arch. Derm.*, 98: 489-493, 1968.
28. WARNOCK, D.W. - Introduction to the management of fungal infection in the compromised patient. In: WARNOCK, D.W. & RICHARDSON, M.D. *Fungal infection in the compromised patient*. 2. ed. West Sussex, John Wiley & Sons, 1991. p. 23-53.
29. WILSON, J.W. - Cutaneous (chancriform) syndrome in deep mycoses. *Arch. Derm.*, 87: 121-125, 1963.
30. ZECLER, E.; GILBOA, Y.; ELKINA, L.; ATLAN, G. & SOMPOLINSKY, D. - Lymphocutaneous nocardiosis due to *Nocardia brasiliensis*. *Arch. Derm.*, 113: 642-643, 1977.
- Recebido para publicação em 20/12/1993.
Aceito para publicação em 29/03/1994.