

BRIEF REPORT

MAMMOMANOGAMUS (SYNGAMUS) LARYNGEUS INFECTION: A NEW BRAZILIAN HUMAN CASE

Ana Lúcia FREITAS, Geraldo DE CARLI & Maria Helena BLANKENHEIN

The nematode *Mammomanogamus (Syngamus) laryngeus* is commonly found in the upper respiratory tract of ruminants including domestic cattle, water buffalo, and goats. Humans can be accidentally infected with this parasite. The worms live attached in the mucosa of laryngotracheal region, and usually the symptoms express tracheolaryngeal irritation, with stubborn cough without fever. In some patients there is hemoptysis. These worms remain in permanent copula so that the pair appears as a "Y". The life cycle of *M. (S.) laryngeus* has not been elucidated.

These parasites were discovered by KING in January, 1913 (LEIPER, 1913) ⁸ in the sputum of an Irish woman in Santa Lucia, Antilles. Infection of man by this nematode is rare, but the worms have been described in Australia, Brazil, British Guiana, Canada, Martinique, Philippines, Puerto Rico, St. Lucia (West Indies) and Trinidad, and the United States of America. Up to the present, 86 cases of human infection with *M. (S.) laryngeus* have been reported (St. JOHN et al. ²¹; JUNG et al. ⁶; DUFAT et al. ⁴; WEINSTEIN & MOLAVI ²⁴; BIRREL et al. ²; MORNEX et al. ¹⁷; TIMMONS et al. ²²; GARDINER & SCHANTZ ⁵; LEERS et al. ⁷; SANTOS et al. ¹⁹ and SEVERO et al. ²⁰).

In the Brazilian reports there are 21 cases of human parasitism by *M. (S.) laryngeus*. All of these are, apparently, accidental infections with the bovine species.

These worms were first described from Brazilian patients in the early 1920s by TRAVASSOS (1921) ²³ in Salvador, Bahia. Other cases have been reported by MACHADO (1938) ¹³; MELLO & MELLO (1938) ¹⁴; LENT & PENNA (1939) ¹⁰; MORAES (1947) ¹⁶;

PASSOS & BARBOSA (1948) ¹⁸; LIMA & BARBOSA (1951) ⁹; AMARAL, et al. (1954) ¹; MACHADO et al. (1962) ¹²; LONDERO & LAUDA, 1967 ¹¹; Busetti et al. (1983) ³; MELO et al. (1984) ¹⁵; SANTOS et al. (1986) ¹⁹; SEVERO et al. (1988) ²⁰, and finally ZUNINO et al. (1989) ²⁵ described six additional cases.

The aim of this communication is to describe a new Brazilian case of syngamosis in a human being. The patient, a 33-year-old white man, veterinarian, from Santa Maria, RS, Brazil, eliminated the worms in July 1992 by spontaneous expectoration after violent attacks of coughing.

The specimens received for morphologic diagnostic reached our laboratory poorly preserved and damaged. To secure a proper preparation, the mucus and adherent debris were carefully removed from the worms by gently shaking in physiological saline. The parasites were fixed in alcohol-formalin-acetic acid (AFA) for 24 h and were stored in alcohol-glycerin.

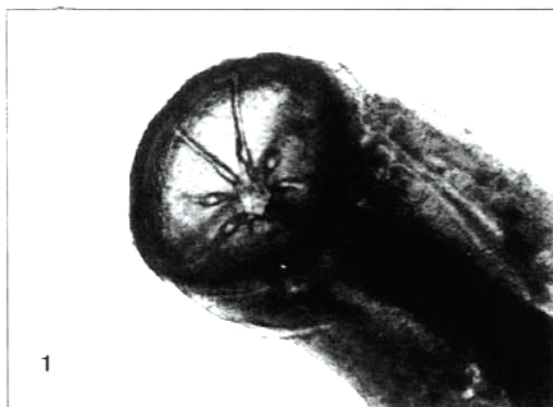

Fig. 1 - Anterior extremity of the female (X 400).

Laboratório de Parasitologia, Faculdade de Farmácia, UFRGS, Porto Alegre, RS, Brazil.

Correspondence to: Prof. Geraldo A. De Carli. Rua Cel. Lucas de Oliveira 597/302, 90440-011, Porto Alegre, RS, Brazil.

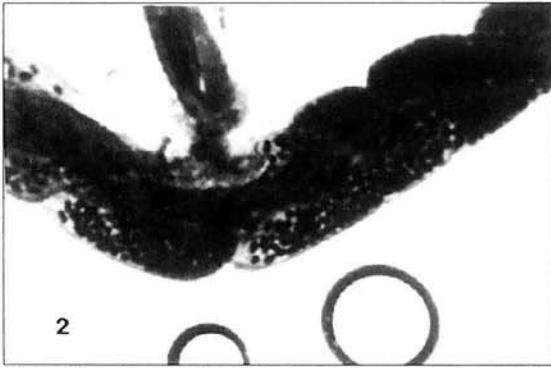


Fig. 2 - The male attached to the female by the copulatory bursa (X 200).

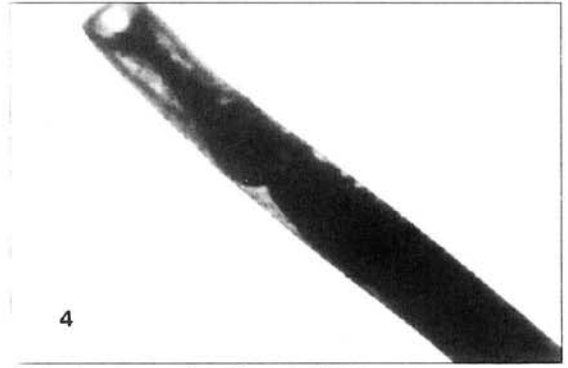


Fig. 4 - Anterior extremity of the male (X 200).




Fig. 3 - Posterior end of the female (X 400).



Fig. 5 - *Mammomanogamus (Syngamus) laryngeus*. Eggs (X 400).

The female and the male measured 9.0mm and 3.2mm respectively. The anterior extremity of the female showed a large buccal capsule with eight triangular teeth at base (Fig. 1). The male was attached to the female by the copulatory bursa, in the typical "Y"-shaped appearance (Fig. 2). Figure 3 shows the typical posterior extremity of the female, while Fig. 4 shows the anterior extremity of the male, and Fig. 5 shows the eggs. The stool and sputum examination was not performed.

REFERENCES

1. AMARAL, A.D.F.; QUAGLIA, F.O. & INOUE, C.R. - Sobre novo caso de singamose humana. **Rev. méd. S. Paulo**, 38: 1-9, 1954.
2. BIRREL, D.J.; MOORHOUSE, D.E.; GARDNER, M.A. & MAY, C.S. - Chronic cough and haemoptysis due to a nematode *Syngamus laryngeus*. **Aust. N. Z. J. Med.**, 8: 168-170, 1978.
3. BUSETTI, E.T.; SOCCOL, V.T.; RUIS, M.C.E. & CHRISTO, S.W. - *Mammomanogamus laryngeus (Syngamidae)*. Ocorrência parasitária no homem. In: CONGRESO DE LA FEDERACIÓN LATINOAMERICANA DE PARASITÓLOGOS, 6., CONGRESO DA SOCIEDADE BRASILEIRA DE PARASITOLOGIA, 8. & JORNADA PAULISTA DE PARASITOLOGIA, 5., São Paulo, 1983. **Resumos**, p. 105.
4. DUFAT, R.; SANG, H.T.; HERRENSCHMIDT, J.L.; VERGEZ, P. & ANDRÉ, J. - A propos d'un nouveau cas de syngamose bronchique humaine en provenance de la Martinique. **J. franç. Méd. Chir. thor.**, 25: 547-554, 1971.
5. GARDINER, C.H. & SCHANTZ, P.M. - *Mammomanogamus* infection in a human. **Amer. J. trop. Med. Hyg.**, 32: 995-997, 1983.
6. JUNG, C.; PHILBERT, M. & SANG, H.T. - Une observation de syngamose humaine à localisation bronchique. Premier cas traité et guéri par le thiabendazole. **Bull. Soc. Path. exot.**, 63: 483-488, 1970.
7. LEERS, W.D.; SARIN, M.K. & ARTHURS, K. - Syngamosis, a unusual cause of asthma: the first reported case in Canada. **Canad. med. Ass. J.**, 132: 269-270, 1985.
8. LEIPER, R.T. - Gapes in man, an occasional helminthic infection: a notice of its discovery by Dr. King in St. Lucia. **Lancet**, 1: 170, 1913.
9. LIMA, L.I. & BARBOSA, F. - Considerações em caso de singamose humana. **Publ. avul. Inst. Ageu Magalhães**, 1: 27-34, 1951.

10. LENT, H. & PENNA, M. - Novo caso de singamose em homem no Brasil. **Hospital (Rio de J.)**, 6: 111-118, 1939.
11. LONDERO, A.T. & LAUDA, P. - Infecção humana por *Syngamus laryngeus*. **Hospital (Rio de J.)**, 72: 329-331, 1967.
12. MACHADO, J.M.; DAVIDSON, S. & LOURES, J.C. - Mais um caso de singamose humana. **Atas Soc. Biol. Rio de J.**, 6: 18-20, 1962.
13. MACHADO, O. - Sobre *Syngamus laryngeus* (caracteres dos exemplares encontrados em um caso de Singamose no homem). **Bol. Inst. Vital Brasil**, 22: 61-68, 1938.
14. MELLO, M. & MELLO, S. - *Syngamus laryngeus* no homem. **Rev. flum. Med.**, 3: 457-460, 1938.
15. MELO, A.L.; TEIXEIRA, A.S.; GUERRA, A.F.M.; FORTINI, M.S. & FULGÊNCIO, M.S.T. - Parasitismo da rinofaringe pelo *Syngamus laryngeus*. **J. bras. Med.**, 46: 94-96, 1984.
16. MORAES, R.G. - Parasitismo humano pelo *Syngamus laryngeus*. **Arch. bras. Med.**, 37: 97-101, 1947.
17. MORNE, J.F.; MAGDELEINE, J. & THORÉ, J. - La syngamose humaine (*Mammomanogamus nasicola*), cause de toux chronique en Martinique: 37 observations recents. **Nouv. Presse méd.**, 47: 3628, 1980.
18. PASSOS, W. & BARBOSA, N.C. - *Syngamus laryngeus* na espécie humana. **Rev. bras. Med.**, 5: 340, 1948.
19. SANTOS, V.A.; VILELA, M.S.H. & SERRA, R.G. - Ocorrência de um novo caso de singamose humana em São Paulo. **Rev. Inst. Med. trop. S. Paulo**, 28: 358-363, 1986.
20. SEVERO, L.C.; CONCI, L.M.A.; CAMARGO, J.J.P.; ANDRADE-ALVES, M.R. & PALOMBINI, B.C. - Syngamiasis: two new Brazilian cases and evidence of a possible pulmonary cycle. **Trans. roy. Soc. trop. Med. Hyg.**, 82: 467-468, 1988.
21. St. JOHN, J.H.; SIMMONS, J.S. & GARDNER, L.L. - Infestation of the lung by a nematode of the genus *Cyathostoma*. **J. Amer. med. Ass.**, 92: 1816-1818, 1929.
22. TIMMONS, R.F.; BOWERS, R.E. & PRICE, D.L. - Infection of the respiratory tract with *Mammomanogamus (Syngamus) laryngeus*: a new case in Largo, Florida, and a summary of previously report cases. **Amer. Rev. resp. Dis.**, 128: 566-569, 1983.
23. TRAVASSOS, L. - Notas helmintológicas. **Brasil-méd.**, 35: 67, 1921.
24. WEINSTEIN, L. & MOLAVI, A. - *Syngamus laryngeus* infection (syngamiasis) with chronic cough. **Ann. intern. Med.**, 74: 577-580, 1971.
25. ZUNINO, J.N.; MORITZ, D.E.; ZOCCOLI, C.M. & BARTH, V.L. - Descrição de seis casos de singamose em Florianópolis. In: CONGRESSO DA SOCIEDADE BRASILEIRA DE MEDICINA TROPICAL, 25., Florianópolis, 1989. **Resumos**, p. 213.

Recebido para publicação em 18/07/1994.

Aceito para publicação em 12/09/1994.