

CASE REPORT

SPONTANEOUS RESOLUTION OF ZOONOTIC SPOROTRICHOSIS DURING PREGNANCY

Hiram Larangeira de ALMEIDA JR.(1,2), Cristiane Borges Evaldt LETTNIN(1), Juliana Lima BARBOSA(1) & Márcia Cristiane Feltrin DIAS(3)

SUMMARY

Sporotrichosis is the most common deep mycosis in Latin America. The zoonotic transmission from cats has been demonstrated over the last few decades in many countries. A forty year-old veterinarian examined a cat with multiple ulcerations, which mycological examination isolated *Sporothrix schenckii*. During the examination, she was bitten in the right index finger by the animal. Two weeks later, an inflammatory lesion appeared, which became ulcerated and was followed by ascendant lymphangitis. The diagnoses of lymphocutaneous sporotrichosis and of a six weeks pregnancy were established. The lesions were not treated and by the 28th week the ulceration healed and the abscesses showed involution. This case illustrates that non-life-threatening forms of sporotrichosis during pregnancy could be treated with systemic antifungals after delivery.

KEYWORDS: Sporotrichosis; Pregnancy; Spontaneous resolution

INTRODUCTION

Sporotrichosis has a worldwide distribution and has been especially noticed in tropical and temperate zones⁴. The causative agent can be found in decaying vegetation, soil, moss, wood and may infect a large diversity of animals, including cats. The usual mode of transmission is the traumatic cutaneous inoculation of the organism followed by lymphatic spread.

Sporotrichosis is the most common subcutaneous mycosis in Latin America⁶ and Brazil^{3,9,13,14}. The zoonotic potential of cats has been demonstrated over the last few decades in Brazil^{3,9,15,17,18}, Mexico⁵ and the United States⁸, recognizing the importance of this mode of transmission and alerting people who works with these animals^{8,20}. Treatment consists of the administration of systemic antifungal or iodides and on very rare occasions has a spontaneous cure been related. In this case the disease in a pregnant woman had resolution without intervention.

CASE REPORT

A forty year-old veterinarian examined a cat with multiple ulcerations (Fig. 1) which mycological examination isolated *Sporothrix schenckii*. During the examination, she was bitten in the right index finger by the animal. Two weeks later, an inflammatory lesion appeared in the same finger, which became ulcerated (Fig. 2a) and was followed by ascendant lymphangitis in the right arm (Fig. 2c). *S. schenckii* was identified again by the mycological examination. As well as the diagnosis

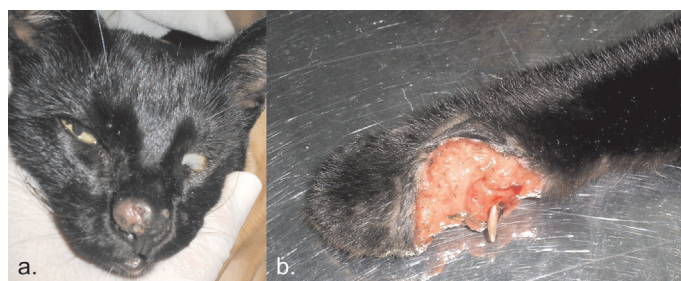


Fig. 1 - Ulcerations on the nasal region (a) and in a paw (b).

of lymphocutaneous Sporotrichosis, a six weeks pregnancy was also diagnosed.

Since there is not a safe systemic antifungal treatment for sporotrichosis during the first trimester of pregnancy and a low risk of dissemination to the fetus², no medicamentous treatment was prescribed. Interestingly by the 28th week the ulceration healed (Fig. 2b) and the abscesses showed involution with residual erythema in the following weeks (Fig. 2d). She had an uncomplicated cesarean delivery and the child was born healthy.

DISCUSSION

Few cases of spontaneous resolution of sporotrichosis have been reported^{1,2,7,10,16}. Most of them were localized cutaneous disease, without

(1) Department of Dermatology, Federal University of Pelotas, RS, Brazil.

(2) Department of Dermatology, Catholic University of Pelotas, RS, Brazil.

(3) Microbiology, Federal University of Rio Grande, RS, Brazil.

Correspondence to: Dr. Hiram de Almeida Jr., Faculdade de Medicina da UFPEL, Av. Duque de Caxias 250, 96.030-002 Pelotas, RS, Brasil, Phone: +55-53-3278 2909, Fax: +55-53-3278 7582, E-mail: hiramalmeidajr@hotmail.com

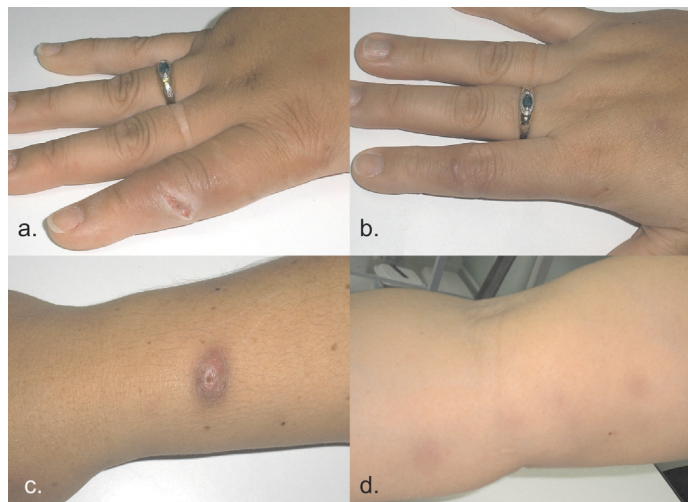


Fig. 2 - Ulceration in the right index finger (a.). Spontaneous remission after 28 weeks (b). Abscess in the right forearm (c). Residual erythema of the lymphatic spread on the right arm (d).

lymphatic involvement and the mode of transmission was not known.

Treatment of deep mycoses during pregnancy is a dilemma because there are no safe oral home-made treatments¹². Azole therapy, which is considered the best choice to most of them, cannot be used during pregnancy due its teratogenic potential. Another possibility in these cases is local thermotherapy.

The immune system changes during pregnancy are not fully understood, probably a shift from cell-mediated immunity toward humoral immunity occurs¹¹, besides the immunological tolerance to fetal antigens¹⁹. Several infectious diseases such as malaria, influenza, varicella and measles may have a more severe course¹¹, paradoxically we could observe a remission of a deep fungal infection without any treatment.

This case illustrates that non-life-threatening forms of sporotrichosis could be treated after delivery, as proposed the literature¹² and the possibility of spontaneous resolution could be considered.

RESUMO

Regressão espontânea de esporotricose zoonótica durante a gestação

Esporotricose é a micose profunda mais comum na América Latina. Sua transmissão zoonótica a partir de gatos foi documentada nos últimos anos em vários países. Médica veterinária foi mordida por um gato, que apresentava múltiplas ulcerações, das quais foi isolado *Sporothrix schenckii*. Duas semanas depois surgiu lesão inflamatória e após uma ulceração no dedo mordido, seguida de linfangite ascendente. Esporotricose linfocutânea e de gravidez foram então diagnosticados. As lesões não foram tratadas e na 28ª semana de gravidez a ulceração cicatrizou e os abscessos sofreram involução. Esse caso demonstra que formas menos graves de esporotricose poderiam ser tratadas com antifúngicos sistêmicos depois do parto.

REFERENCES

1. BARGMAN, H.B. - Sporotrichosis of the nose with spontaneous cure. *Canad. med. Assoc. J.*, **124**: 1027, 1981.
2. BARGMAN, H. - Sporotrichosis of the skin with spontaneous cure: report of a second case. *J. Amer. Acad. Derm.*, **8**: 261-262, 1983.
3. BARROS, M.B.; SCHUBACH, T.M.; GALHARDO, M.C. *et al.* - Sporotrichosis: an emergent zoonosis in Rio de Janeiro. *Mem. Inst. Oswaldo Cruz*, **96**: 777-779, 2001.
4. BEZERRA, L.M.L.; SCHUBACH, A. & COSTA, R.O. - *Sporothrix schenckii* and sporotrichosis. *An. Acad. bras. Ciênc.*, **78**: 293-308, 2006.
5. BOVE-SEVILLA, P.M.; MAYORGA-RODRÍGUEZ, J. & HERNÁNDEZ-HERNÁNDEZ, O. - Sporotrichosis transmitted by a domestic cat. Case report. *Med. cut. ibero lat-amer.*, **36**: 33-35, 2008.
6. CONTI-DIAZ, I.A. - Epidemiology of sporotrichosis in Latin America. *Mycopathologia (Den Haag)*, **108**: 113-116, 1989.
7. DESGARENNES, M.D.C.P.; ZAMBRANO, S.P.S. & COLOMA, J.N.S. - Esporotricose con involución espontánea. *Dermatología (Méx.)*, **51**: 14-19, 2007.
8. DUNSTAN, R.W.; REIMANN, K.A. & LANGHAM, R.F. - Feline sporotrichosis. *J. Amer. Vet. med. Ass.*, **189**: 880-883, 1986.
9. FLEURY, R.N.; TABORDA, P.R.; GUPTA, A.K. *et al.* - Zoonotic sporotrichosis. Transmission to humans by infected domestic cat: report of four cases in São Paulo, Brazil. *Int. J. Derm.*, **40**: 318-322, 2001.
10. IWATSU, T.; NISHIMURA, K. & MIYAJI, M. - Spontaneous disappearance of cutaneous sporotrichosis. Report of two cases. *Int. J. Derm.*, **24**: 524-525, 1985.
11. JAMIESON, D.J.; THEILER, R.N. & RASMUSSEN, S.A. - Emerging infections and pregnancy. *Emerg. infect. Dis.*, **12**: 1638-1643, 2006.
12. KAUFFMAN, C.A.; BUSTAMANTE, B.; CHAPMAN, S.W. & PAPPAS, P.G. - Clinical practice guidelines for the management of sporotrichosis. Infectious Diseases Society of America. *Clin. infect. Dis.*, **45**: 1255-1265, 2007.
13. LONDERO, A.T. & RAMOS, C.D. - Esporotricose no Rio Grande do Sul. Três décadas de observação. *An. bras. Derm.*, **64**: 307-310, 1989.
14. LOPES, J.O.; ALVES, S.H.; MARI, C.R. *et al.* - Epidemiologia da esporotricose na região central do Rio Grande do Sul. *Rev. Soc. bras. Med. trop.*, **32**: 541-545, 1999.
15. MARQUES, S.A.; FRANCO, S.R.; CAMARGO, R.M. *et al.* - Sporotrichosis of the domestic cat (*Felis catus*): human transmission. *Rev. Inst. Med. trop. S. Paulo*, **35**: 327-330, 1993.
16. MAYORGA, R.; CÁCERES, A.; TORIELLO, C. *et al.* - Étude d'une zone d'endemie sporotrichosique au Guatemala. *Med. Mycol.*, **16**: 185-198, 1978.
17. NOBRE, M.O.; CASTRO, A.P.; CAETANO, D. *et al.* - Recurrence of sporotrichosis in cats with zoonotic involvement. *Rev. Iberoamer. Micol.*, **18**: 137-140, 2001.
18. OLIVEIRA-NETO, M.P.; MATTOS, M.; LAZERA, M.; REIS, R.S. & CHICARINO-COELHO, J.M. - Zoonotic sporotrichosis transmitted by cats in Rio de Janeiro, Brazil. A case report. *Derm. OnLine J.*, **8**(2): 5, 2002.
19. SARAFANA, S.; COELHO, R.; NEVES, A. & COSTA TRINDADE, J. - Aspectos da imunologia da gravidez. *Acta. méd. port.*, **20**: 355-358, 2007.
20. SCHUBACH, A.; BARROS, M.B. & WANKE, B. - Epidemic sporotrichosis. *Curr. Opin. infect. Dis.*, **21**: 129-133, 2008.

Received: 23 February 2009

Accepted: 1 July 2009