

CASE REPORT

Fusobacterium necrophorum CAUSING INFECTIVE ENDOCARDITIS AND LIVER AND SPLENIC ABSCESES

Marc Zac HANDLER(1), Benjamin MIRIOVSKY(1), Howard E. GENDELMAN & Uriel SANDKOVSKY(1,2)

SUMMARY

A 25-year-old male without prior co-morbidities was admitted to hospital with *Fusobacterium necrophorum* bacteremia, where he was found to have liver and splenic abscesses. Further evaluation with echocardiography revealed a bicuspid aortic valve with severe insufficiency and a 1.68 x 0.86 cm vegetation. The patient required abscess drainage, intravenous antimicrobial therapy and aortic valve replacement. Complete resolution of the infection was achieved after valve replacement and a prolonged course of intravenous antimicrobial therapy. A brief analysis of the patient's clinical course and review of the literature is presented.

KEYWORDS: *Fusobacterium necrophorum*; Infective endocarditis.

INTRODUCTION

Fusobacterium necrophorum is an obligate anaerobic filamentous gram-negative rod that frequently colonizes the mouth and respiratory tract. The classic clinical presentation of infection due to *F. necrophorum* is septic jugular thrombophlebitis (also called Lemierre's syndrome) with findings of sore throat, persistent fever, soft tissue or neck swelling and bacteremia⁷. There is increasing evidence for *F. necrophorum* as a cause of endemic pharyngitis in adolescents and young adults with an estimated incidence that could parallel that of the group A *Streptococcus*⁵. *F. necrophorum* may also cause intraabdominal infections, peritonitis, septic arthritis, brain abscesses and less frequently, infective endocarditis (IE)⁶⁻⁹.

CASE REPORT

A 25-year-old Caucasian male without significant past medical history and no history of alcohol or illicit drug use presented to the emergency room in December 2009 with a one week- history of sore throat, fever and chills, nausea, vomiting and watery diarrhea. He was given hydration and sent home. Two days later he was seen at his primary care provider's office where he was diaphoretic, febrile to 39 °C and hypotensive, and he was admitted to an outside hospital. On admission, his temperature was 39.2 °C, heart rate 99 beats per minute, blood pressure 137/80, and respirations 18 per minute. Physical examination showed a well nourished man with mild oropharynx edema without tonsillar drainage and no evidence of neck swelling. Lungs were clear and heart examination was notable for a 2/6 diastolic murmur best appreciated on

the lower right sternal border. The abdomen was benign without palpable spleen or liver or tenderness and there were no skin or mucosal lesions present on examination. The patient's WBC count was 24,000 cells/mm³, platelets 28000/mm³, creatinine 2.7 mg/dL (0.6-1.3) and BUN 41 mg/dL. Liver tests showed AST 44 U/L (10-40), ALT 48 U/L (30-65), albumin 2.2 mg/dL (3.5-5), alkaline phosphatase 210 U/L (43-138), total bilirubin 4.1 mg/dL (0-1.5) with direct bilirubin 3.6 mg/dL, and CRP 222 mg/dL (0.5-9 mg/dL). Two anaerobic blood culture bottles drawn on admission turned positive at 16 and 17 hours. Anaerobe phenylethyl alcohol blood agar (PEA), anaerobe kanamycin-vancomycin blood agar (KV) and enriched thioglycolate medium for anaerobes (THIO) were used and subsequently grew beta-lactamase negative *Fusobacterium necrophorum*. Intravenous piperacillin-tazobactam 3.375 grams every six hours was initiated with sterilization of subsequent blood cultures.

Initial computed tomography (CT) scans of the chest and abdomen performed without intravenous contrast showed no vascular lesions. There was splenomegaly and a 2 cm hypodense lesion on the right hepatic lobe. Ultrasound Doppler of the neck showed patent right neck veins although the left side was not evaluated. A CT scan of the neck - also without intravenous contrast - showed soft tissue swelling posterior to the right parotid gland but no other abnormalities. Ultrasound examination of the liver showed a 2.5 cm complex fluid collection on the right hepatic lobe. On the third hospital day the patient developed abdominal pain and persisted febrile despite proper antimicrobial therapy and a repeat CT scan of the abdomen showed two splenic lesions of 1.2 and 1.3 cm in diameter and a 3 cm complex liver lesion all of which enhanced with intravenous

Potential conflicts/disclosures: the authors have no conflicts of interest or disclosures.

(1) Department of Medicine.

(2) Division of Infectious Diseases.

(3) Department of Pharmacology and Experimental Neuroscience, University of Nebraska Medical Center, Omaha, NE, USA.

Correspondence to: Uriel Sandkovsky, MD. Division of Infectious Diseases, University of Nebraska Medical Center. 988106 Nebraska Medical Center, Omaha, NE. 68198-8106. Tel: 1 (402) 559-8664. Fax: 1 (402) 553-5527. E-mail: usandkovsky@unmc.edu

contrast, suggestive of abscesses. The liver lesion was aspirated five days after the start of antimicrobial therapy. Primarily due to concerns of thrombocytopenia, drainage was delayed. Blood cultures obtained at that time did not show bacterial growth. A transthoracic echocardiogram evidenced a bicuspid aortic valve with severe regurgitation but failed to show vegetations; however, a transesophageal echocardiogram (TEE) revealed severe aortic insufficiency and 1.68 x 0.86 cm mobile vegetation on the aortic valve (Fig. 1). Ten days into admission the patient's fever recurred with a recorded temperature of 40.3 °C. Re-evaluation of the abdomen with a CT scan showed a stable 3 cm liver abscess but an enlarged splenic fluid collection of 3 x 1.8 cm (Fig. 2 and 3). External drainage catheters were placed into both the splenic and hepatic lesions with resolution of the fever. On his third week of hospitalization he was transferred to the Nebraska Medical Center. A repeat TEE showed a smaller vegetation of ~ 7 mm on the aortic valve. He underwent aortic valve replacement with a mechanical valve. He was discharged to complete six weeks of antimicrobial therapy with 24 million units a day of penicillin G after surgery. Follow-up imaging showed resolution of the liver and splenic abscesses. The patient continues to follow in the outpatient clinic regularly and has not had any relapses.

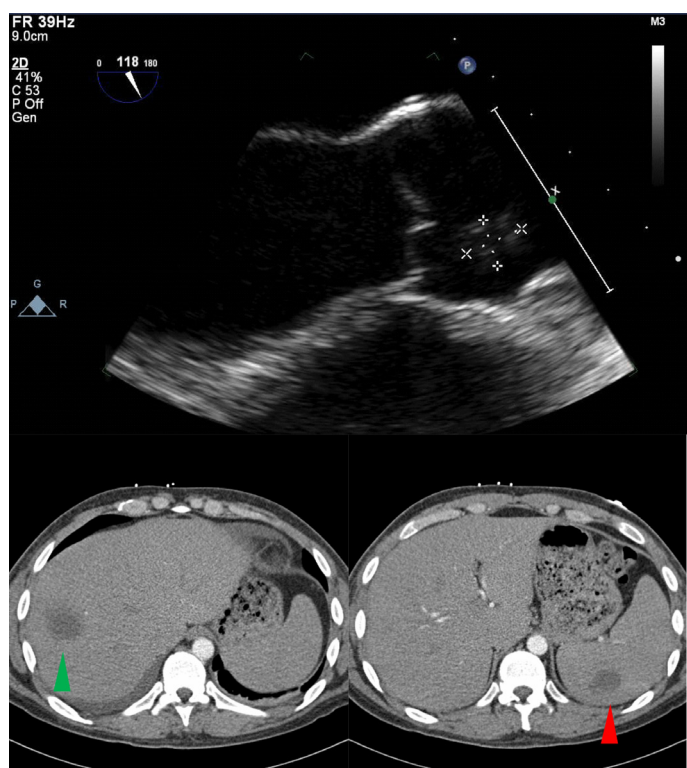


Fig. 1 - Above transesophageal echocardiogram showing an aortic valve vegetation. Figures 2 and 3 below: computed tomography of the abdomen demonstrating a liver abscess (green arrowhead) and splenic abscess (red arrowhead).

DISCUSSION

F. necrophorum is an obligate anaerobic filamentous gram-negative rod that frequently colonizes the mouth and respiratory tract. The classic clinical presentation of infection due to *F. necrophorum* is septic jugular thrombophlebitis (also called Lemierre's syndrome) with findings of

sore throat, persistent fever, soft tissue or neck swelling and bacteremia⁷. There is increasing evidence for *F. necrophorum* as a cause of endemic pharyngitis in adolescents and young adults with an estimated incidence that could parallel the one for group A *Streptococcus*⁵. *F. necrophorum* may also cause intraabdominal infections, peritonitis, septic arthritis, brain abscesses and, less frequently, as in this case, infective endocarditis (IE)⁶⁻⁹.

Anaerobic bacteria represent 1-16% of all cases of infective endocarditis⁴. Of the reported cases of *Fusobacterium spp* IE, 77 percent seeded from head and neck infections and 20 percent occurred in the setting of IV drug use. Most cases of IE caused by *F. necrophorum* have originated from the head and neck with one reported case in a patient with polymicrobial IE secondary to intravenous drug use (IVDU)^{1,6,9,12}. Interestingly, a recent report of a fatal case of mitral valve endocarditis caused by *F. necrophorum* in a 20 year-old female without clinical or post-mortem autopsy findings that could point to an originating source². Our patient had complained of a sore throat before admission to the hospital and imaging of the neck, although limited by the lack of intravenous contrast, did not show major or obvious findings. Moreover, there was no history of head and neck procedures that could have pointed to an originating source and nor did he use illicit drugs.

Although *F. necrophorum* is well known to cause septic embolization to distant sites, IE is still an uncommon finding. On the few reported cases of *F. necrophorum* endocarditis that have been identified, complications included heart failure, lung, liver, spleen and brain embolization, rapid valve destruction and death^{1,9,11,12}. Table 1 summarizes the previously reported cases of IE caused by *F. necrophorum*. Anaerobic bacterial endocarditis has been associated with lower frequency of preexisting valvular heart disease when compared to endocarditis caused by aerobic bacteria³. Our patient did have preexisting valvular heart disease (bicuspid aortic valve) that may have increased his risk substantially. The overall mortality for patients with anaerobic IE ranges between 21-43%⁴. Endocarditis due to *F. necrophorum* has been initially associated with a 75 percent mortality rate^{4,9,11,12}. Of the previously reported cases summarized in Table 1, it is interesting to note that almost half of them originated in the oropharynx, the left side of the heart was more commonly involved, almost half of them had embolic complications, three underwent valve replacement and the overall mortality rate was 50 percent if we exclude the three cases in which the outcome was unknown. Fatalities may be lower nowadays with the availability and prompt use of effective antimicrobial therapy, but the low number of reported cases and the lack of clinical studies may preclude any assumption. HUGGAN & MURDOCH identified 25 invasive infections caused by *F. necrophorum* among 78 clinical isolates with no reported fatalities, although no cases of IE were identified in this report⁸.

Clinical diagnosis should be suspected with the finding of high fever and rigors in patients with a history of sore throat, jugular vein thrombosis and septic embolization. Making the correct diagnosis may still prove to be difficult, even with the classic presentation of Lemierre's syndrome, because the disease is not usually suspected. The appearance of the throat may vary from normal to severe exudative tonsillitis and the neck vein thrombosis may be mistaken for cervical lymphadenopathy. Septic manifestations tend to occur several days after the sore throat has resolved and may also be initially attributed to other pathogens (i.e. cavitary lung lesions caused by *Staphylococcus aureus*). Imaging studies

Table 1
Summary of the reported case of infective endocarditis due to *F. necrophorum*

Authors	Age (years) and gender	Possible predisposing factors	Valve involved and complications	Treatment	Outcome
NASTRO & FINEGOLD ⁹	52, male	Dental fistula	Aortic valve, splenic emboli	No therapy	Death
	21, male	Tonsillar abscesses	Mitral valve, emboli to skin, joint, liver, lung	No therapy	Death
	37, unknown	Unknown	Mitral valve, CHF	Penicillin No valve replacement	Death
	Not stated	Not stated	Not stated	Not stated	Not stated
	Adult female, age unknown	Suppurative tonsillitis	Ao valve	No therapy	Death
	27, male	Pyorrhea	Valve unspecified, thrombophlebitis, emboli to brain and brain abscess	Hetacillin No mention of valve replacement	Alive
	47 male	Pneumonia, empyema, subphrenic abscess	Valve unspecified, Emboli to axillary artery, liver	Methicillin No mention of valve replacement	Alive
FELNER & DOWELL ⁶	Adult, unknown	Oropharyngeal disease	Unknown	Not mentioned	Unknown
	Adult, unknown	Oropharyngeal disease	Unknown	Not mentioned	Unknown
ADLER <i>et al.</i> ¹	39, male	IVDU.	Tricuspid valve polymicrobial endocarditis, CHF subclavian abscess	Initial Nafcillin+gentamicin then changed to penicillin and later Ampicillin and metronidazole Valve replacement	Alive
STUART & WREN ¹¹	2, male	Unknown	Mitral valve, pneumonia with empyema	Initially Azlocillin and gentamicin. Later ceftazidime, vancomycin and metronidazole. Delayed valve replacement	Alive
VEDIRE <i>et al.</i> ¹²	20, male	Unable to identify	Aortic valve, pulmonary edema	Piperacillin-tazobactam subsequently changed to Penicillin G. No valve replacement	Alive
AUGUSTO, <i>et al.</i> ²	20, female	Unable to identify	Mitral valve, pulmonary edema	Cefotaxime and levofloxacin Valve replacement	Death

CHF: congestive heart failure; IVDU: intravenous drug abuse.

such as ultrasound with doppler or CT scans of the neck may prove useful since jugular vein involvement is not readily recognized in clinical exam. Isolating the bacterium from clinical specimens is key for microbiological diagnosis. Growth is usually achieved with special media consisting of blood agar enriched with hemin, vitamin K, menadione and a reducing

agent. The colonies appear cream-yellow in color with almost all strains showing complete hemolysis in horse blood agar. Full identification can be completed with biochemical tests available in commercial kits¹⁰.

Treatment often involves surgical debridement of necrotic tissues

or drainage of abscesses. Because many *F. necrophorum* infections are polymicrobial and *F. necrophorum* may be penicillin resistant, initial antimicrobial therapy for life threatening cases should include a beta-lactam plus beta lactamase inhibitor such as piperacillin-tazobactam, a carbapenem or metronidazole and either a penicillin or third generation cephalosporin^{4,7,10}. Some authorities prefer to use metronidazole due to its excellent *in-vitro* activity, good tissue penetration and the possibility to switch to oral therapy. Duration of treatment varies depending on the site and severity of infection, although treatment courses of less than two weeks have been associated with relapses. Despite the lack of prospective studies, it would seem prudent to complete at least six weeks of antimicrobial therapy in cases of endocarditis like in our patient.

Similar to the case described by AUGUSTO *et al.*², we were unable to determine the originating source of our patient's bacteremia but we could also speculate that this patient's infection may have arisen from endemic pharyngitis.

This case serves as a reminder of the elusive clinical presentation of this particularly virulent organism, especially in the initial stages, the rapid clinical progression and the potential complications that can arise from this infection. Bacteremia caused by *F. necrophorum* has a high mortality rate especially due to the lack of specific signs and symptoms upon initial presentation. Morbidity and mortality is further increased by the presence of deep seated infections or endocarditis. Antimicrobial therapy alone may be insufficient with many patients often requiring surgical intervention. It is also important to remember that patients can present with bacteremia even without the classic history of IV drug abuse, head and neck procedures or the presence of oropharyngeal disease.

RESUMO

***Fusobacterium necrophorum* causando endocardite infecciosa e abscesso hepático e esplênico**

Homem de 25 anos de idade, sem antecedentes mórbidos foi admitido ao hospital com bacteremia por *Fusobacterium necrophorum* e abscessos no fígado e no baço. Avaliação posterior com ecografia revelou válvula aórtica bicúspide com insuficiência severa e vegetação de 1,68 x 0,86 cm. Foi feita drenagem dos abscessos, terapia antimicrobiana intravenosa e substituição da válvula aórtica. Resolução completa da infecção foi conseguida após substituição valvular e curso prolongado de terapêutica intravenosa antimicrobiana. É apresentada breve análise do curso clínico do paciente e revisão da literatura.

ACKNOWLEDGEMENT

Tara Whitmire, APRN and Dawn M Bodnar, MD for providing the echocardiogram images.

REFERENCES

1. Adler AG, Blumberg EA, Schwartz DA, Russin SJ, Pepe R. Seven-pathogen tricuspid endocarditis in an intravenous drug abuser. Pitfalls in laboratory diagnosis. *Chest*. 1991;99:490-1.
2. Augusto JF, Mercat A, Asfar P, Pinaud F, Croue A, Chausseret L. Fatal case of *Fusobacterium necrophorum* mitral endocarditis. *J Infect*. 2010;61:94-5.
3. Brook I. Endocarditis due to anaerobic bacteria. *Cardiology*. 2002;98:1-5.
4. Brook I. Infective endocarditis caused by anaerobic bacteria. *Arch Cardiovasc Dis*. 2008;101:665-76.
5. Centor RM. Expand the pharyngitis paradigm for adolescents and young adults. *Ann Intern Med*. 2009;151:812-5.
6. Felner JM, Dowell VR, Jr. Anaerobic bacterial endocarditis. *N Engl J Med*. 1970;283:1188-92.
7. Garrett WS, Onderdonk AB. Bacteroides, Prevotella, Porphyromonas, and Fusobacterium Species (and other medically important anaerobic Gram-Negative Bacilli). In: Mandell GL, Bennett JE, Dolin R. Mandell, Douglas, and Bennett's principles and practice of infectious diseases. 7th ed. Philadelphia: Churchill Livingstone/Elsevier; 2010. p. 3111-9.
8. Huggan PJ, Murdoch DR. Fusobacterial infections: clinical spectrum and incidence of invasive disease. *J Infect*. 2008;57:283-9.
9. Nastro LJ, Finegold SM. Endocarditis due to anaerobic gram-negative bacilli. *Am J Med*. 1973;54:482-96.
10. Riordan T. Human infection with *Fusobacterium necrophorum* (Necrobacillosis), with a focus on Lemierre's syndrome. *Clin Microbiol Rev*. 2007;20:622-59.
11. Stuart G, Wren C. Endocarditis with acute mitral regurgitation caused by *Fusobacterium necrophorum*. *Pediatr Cardiol*. 1992;13:230-2.
12. Vedire S, Alpert MA, Ren J, Manian FA. *Fusobacterium necrophorum* endocarditis in a previously healthy young adult. *Am J Med Sci*. 2007;334:125-7.

Received: 20 January 2011

Accepted: 19 April 2011