Rev. Latino-Am. Enfermagem
2022;30:e3693
DOI: 10.1590/1518-8345.5786.3693
www.eerp.usp.br/rlae

RLAE
Revista Latino-Americana de Enfermagem

Original Article

Effects of photobiomodulation (660 nm laser) on anthracycline extravasation: An experimental study*

Karina Alexandra Batista da Silva Freitas[1]
https://orcid.org/0000-0002-3413-8468
Eliana Maria Minicucci[1]
https://orcid.org/0000-0002-4664-6929
Valéria Flávia Batista da Silva[2]
https://orcid.org/0000-0001-5784-9265
Benedito Donizete Menozzi[3]
https://orcid.org/0000-0001-5393-5799
Hélio Langoni[3]
https://orcid.org/0000-0001-5127-0762
Regina Célia Popim[1]
https://orcid.org/0000-0001-8341-1590

Highlights: (1) Using photobiomodulation proved to be effective in doxorubicin extravasation. **(2)** Photobiomodulation can be considered a possible antidote for extravasation. **(3)** It favors better quality of life in the patient, through a reduction in the formation of lesions. **(4)** It exerts no deleterious effects on the body as some medications do. **(5)** It is a low-cost therapy when compared to other antidotes.

Objective: to investigate the effect of using different agents (topical hyaluronidase, photobiomodulation, and the association of photobiomodulation with topical hyaluronidase) in preventing the formation of lesions caused by doxorubicin extravasation, as well as in the reduction of lesions formed by extravasation of this drug. **Method:** a quasi-experimental study conducted with 60 Wistar rats, randomized into four groups with 15 animals each. Group 1 (Control); Group 2 (Hyaluronidase); Group 3 (Photobiomodulation); and Group 4 (Hyaluronidase + Photobiomodulation). A wound was induced by applying 1 mg of doxorubicin to the subcutaneous tissue of the back of the animals. The concentration of topical hyaluronidase was 65 turbidity units/g and the energy employed was 1 joule of 100 mW red laser *per* square centimeter. With macroscopic evaluation every two days for 28 days, the following variables were observed: skin integrity, presence of blisters, hyperemia, exudate, bleeding, edema, crust, peeling and granulation tissue. **Results:** the animals from the groups subjected to photobiomodulation obtained better results in the assessment of the following variables: bleeding, hyperemia, exudate, intact skin and edema. **Conclusion:** it was evidenced that the association of photobiomodulation with topical hyaluronidase was effective in reducing the local effects and assisted in the wound healing process, and that PBM alone was able to prevent appearance of lesions.

Descriptors: Low-Level Light Therapy; Extravasation of Diagnostic and Therapeutic Materials; Antineoplastic Agents; Wistar Rats; Nursing Care; Adverse Effects.

* Paper extracted from doctoral dissertation "Effects of photobiomodulation (laser 660nm) on anthracycline extravasation: experimental study", presented to Universidade Estadual Paulista "Júlio de Mesquita Filho", Faculdade de Medicina de Botucatu, Departamento de Enfermagem, Botucatu, SP, Brazil.

[1] Universidade Estadual Paulista "Júlio de Mesquita Filho", Faculdade de Medicina de Botucatu, Departamento de Enfermagem, Botucatu, SP, Brazil.
[2] Universidade Estadual de Mato Grosso do Sul, Unidade Universitária de Mundo Novo, Mundo Novo, MS, Brazil.
[3] Universidade Estadual Paulista "Júlio de Mesquita Filho", Faculdade de Medicina Veterinária e Zootecnia de Botucatu, Botucatu, SP, Brazil.

How to cite this article

Freitas KABS, Minicucci EM, Silva VFB, Menozzi BD, Langoni H, Popim RC. Resilience and the reduction of occupational stress in Nursing. Rev. Latino-Am. Enfermagem. 2022;30:e3693. [Access month day year]; Available in: URL. https://doi.org/10.1590/1518-8345.5786.3693

Introduction

Extravasation of antineoplastic agents (EA) is the most feared adverse event in Oncology, with the possibility of causing serious injuries, especially when the medication involved is classified as vesicant[1]. When infused outside a vessel, vesicant medications cause bubbles and necrosis. With a reported incidence in the literature from 0.1% to 6%, its main signs and symptoms are infusion stop, absence of venous return, burning sensation, hyperemia, edema and pain. As it is also considered as an emergency in Oncology, it requires a duly qualified and trained Nursing team for immediate treatment of this event. In view of this, it is necessary to investigate actions towards the prevention of complications referring to extravasation[1-2].

One of the most feared vesicant medications is doxorubicin (DOX), an anthracycline binding to Deoxyribonucleic Acid (DNA) that binds to the nucleic acids of tissues, generating free radicals, inhibiting the synthesis of local proteins and leading the tissue to chronic, progressive and increased necrosis, making the lesion deeper, more extensive and painful, exerting direct impacts on the patient's quality of life. It can remain in tissues for up to 28 days, which requires constant evaluation[3].

Currently, dexrazoxane is the antidote used in DOX extravasation. Its use is approved by the Food and Drugs Administration (FDA) and by the European Commission and has 98% efficacy. The mechanism of action is binding of the drug to the iron molecule preventing the formation of free radicals[4]. In addition to being unfeasible for the public sector (due to its price), it can cause side effects such as nausea, vomiting, mild pain at the infusion site and reversible increases in liver enzymes[2,5].

Hyaluronidase is a widely used antidote in the extravasation of chemotherapeutics; however, it is specific for non-DNA-binding vesicants (vinca and taxane alkaloids), although it is a potential antidote for anthracyclines. This medication modifies tissue permeability by hyaluronic acid hydrolysis, promoting reabsorption of fluids and reducing the edema. This enzyme is an antidote recommended by the Oncology Nursing Society (ONS), which 1.0 ml subcutaneous application of 150 UI/ml to the extravasation area[1,6-8]. After ten minutes since application, an increase in diffusion of the overflowed liquid can be seen in an area from 3 to 5 times greater than in an untreated area. Tissue permeability is restored from 24 to 48 hours after applying the antidote[2,7,9].

Photobiomodulation (PBM) consists in irradiating non-ionizing light and is classified according to its wavelength into visible red (622-780 nm) or infrared (780-1,500 nm). It is quite used to accelerate the healing process of various types of lesions, promoting improvements in the patients' quality of life and speeding up the treatments[10]. When applying PBM, photochemical and photophysical reactions occur where excitation of the electrons that release adenosine triphosphate (ATP) used by the cells for development of their functions is stimulated[8,11-13].

For this, it is necessary that light is absorbed by chromophores, which are interrelated molecules (enzymes, cell membranes, extracellular substances) with the ability to absorb light. Cytochrome C Oxidase (CCO) is the main chromophore and is located in unit IV of the mitochondrial respiratory chain. CCO absorption mainly by the red wavelength leads to photodisconnection of nitric oxide (NO), resulting in a reduction of oxidative stress and, consequently, in an increase in the production of reactive oxygen species (ROS), ATP and Ca^{2+} ions, favoring the intended biological response (anti-inflammatory, analgesic, scarring) and increasing cell differentiation, proliferation and migration[11,13].

The association between topical hyaluronidase 65 UTR/g and PBM is already used in an Oncology Outpatient service of a tertiary-level Public Hospital from the inland of the state of São Paulo. However, despite excellent results, the number of patients with extravasation is low, and there is no scientific evidence on this association. Consequently, it was necessary to conduct an experimental study to evidence this practice, thus justifying this study.

Therefore, the objective of this research was to investigate the effect of using different agents (topical hyaluronidase, PBM, and the association of PBM with topical hyaluronidase) in preventing the formation of lesions caused by antineoplastic DOX extravasation, as well as the reduction of lesions formed after extravasation of this drug.

Method

Type of study

An experimental study conducted with 60 albino Wistar adult female rats of the *Rattus norvegicus* species, aged between 3 and 4 months old. In randomized experimental studies, the researcher randomly assigns the subjects to a control group and to one or more experimental groups, minimizing selection bias, in addition to allowing isolating the effect of an intervention[14].

Study locus and period

The experiment was carried out from 08/15/2019 to 09/16/2019 at the Experimental Laboratory for Diagnosis of Zoonoses, Department of Veterinary Hygiene and Public Health, School of Veterinary Medicine and Zootechnics, UNESP, Botucatu-SP, Brazil.

Population

The animals were provided by the Creation Vivarium located in the Biotechnology Institute (*Instituto de Biotecnologia*, IBTEC) of the "Júlio de Mesquita Filho" State University of São Paulo. Immediately after that, they were kept in the Experimentation Vivarium for a 15-day adaptation period, and only then were they submitted to the experiment. Female rats were selected due to their differences regarding behavior and aggressiveness when compared to males, easing manipulation. Throughout the period, temperature, ammonia level and bed change were controlled, as well as water supply and *ad libitum* feed. They were clinically examined by a veterinarian at admission to the laboratory and during the entire experiment. In order to ensure environmental enrichment, paper rolls were places in the cages in an attempt to reduce the stress caused by manipulation and isolation.

Selection and randomization criteria

To perform the randomization procedure, after the adaptation period, the animals were identified with numbers from 1 to 60, with a pilot pen in the dorsal region. Four envelopes were prepared and identified with the type of treatment, as follows:

Envelope 1: Control Group (no antidote).
Envelope 2: Hyaluronidase Group (H).
Envelope 3: Photobiomodulation Group (PBM).
Envelope 4: Photobiomodulation + Hyialuronidase Group (PBM+H).

Subsequently, one of the laboratory team members made a draw with numbers from 1 to 60.

The first 15 animals drawn were allocated to Envelope 1, and so on.

Each group consisted of 15 animals that were housed in rectangular polypropylene cages with 5 animals each, placed on ALESCO® ventilated racks, kept under room temperature and with free movement. It is important to note that, after DOX inoculation, the animals were separated, keeping them in individual cages.

The cages were identified with the numbers corresponding to the animals and with the group to which they belonged.

Sample definition

Considering that there is 50% occurrence of necrosis cases control) and assuming that application of the treatment reduces this percentage to zero (no necrosis), the minimum size for carrying out the experiment with a 5% margin of error, 95% compatibility and 90% power will be 15 animals per group (60 animals for all 4 groups).

Study variables

The qualitative variables analyzed were related to the appearance of the extravasation site and to the formation or not of lesions such as: intact skin, blister (intact or ruptured), hyperemia (marginal, central, or generalized), exudate (absent, mild, moderate, severe), bleeding (absent, mild, moderate, severe), edema (absent, mild, moderate, severe), crust (absent and present: loosely adhered, very adhered), peeling (absent or present – mild, moderate, severe) and granulation tissue (present, absent).

Instruments used for data collection

The process of wound formation was monitored by the researcher every 48 hours for 28 days, through an evaluation form that included presence of intact skin, blisters, hyperemia, exudate, bleeding, edema, crust, peeling and granulation tissue(15). At the same time, a database of photographic records (CANON Power Shot SX170IS digital camera with 1/250 speed and distance of 0.7) was prepared to assist in interpreting evolution of the wounds. Angle and distance of the photographs were calculated by a professional photographer from the Botucatu Medical School, in order to standardize the images.

Data collection

After the adaptation period, the animals were subjected to inhalational general anesthesia with isoflurane gas and trichotomy of the dorsal region with an electric trichotomizer and administered 1.0 mg of DOX (0.5 ml) in the subcutaneous tissue located between the scapula and the end of the ribs, using a graduated 1 ml syringe and a 13 G x 4.5 mm hypodermic needle.

The DOX vial contained 10 mg in 5 ml, making up an equivalent of 2 mg/ml. 0.5 ml of the solution was aspirated, containing a total of 1 mg of DOX. A research study carried out with extravasation in rats proved that an intradermal injection of 1 mg of DOX was capable of causing necrosis[6].

The hyaluronidase used in the study was manipulated at the *Cruz Vermelha* Pharmacy in Botucatu-SP, with a concentration of 65 UTR with 1 g base cream.

After DOX inoculation, the antidotes were applied as follows:

- Control Group (no antidote): no antidote was applied;
- Hyaluronidase Group (H): the topical hyaluronidase antidote was applied 15 minutes after inoculation and, daily, in the form of an ointment on the entire back of the animal, even in the presence of lesion;

- PBM Group: application of 100 mW PBM, 1 joule red light (10 seconds), wavelength of 660 nm, at the inoculation point occurred 10 minutes after administration of doxorubicin. In the subsequent days, in the animals that did not show lesions, 1 point of 1 joule (10 seconds) of PBM was performed at the inoculation point. When lesions appeared, in wounds up to 1 cm in area, a 1 joule point was irradiated (10 seconds), with a total energy of 1 joule in the center of the lesion; in wounds up to 2 cm in area, it was irradiated to the North, South, East and West (totaling 4 points – 40 seconds), with a total energy of 4 joules. Topical dressings with primary coverage were not performed, leaving the lesion area exposed.
- PBM+H Group: PBM was performed as reported in the PBM Group and, immediately after the laser, the hyaluronidase antidote was applied, as described in the H Group.

A pen-shaped semiconductor diode laser device was used (Therapy EC, DMC group, São Carlos, SP, Brazil), which emits two wavelengths: a laser diode at 660 nm (red) and a laser diode 808 nm (infrared). Peak emission power was 100 mW, in continuous mode delivery. The spacer at the end of the device was used, as well as a PVC film to avoid cross-contamination and wear of the appliance.

The wound formation process was monitored by the researcher every 48 hours for 28 days and euthanasia was performed at day 30.

Data treatment and analysis

After data tabulation, a qualitative and descriptive analysis of the variables (bleeding, hyperemia, exudate, bleeding, edema, crust, peeling and granulation tissue) was performed by group (Control, Hyaluronidase, PBM and PBM+H) throughout the treatment days.

Ethical aspects

The research was approved on 02/11/2019 by the Commission of Ethics in Use of Animals (*Comissão de Ética no Uso de Animais*, CEUA) at the Botucatu Veterinary and Zootechnics School - UNESP, with protocol No. 0026/2019.

Results

It was observed that the groups that made use of hyaluronidase showed more animal losses (H: 09/15: 60% and PBM+H: 8/15: 53.3%). We believe that this loss can be related to several factors such as: toxicity generated by anthracycline, toxicity by hyaluronidase, and factors related to animal behavior. Although the groups were evaluated every two days, hyaluronidase was administered daily, with the possibility that such manipulation of the animals be considered stressing.

It was noticed that some animals from the PBM group (4/15: 26%) did not show lesions (Figure 1). In animals that presented lesions, it was observed that they started at D4, becoming more evident in group C (7/15: 46%) with the maximum time for wound formation at D8 for the photobiomodulation group.

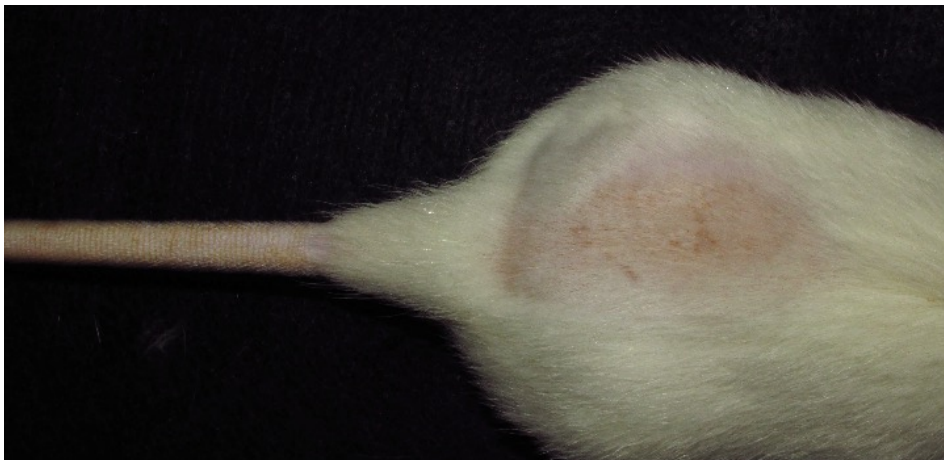

Figure 1 - An animal from the PBM+H group at D28, without lesions in the back after doxorubicin extravasation. Botucatu, SP, Brazil, 2019

Hyperemia was already observed at the first evaluation day (D2) in most of the animals analyzed from groups C and H, extending up to D16. It was observed that in the groups in which PBM was used, few animals presented hyperemia, with a maximum peak at D4 for both groups, with a lower frequency of animals involved, PBM (5/15: 33%) and PBM+H (9/15: 60%) (Figure 2).

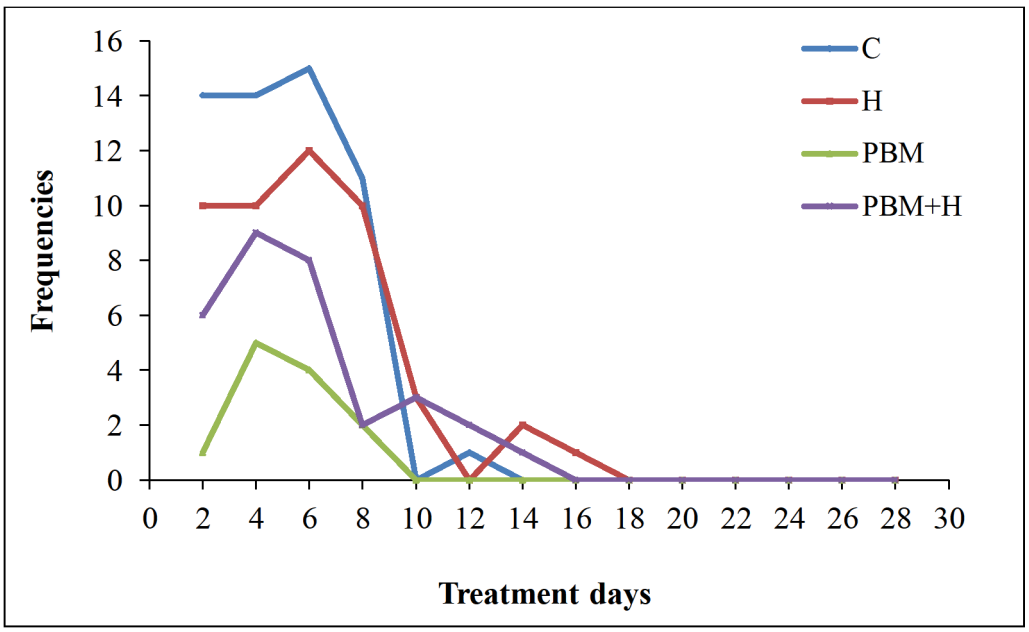

Figure 2 - Frequency of animals with hyperemia after DOX inoculation in subcutaneous tissue, in all four groups and throughout the treatments. C = Control; H = Hyaluronidase; PBM = Photobiomodulation; PBM+H = Photobiomodulation + Hyaluronidase. Botucatu, SP, Brazil, 2019

Exudate was mostly found in Group C (14/15: 93%) starting at D10, reaching a maximum number of animals at D12 and extending until the end of the experiment. The animals that participated in the PBM and PBM+H groups did not show formation of exudate until the end of the experiment.

Of the animals from the groups with PBM, only one presented bleeding during the entire research. In turn, the animals from groups C (9/15: 60%) and H (7/15: 46.6%) showed bleeding at the third evaluation day (D6).

Crust was observed throughout the research in animals from all groups, although in a smaller number of animals from groups H, PBM and PBM+H.

Figure 4 shows that granulation tissue was more found in animals from the PMB and PBM+H groups, as early as D12. The lesions were in the healing process, with replacement of granulation tissue by epithelium from D20 onwards.

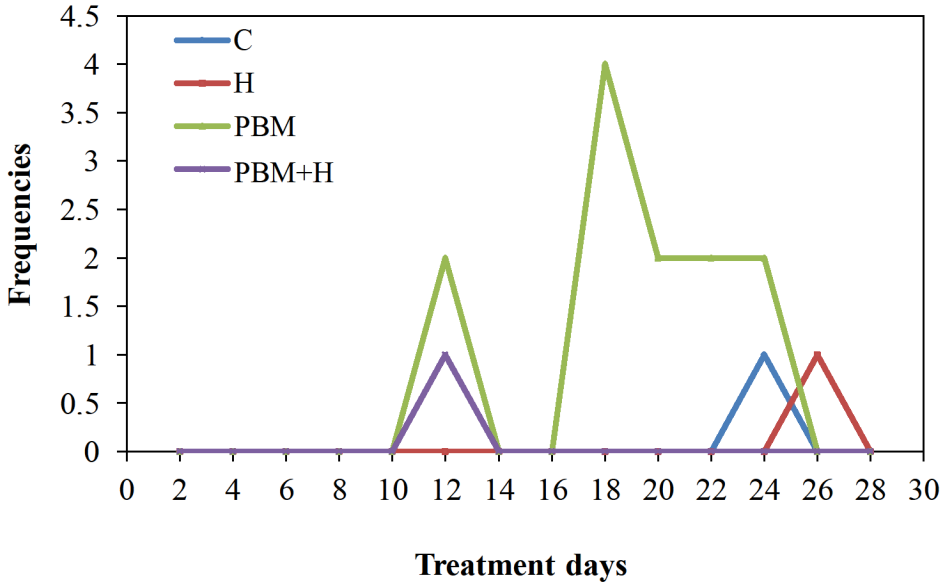

Figure 3 - Frequency of animals with granulation tissue after DOX inoculation in subcutaneous tissue, in all four groups, throughout the treatments. C = Control; H = Hyaluronidase; PBM = Photobiomodulation; PBM+H = Photobiomodulation + Hyaluronidase. Botucatu, SP, Brazil, 2019

The animals from Group C presented a higher rate of necrosis on all treatment days, starting on the fourth evaluation day (D4) and extending steadily and progressively throughout the study. The animals from the H, PBM and PBM+H groups also showed necrosis, although more superficial, in lower numbers, and with an improvement in the lesion at the end of the treatment.

Edema was observed in 14 (93%) animals from the Control Group already at the first evaluation day (D2) (Figure 4). A lower number of animals from the PBM group showed edema (4/15: 26%) only at days 20, 22 and 28. On the other hand, the animals from the PBM+H group presented the best conditions in this aspect. Only two animals showed edema on the first two evaluation days, with only one of them maintaining the edema up to D10.

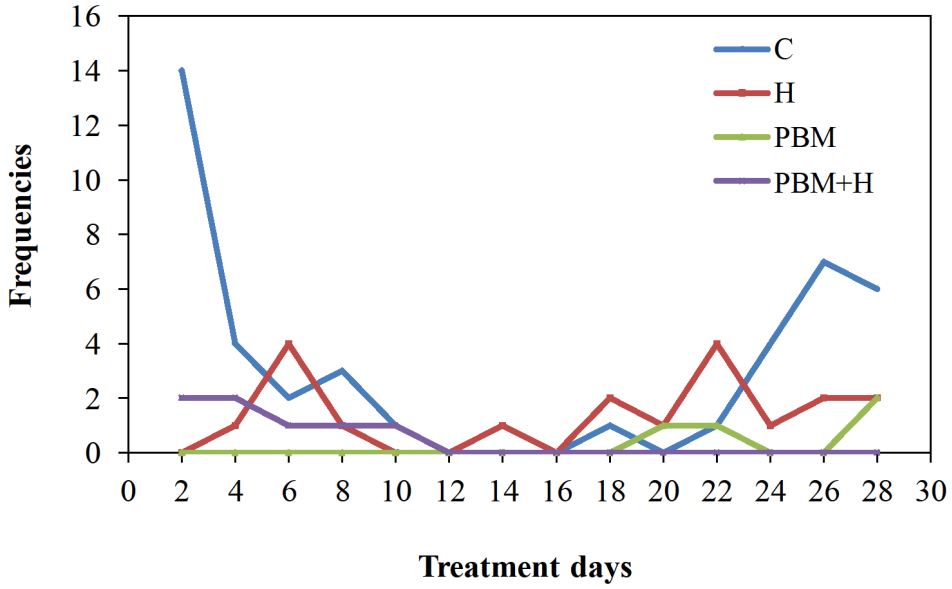

Figure 4 - Frequency of animals with edema after DOX inoculation in subcutaneous tissue, in all four groups and throughout the treatments. C = Control; H = Hyaluronidase; PBM = Photobiomodulation; PBM+H = Photobiomodulation + Hyaluronidase. Botucatu, SP, Brazil, 2019

The healing process with epithelial tissue was observed at D12 with animals from the PBM+H group. It was observed that, after 28 days of evaluation, two animals from the PBM and PBM+H groups showed complete healing of the lesions. At the end of the study, six animals (40%) from the PBM group and two (13%) from the PBM+H presented intact skin (Figure 5).

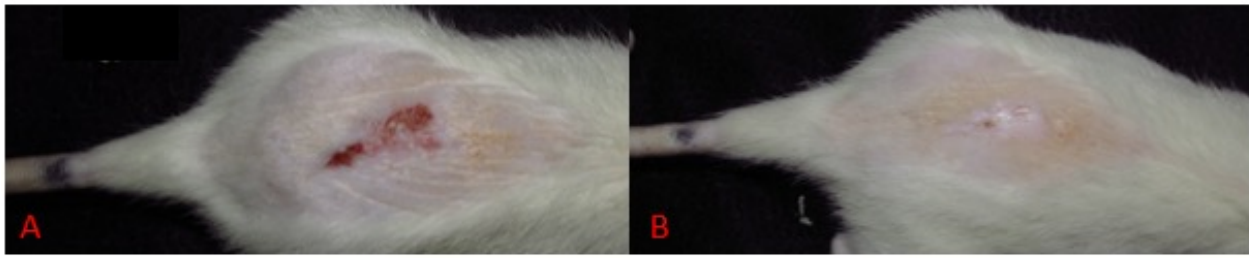

Figure 5 - An animal from the PBM group at two moments: A: Presence of wound at D16; and B: Full healing of the lesion at D28. Botucatu, SP, Brazil, 2019

Discussion

There was premature death of 23 animals, which can be related to several factors, such as the toxicity generated by anthracycline and hyaluronidase and animal behavior. It was observed that the animals that died the most were from the groups that contained hyaluronidase. We infer that even when the ointment is being applied correctly to the back of the animal, due to its significant fluidity, it generated ease of licking and possible intoxication.

Hyaluronidase has been widely used in ophthalmic and dermatological surgeries, as the enzyme degrades the hyaluronic acid matrix, increasing tissue permeability and favoring drug absorption. In addition to that, it is already widely used in EA management, subcutaneously[16]. Although we used a topical presentation in our research, no references to this application route in extravasation were found in the literature, nor on its toxic effects when ingested.

The toxicity generated by anthracycline corresponds to the symptoms observed in the animals, such as diarrhea and weight loss. As it is non-selective, DOX causes various side effects, such as nausea, vomiting, diarrhea and anorexia with consequent weight loss[17]. In addition to these effects, the acute inflammation and oxidative stress caused by DOX can be related to toxicity in multiple organs[18]. We noticed that one animal from the Control Group showed ascites at the end of the study. The autopsy was performed after euthanasia, noticing significant adherence to the liver, spleen, heart and intestines.

Better preservation of skin morphology and reduction of edema and ulcer size were observed in an experimental study with Wistar rats that were administered an intradermal injection of vincristine and were treated with hyaluronidase[6]. This fact corroborates the results found in our study, in which only 2 animals from the PBM+H group presented edema.

PBM also plays an important role in the prevention or reduction of edema during tissue repair processes since, after all, the benefits related to reduction of the edema, oxidative stress and pro-inflammatory cytokines are already well established[19]. This fact is related to a considerable increase in blood flow due to the vasodilating action of nitric oxide (NO); however, at the same time, lymphatic drainage is stimulated, reducing the edema through the control of pro-inflammatory cytokines[20].

During this research, our study group published a retrospective cross-sectional study of the Oncology Outpatient service of a Public Hospital from the inland of the State of São Paulo, Brazil, with the objective of analyzing the effect of PBM and topical hyaluronidase on extravasation and infiltration of antineoplastic drugs in a 21-month period. 8 extravasations (among them 01 of anthracycline) and 7 infiltrations were reported. All were followed-up and received a mean of 2 PBM sessions (1 joule — 100 mw) and topical hyaluronidase (65 UTR) 3 times a day for 4 days. It was found that there was no formation of lesions, even in the patient who used anthracycline[21].

During DOX extravasation, there is cell death in the tissues underlying the extravasation site, with the release of free radicals triggering a marked oxidative stress, increasing the inflammatory process and causing necrosis[22].

From photochemical reactions, PBM restores the cellular function through the release of reactive oxygen species, causing cellular balance restoration by the production of antioxidant enzymes and most importantly, without deleterious effects to the organism[4]. Unlike dexrazoxane, which, despite having a proven efficiency of 98%, also causes some side effects such as nausea, vomiting, mild pain at the infusion site and reversible increases in liver enzymes[1,5,23]. Unfortunately, it is unfeasible for many services due to its high cost.

This is the first paper to investigate the association of PBM with topical hyaluronidase in DOX extravasation. However, the efficacy of PBM has already been proven in other types of lesion, even with the possibility of being associated with topical therapies.

PBM is already quite used to heal wounds of various etiologies. In a study conducted to evaluate the effect of laser therapy at different wavelengths on the expression of growth factors and inflammatory mediators in the healing processes of pressure ulcers, it was observed that the wavelength of 658 nm was more effective. It is believed that this effect is associated with inhibition of the inflammatory processes[24].

In a case study on anthracycline (epirubicin) extravasation in a central venous access (fully implanted catheter) in the right hemithorax, it was observed that the patient showed necrosis in 2/3 of her breast in the first 10 days, lasting for 32 days when she underwent a surgical procedure to dry the necrosis. It is important to report that no antidote was applied to this patient, as 24 hours had already elapsed since extravasation. A skin graft was placed in the site and, after 8 months, the breast reconstruction procedure was performed[25]. A similar result was found in our study regarding the antidote and necrosis formation. In animals that did not receive the antidote, a greater amount of necrosis was observed at all moments evaluated, starting on the fourth evaluation day and extending steadily and progressively throughout the research; differently from what was found with the animals of the groups that used antidotes. All groups showed necrosis, although to a lesser extent and with improvement of the lesion and disappearance of necrosis at the end of the study.

In the study, we found that the granulation tissue was more evident in the animals from the PBM group, with onset of its appearance at D12, maximum peak at D18, stabilization from D20 and a sharp drop at D26, showing replacement of the granulation tissue by gradual epithelization with consequent wound healing of 2 animals from the PBM group and 2 animals from the PBM+H group.

This study provides diverse evidence for using PBM associated with hyaluronidase in DOX extravasation, providing important and relevant information for the formulation of protocols by Oncology professionals. It

has sufficient clinical relevance for the possibility of incorporating new technologies by the Unified Health System (*Sistema Único de Saúde*, SUS).

Study limitations

We consider the loss of some animals from the groups in use of hyaluronidase as a limitation of this study, which may have been due to toxicity.

Another limiting factor is the non-existence of literature on photobiomodulation in anthracycline extravasation. We suggest that this technique be encouraged in several Health Institutions and that case reports be published in order to increase the evidence, as it would not be feasible to carry out experimental or clinical studies with extravasations in humans.

Advances for the Nursing/Health areas

This research can be considered the initial milestone in the use of photobiomodulation in anthracycline extravasation, ensuring professional autonomy for nurses in the prevention and treatment of such an important adverse event.

New technologies should be incorporated in order to ensure better care for cancer patients.

Conclusion

The results evidenced that the association of PBM (660 nm - 1 J) with topical hyaluronidase (65 UTR) on DOX extravasation was effective in reducing the local effects and assisted in the wound healing process, as well as that PBM alone was able to prevent the appearance of lesions. This therapy is a good alternative to treat extravasation, with the possibility of being incorporated into the clinical practice.

Acknowledgments

We thank Talita Oliveira de Lima, Alessandra Passarelli Vigliassi and Dayane Oliveira Borges for their collaboration in the data collection phase.

References

1. Melo JMA, Oliveira PP, Rodrigues AB, Souza RS, Fonseca DF, Gontijo TF, et al. Bundle construction and assessment before antineoplastic extravasation: a methodological study. Acta Paulista Enferm [Internet]. 2020 [cited 2021 Aug 28];33:eAPE20190075. Available from: https://acta-ape.org/wp-content/uploads/articles_xml/1982-0194-ape-33-eAPE20190075/1982-0194-ape-33-eAPE20190075-en.pdf

2. Melo JMA, Oliveira PP, Souza RS, Fonseca DF, Gontijo TF, Rodrigues AB. Prevention and conduct against the Extravasation of antineoplastic chemotherapy: a scoping review. Rev Bras Enferm [Internet]. 2020 [cited 2021 Aug 28];73(4):e20190008. Available from: https://www.scielo.br/pdf/reben/v73n4/0034-7167-reben-73-04-e20190008.pdf

3. Miura NO, Aung NY, Yamakawa M. Effect of cold and hot compress on neutrophilic migration to the site of doxorubicin extravasation. Int J Clin Exp Pathol [Internet]. 2019 [cited 2021 Sep 02];12(4):1468-77. Available from: https://www.ncbi.nlm.nih.gov/pmc/articles/PMC6947076/pdf/ijcep0012-1468.pdf

4. Koleini N, Kardami E. Autophagy and mitophagy in the context of doxorubicin-induced cardiotoxicity. Oncotarget [Internet]. 2017 [cited 2021 Jan 17];8(28):46663-80. Available from: https://www.ncbi.nlm.nih.gov/pmc/articles/PMC5542301/pdf/oncotarget-08-46663.pdf

5. Romero AS, Ureña MTD, García AS, Fernández MTM, Porriño-Bustamante ML, Barrera JC. Extravasation accidents with liposomal/liposomal pegylated anthracyclines treated with dexrazoxane: an overview and outcomes. Anti-Cancer Drugs [Internet]. 2018 [cited 2020 Feb 29];29:821-6. Available from: https://journals.lww.com/anti-cancerdrugs/Fulltext/2018/10000/Extravasation_accidents_with_liposomal_liposomal.1.aspx

6. Kesik V, Kurt B, Tunc T, Karslioglu Y, Citak EC, Kismet E, et al. Melatonin ameliorates doxorubicin-induced skin necrosis in rats. Ann Plast Surg [Internet]. 2010 [cited 2021 Feb 27];65(2):250-3. Available from: https://journals.lww.com/annalsplasticsurgery/Fulltext/2010/08000/Melatonin_Ameliorates_Doxorubicin_induced_Skin.29.aspx?casa_token=Yp6UqoQ8ucEAAAAA:Bci7fwuxRx-9z1ykYuhXYx3JKFs9pW3RyLBcAT9pAjP0lgl_6HNveCevLmogP5cq_92Ru6rl_tuVwCLM3jZr4xQuC0l3GZg

7. Schulmeister L. Extravasation management: clinical update. Semin Oncol Nurs [Internet]. 2011 [cited 2021 Nov 20];27(1):82-90. Available from: https://www.sciencedirect.com/science/article/pii/S0749208110000926/pdfft?md5=d701d28d9d89aa4f230083f65ec93a0d&pid=1-s2.0-S0749208110000926-main.pdf

8. Kim JT, Park JY, Lee HJ, Cheon YJ. Guidelines for the management of extravasation. J. Educ Eval Health Prof [Internet]. 2020 [cited 2021 Aug 12];17(21). Available from: https://doi.org/10.3352/jeehp.2020.17.21

9. Doellman D, Hadaway L, Bowe-Geddes LA, Franklin M, LeDonne J, Papke-O'Donnell L, et al. Infiltration and extravasation: update on prevention and management. J Infus Nurs [Internet]. 2009 [cited 2021 Nov 17];32(4):203-11. Available from: https://journals.lww.com/journalofinfusionnursing/Fulltext/2009/07000/Infiltration_and_Extravasation__Update_on.10.aspx

10. Hamblin MR. Mechanisms and applications of the anti-inflammatory effects of photobiomodulation. AIMS

Biophys [Internet]. 2017 [cited 2021 Feb 08];4(3):337-61. Available from: https://pubmed.ncbi.nlm.nih.gov/28748217/

11. Dompe C, Moncrieff L, Matys J, Grzech-Leśniak K, Kocherova I5, Bryja A, et al. Photobiomodulation - Underlying Mechanism and Clinical Applications. J Clin Med [Internet]. 2020 [cited 2021 Jan 17];9(6):1724. Available from: https://www.mdpi.com/2077-0383/9/6/1724/pdf?version=1591187098

12. George S, Hamblin MR, Abrahamse H. Effect of red light and near infrared laser on the generation of reactive oxygen species in primary dermal fibroblasts. J Photochem Photobiol B [Internet]. 2018 [cited 2021 Jan 07];188:60-8. Available from: https://www.ncbi.nlm.nih.gov/pmc/articles/PMC6214457/

13. Mosca RC, Ong AA, Albasha O, Bass K, Arany P. Photobiomodulation Therapy for Wound Care: A Potent, Noninvasive, Photoceutical Approach. Adv Skin Wound Care [Internet]. 2019 [cited 2021 Jan 07];32(4):157-67. Available from: https://journals.lww.com/aswcjournal/Fulltext/2019/04000/Photobiomodulation_Therapy_for_Wound_Care__A.3.aspx

14. Munnangi S, Boktor SW. Epidemiology Of Study Design. StatPearls [Internet]. 2021 [cited 2021 Sep 13]. Available from: https://www.ncbi.nlm.nih.gov/books/NBK470342/

15. Valente FS. Terapia tópica na cicatrização de lesões cutâneas provocadas por congelamento com nitrogênio líquido em ratos Wistar [Master's thesis]. Porto Alegre: Faculdade de Veterinária, Universidade Federal de Porto Alegre; 2014. Available from: https://www.lume.ufrgs.br/bitstream/handle/10183/95142/000917868.pdf?sequence=1

16. Kreidieh FY, Moukadem HA, El Saghir NS. Overview, prevention and management of chemotherapy extravasation. World J Clin Oncol [Internet]. 2016 [cited 2021 Sep 10];7(1):87-97. Available from: https://www.ncbi.nlm.nih.gov/pmc/articles/PMC4734939/pdf/WJCO-7-87.pdf

17. Jamali J, Dayo A, Adeel A, Qureshi Y, Khan T, Begum S. A survey on gastrointestinal adverse drug reactions of Doxorubicin and Cyclophosphamide combination therapy. J Pak Med Assoc [Internet]. 2018 [cited 2021 Feb 08];68(6). Available from: https://jpma.org.pk/PdfDownload/8730

18. Pugazhendhi A, Edison TNJI, Velmurigan BK, Jacob JA, Karuppusamy I. Toxicity of Doxorubicin (Dox) to different experimental organ systems. Life Sciences 200 [Internet]. 2018 [cited 2020 Nov 08];200:26-30. Available from: https://linkinghub.elsevier.com/retrieve/pii/S0024-3205(18)30130-9

19. Hamblin MR. Mechanisms and Mitochondrial Redox Signaling in Photobiomodulation. Photochem Photobiol [Internet]. 2018 [cited 2021 Jan 15];94(2):199-212. Available from: https://www.ncbi.nlm.nih.gov/pmc/articles/PMC5844808/

20. Hamblim MR. Photobiomodulation for traumatic brain injury and stroke. J Neurosci Res [Internet]. 2018 [cited 2021 Jan 08];96(4):731-43. Available from: https://www.ncbi.nlm.nih.gov/pmc/articles/pmid/29131369/

21. Freitas KABS, Lima TO, Minicucci EM, Silva KAB, Vigliassi AP, Popim RC. Association of photobiomodulation and topical hyaluronidase in extravasation and infiltration of antineoplastics. Retrospective study. Nursing [Internet]. 2020 [cited 2021 Jun 19];23(271):4971-8. Available from: http://revistas.mpmcomunicacao.com.br/index.php/revistanursing/article/view/1045

22. Koleini N, Nickel BE, Edel AL, Fandrich RR, Ravandi A, Kardami E. Oxidized phospholipids in Doxorubicin-induced cardiotoxicity. Chem Biol Interact [Internet]. 2019 [cited 2021 Jun 25];303:35-9. Available from: https://www.sciencedirect.com/science/article/pii/S000927971831603X?casa_token=hO_oPK1H8ZIAAAAA:HGiDUT5vaYCbOyRKNPgstPqCQv7-pB8_bh4FCktF_KgknJdBKASWIoySQ2VoHGNg7a4StWWJinPy

23. Eneh C, Lekkala MR. Dexrazoxane. StatPearls [Internet]. 2021 [cited 2021 Aug 12]. Available from: https://www.ncbi.nlm.nih.gov/books/NBK560559/

24. Taradaj J, Shay B, Dymarek R, Sopel M, Walewicz K, Beeckman D, et al. Effect of laser therapy on expression of angio- and fibrogenic factors, and cytokine concentrations during the healing process of human pressure ulcers. Int J Med Sci [Internet]. 2018 [cited 2021 Jan 15];15(11):1105-12. Available from: https://www.ncbi.nlm.nih.gov/pmc/articles/PMC6097266/

25. Vasconcelos I, Schoenegg W. Massive breast necrosis after extravasation of a full anthracycline cycle. BMJ Case Rep [Internet]. 2013 [cited 2021 Feb 28];bcr2013201179. Available from: https://www.ncbi.nlm.nih.gov/pmc/articles/PMC3822217/

Authors' contribution

Study concept and design: Karina Alexandra Batista da Silva Freitas, Eliana Maria Minicucci, Hélio Langoni, Regina Célia Popim. **Obtaining data:** Karina Alexandra Batista da Silva Freitas, Eliana Maria Minicucci, Valéria Flávia Batista da Silva, Benedito Donizete Menozzi, Hélio Langoni, Regina Célia Popim. **Data analysis and interpretation:** Karina Alexandra Batista da Silva Freitas, Eliana Maria Minicucci, Valéria Flávia Batista da Silva, Benedito Donizete Menozzi, Hélio Langoni, Regina Célia Popim. **Statistical analysis:** Karina Alexandra Batista da Silva Freitas, Valéria Flávia Batista da Silva. **Drafting the manuscript:** Karina Alexandra Batista da Silva Freitas, Eliana Maria Minicucci, Valéria Flávia Batista da

Silva, Benedito Donizete Menozzi, Regina Célia Popim. **Critical review of the manuscript as to its relevant intellectual content:** Karina Alexandra Batista da Silva Freitas, Eliana Maria Minicucci, Valéria Flávia Batista da Silva, Benedito Donizete Menozzi, Hélio Langoni, Regina Célia Popim. **Others (Development of the experimental part of the laboratory research):** Karina Alexandra Batista da Silva Freitas, Benedito Donizete Menozzi, Hélio Langoni.

All authors approved the final version of the text.

Conflict of interest: the authors have declared that there is no conflict of interest.

Received: October 18th 2021
Accepted: June 17th 2022

Associate Editor:
Evelin Capellari Cárnio

Copyright © 2022 Revista Latino-Americana de Enfermagem
This is an Open Access article distributed under the terms of the Creative Commons (CC BY).
This license lets others distribute, remix, tweak, and build upon your work, even commercially, as long as they credit you for the original creation. This is the most accommodating of licenses offered. Recommended for maximum dissemination and use of licensed materials.

Corresponding author:
Karina Alexandra Batista da Silva Freitas
E-mail: k.freitas@unesp.br
https://orcid.org/0000-0001-3413-8468