

Mohs micrographic surgery in the treatment of non-melanocytic skin neoplasms – a systematic review

João Augusto Gomes de Souza Monteiro de Brito¹ , Lucas da Silva Lopes¹ , Ana Luísa Gross Rodrigues¹ , Caio Vinicius Botelho Brito¹ 

ABSTRACT

Objective: Evaluating the effectiveness of using MOHS surgery in the management of non-melanoma skin tumors compared to other therapy methods. **Methods:** The study consists of a systematic review, whose search for articles was performed using databases *MEDLINE*, *PubMed Central (PMC)*, *LILACS* and *SciELO*, using the terms “MOHS surgery”, “Skin cancer”, “Clinical trial”, excluding “melanoma”. **Results:** from a total of 132 identified articles, 11 were considered eligible. The analysis of the articles showed that MMS, compared to other methods, presented better cosmetic results, in addition to a lower grade of complications in recurrent tumors and a variable cost/benefit according to the country where the surgery was performed. MMS also had lower recurrence rates in all studies. **Conclusion:** Overall, MOHS surgery has shown promising therapeutic results. However, there are still few comparative studies on the effectiveness of MMS and those that exist are concentrated in a few regions of the world.

Keywords: Mohs surgery, Skin neoplasms, Systematic review.

1. Universidade do Estado do Pará. Curso de Medicina. Belém (PA), Brasil.



INTRODUCTION

Mohs micrographic surgery (MMS) is a systematic and innovative procedure, known to be one of the most effective ways to treat various malignant skin neoplasms, for offering higher cure rates and greater conservation of healthy tissue compared to other methods. It is a technique developed by Dr. Frederic Mohs in the 1930s with the guiding principle of microscopically controlled excisions.¹

In this technique, the tumor is extracted, precisely mapped and processed into horizontal fragments frozen for intraoperative histological evaluation. The process is repeated with the tumor surgically removed, layer by layer, and each layer is examined microscopically. Removal continues until there are no abnormal cells, allowing complete tumor removal and maximum conservation of healthy tissue. Immediate margin assessment leads to higher cure rates and its use is often part of a multidisciplinary approach to treating skin tumors.^{2,3}

In this context, surgical treatment is the basis of therapy for many skin tumors. Basal cell carcinomas (BCC) comprise most of these and have a slow and indolent clinical course with a low risk of metastasis. However, they can be locally invasive, causing extensive tissue destruction. Thus, Mohs micrographic surgery is the treatment of choice for high-risk tumors, in places where tissue conservation is of extreme importance⁴, in addition to studies reporting a lower recurrence rate when compared to conventional surgical excision. Mohs micrographic surgery is the treatment of choice for high-risk tumors, in places where tissue conservation is of paramount importance⁴, and studies report a lower recurrence rate when compared to conventional surgical excision.⁵

Just like basal cell carcinomas, studies have shown that patients with other aggressive or high-risk non-melanoma skin tumors also benefit from methods such as MMS or other margin-controlled surgeries that decrease recurrence rates, have high cure rates and better cosmetic results, with greater tissue preservation, recommending its use in the treatment of lesions, especially in the H zone of the face and in aggressive histological subtype tumors^{6,7,8}

The study by Reeder et al. (2015)⁹ observed an increase in the use of Mohs surgery in the treatment of skin cancer between 1995 and 2010. Despite this, the overall rate of use of this procedure remains low compared to the conventional method.

In addition to surgical methods of treatment, less invasive targeted therapies are under active study and may eventually replace some conventional surgical therapies in the near future, diversifying ways to manage non-melanoma skin tumors¹⁰

Therefore, the current research aims to provide the scientific community and healthcare professionals with knowledge about the advantages and importance of using the Mohs micrographic surgical technique to treat non-melanocytic skin tumors, based on the most reliable evidence available in the medical literature on the subject. Then, through systematic review, this study aims to synthesize and investigate the effectiveness of using Mohs micrographic surgery in non-melanocytic skin tumors compared to other treatment methods.

METHODS

This is a systematic literature review. A search was carried out in electronic databases following the recommendations of the *Preferred Reporting Items for Systematic Reviews e Meta-Analyses (PRISMA)*¹¹.

The collection of articles was performed through a search in electronic databases *MEDLINE*, *PubMed Central (PMC)*, *LILACS*, and *SciELO*.

The descriptors used were "MOHS surgery", "Skin cancer" and "Clinical trial" and their synonyms in Portuguese, English and Spanish, excluding "melanoma" and its synonyms.

The search process was carried out independently and isolated by each of the authors. First, the totality of articles identified in the PUBMED, Virtual Health Library (VHL) and the SciELO database search systems were surveyed and organized in tables in Microsoft Excel 2016 with subsequent elimination of duplicate articles. The titles and abstracts of the articles found were then read to verify eligibility for this study. After excluding articles that were not compatible, the full reading was performed for another verification of eligibility. Subsequently, the information found was crossed between the authors and the differences in the results obtained were verified, in order to reduce possible failures in searches in databases. Finally, the data were primarily synthesized qualitatively.

Articles from primary studies that compared Mohs micrographic surgery with other forms of treatment as a therapeutic form for non-melanoma skin tumors were selected, with abstracts available in selected computerized databases and text available

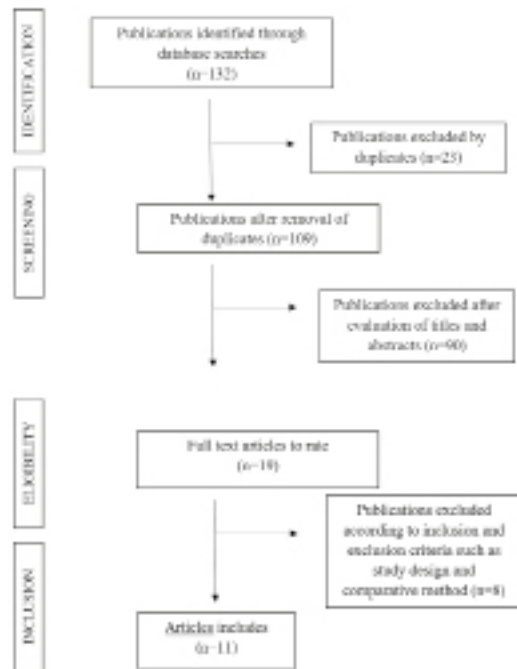
in full on the internet or provided by the original source. Also was considered articles published from 1995 to 2019.

It was excluded articles that studied melanoma, that did not have clear methodology or results, that did not use a method of comparison between treatments and that complete data were not found.

A comprehensive qualitative review of the selected studies was carried out. Information was extracted on the effectiveness of the treatment methods, level of recurrence of tumors after surgery, aesthetic and quality of life results, cost/benefit and complications. After that, graphs and tables were prepared to display the results.

As shown in **Figure 1**, 132 potential citations were found. After the first reading, where duplicate studies were excluded (23), 90 were removed while evaluating titles and abstracts. Among the 19 selected, 8 articles were excluded during the application of the inclusion and exclusion criteria.

Figure 1 Article selection flowchart.



Adapted from PRISMA (Preferred Reporting Items for Systematic Reviews and Meta-analysis; <http://www.prisma-statement.org/index.html>).

Of the 11 articles included, 10 originate from the MEDLINE database and 1 from the PMC. Articles from other databases were not eligible for the study.

RESULTS

The **Table 1** summarizes the characteristics of the original articles that make up the sample and **Table 2** describes methodological procedures and main results.

The study included 11 articles, most of which are case-control studies and randomized clinical trials. In total, data from 3,095 patients were included in the review. The works that made up the study came from countries: the United States of America (USA), the United Kingdom and the Netherlands. Not one work from the LILACS and SciELO databases was eligible for the study.

The study had a higher percentage of patients with lesions in the head and neck and histological type Basal Cell Carcinoma. Nine of the eleven articles sought to compare conventional surgical excision with the Mohs micrographic method.

DISCUSSION

Considering basal cell carcinoma, all articles evaluated had lower recurrence rates after Mohs micrographic surgery compared to other treatments.^{12,13,14} However, none of them were statistically significant, which may be due to the fact that not one of the studies had a follow-up period of at least 5 years for evaluation, as pointed out by Smeets et al(2004).¹⁴

Davis et al. (1997)¹⁵ showed that the treatment of atypical fibroxanthoma with MMS resulted in a lower recurrence rate and metastasis and greater conservation of healthy tissue than with wide excision. This result is similar to that found in a meta-analysis carried out with 907 patients in 23 studies showing a recurrence rate after Mohs surgery and wide local excision (WLE) of 2% and 8.7%, respectively. Careful and complete control of the margin through the MMS likely contributes to best results, particularly in immunocompromised patients who appear to be at higher risk of recurrence.¹⁶

Regarding dermatofibrosarcoma protuberans (DFSP) treatment, DuBay et al (2004)¹⁷ observed that both wide local excision and MMS seem to be effective and with high rates of complete cure. On the other hand, another study observed DFSP recurrence rates of 9.10% and 2.72% after wide local excision and MMS, respectively, during a mean follow-up time of 5.32 years. This result may have been due to the

fact that the surgery service in the DuBay study used a method different from the standard shown in the literature, with extensive local excision in the shape

Regarding the assessment of life quality in patients, Essers et al. (2006)¹³ observed no statistically significant difference in the level of anxiety symptoms and good quality of life 6 months after surgery

Table 1 Description of included studies.

Quotation	Kind of study	Local	Year	Sample
Davis et al	Case-control	USA	1997	116 patients
Boyer et al	Case-control	USA	2002	45 patients
Dubay et al	Case-control	USA	2004	62 patients
Essers et al	Randomized clinical trial Prospective	Netherlands	2006	565 patients
Wain et al	Case-control	United Kingdom	2015	157 patients
Patel et al	Prospective cohort with retrospective phase	USA	2017	369 patients
Muller et al	Randomized clinical trial double blind	United Kingdom	2009	30 patients
Chren et al	Prospective cohort study	USA	2007	633 patients
Smeets et al	Randomized clinical trial	Netherlands	2004	374 patients with 408 primary neoplasms
Cook et al	Case-control	USA	1998	400 tumors
Ravitskiy et al	Case-control	USA	2012	344 patients and 406 tumors

Source: own author

of a diamond and with a complete assessment of the peripheral margin.

Boyer et al (2002)¹⁸. also observed a low recurrence rate (about 4%) after excision of Merkel cell carcinoma by the MMS, without the need for complementary treatments, such as adjuvant radiation, to control lesions.

Wain et al (2015)¹⁹ evaluated the reconstructive techniques used after Mohs surgery compared to conventional surgical excision (CSE), showing that if CSE had been used, 56% of patients would have received a more invasive or less aesthetically desirable reconstruction and 24% of the margins would remain affected. On top of that, 80% of the patients who underwent MMS and subsequent reconstruction improved compared with CSE and its associated reconstruction. Similar results were found by Smeets et al (2004)¹⁴ and Dubay (2004)¹⁷, who showed a larger mean defect size after CSE compared to MMS for recurrent and more aggressive tumors. However, there was no significant statistical difference to primary carcinomas. In this sense, MMS would be preferable for aggressive tumors to avoid major defects, poor cosmetic results, and functional problems.

comparing patients that underwent MMS or CSE. Similar results were found by another study²⁰, which identified that patients treated with CSE or Mohs surgery had similar but better quality of life results than those obtained after electrodissection and curettage. However, NHP and STAI protocols used by Essers et al¹³ may not be sensitive enough to detect all effects and differences of those treatments in patients' lives.

As for the degree of spared tissue, Muller et al. (2009)²¹ found that the area of tissue removed in conventional surgical excision is 1.6 times larger than after Mohs micrographic surgery, something that conflicts with what was found by Smeets et al. (2004)¹⁴, where no significant differences were observed. However, this fact can be explained by the fact that in the work of Smeets et al., 3 mm margins were used in both therapeutic methods, and usually MMS uses much smaller margins, something pointed out in the 2 articles, while in the work of Muller et al.²¹ margins of 2 mm for MMS and 4 mm for CSE were adopted. Still, in cases where more than one ECC or more than one MMS stage was needed, the MMS was shown to spare much more tissue.

Regarding the isolated cost of MMS, there is a consensus that it is higher than that of CSE,

Table 2 Description of the methodological aspects and main outcomes of the studies included in this review.

Quotation	Intervention	Histologic type	Local lesion	Main results / conclusions
Davis et al	MMS and CSE	Atypical fibroxanthoma	78% in head and neck	<p>There were no relapses in patients with MMS at 26.6 months.</p> <p>3 patients undergoing CSE had recurrence. Microscopic control of surgical margins with MMS results in a lower rate of recurrence and metastasis than with CSE and preserves normal tissue.</p> <p>In the group submitted, only MMS had 1 marginal recurrence and 3 metastases.</p>
Boyer et al	MMS only and radiation + MMS	Merkel cell carcinoma	Most common head and neck	<p>In the group submitted to the 2 interventions, 0 recurrence or metastasis. Treatments did not differ significantly for overall and patient-specific survival</p> <p>The 4% recurrence rate validates Mohs surgery alone as an effective treatment.</p>
Dubay et al	CSE, MMS and combined approach: surgical oncology, MMS, plastic surgery, facial plastic surgery, ophthalmology, ortho-maxillo-facial surgery and radiation oncology.	Protuberant dermatofibrosarcoma	Trunk and ends (48) and face (15)	<p>Lesions treated by MMS are smaller compared to those treated with a multidisciplinary approach or large excision</p> <p>The postoperative MMS defect was smaller compared to defects after a combined multidisciplinary approach or wide excision.</p> <p>All treatment modalities, selected by tumor and patient factors, were able to achieve very high local control rates.</p>
Essers et al	CSE and MMS	BCC	Head in all cases	<p>Primary group: 5 recurrences after CSE and 3 after MMS within 30 months.</p> <p>Recurrent group: 3 recurrences after surgical excision and none for MMS.</p> <p>MMS 's costs were higher.</p> <p>Acceptability curves for primary and recurrent BCC demonstrated that the probability of MMS being more cost-effective and surgical excision did not reach 50% and the cost-benefit ratio is still too high to recommend wide implementation.</p>
Wain et al	CSE and MMS	BCC and SCC	Nasal region in 48% of cases	<p>CSE: 24% would have had an incomplete histological margin and 9% would have needlessly lost fundamental structures.</p> <p>80% of those submitted to MMS had better results compared to CSE</p> <p>Detailed reference criteria, complete preoperative period, patient assessment, assessment of CSE abilities and limits allowed the service to produce a demonstrable surgical benefit in at least 80% of patients undergoing MMS when compared to CSE.</p> <p>Comparing MMS and CSE provides a method to assess the efficiency and effectiveness of the MMS service</p>

continued...

...Continuation

Patel et al	MMS and EB	BC C and SCC	X	99.5% of EB and 100.0% of lesions treated with MMS were free from recurrence. Aesthetic results: "excellent" or "good" in 97.6% of lesions treated with EB and 95.7% of lesions treated with MMC. EB is an effective non-surgical treatment option for early-grade nonmelanoma skin cancer.
Muller et al	CSE and MMS	BCC	Head and neck (12)	The mean area of surgical defects in the CMM group was 116.6 mm ² against 187.7 mm ² in the ECC group, so that the area affected by standard surgery is 1.6 times larger than with CMM.
Chren et al	CSE, MMS and electrodissection + curettage.	BCC and SCC	X	Those treated with CSE or MMS showed statistically significant improvements in the three domains of quality of life Patients treated with electrodissection and curettage showed no changes in tumor-related quality of life Skindex mean symptom scores improved by 9.7 (95% CI: 6.9, 12.5) after excision, 10.2 (7.4, 12.9) after Mohs surgery, and 3.4 (± 0.9, 7.6) after electrodissection + curettage.
Smeets et al	CSE and MMS	BCC	All in the head	Primary carcinomas: 3% recurred after CSE and 2% after MMS. Recurrent carcinomas: 3% recurrence after CSE and 0 after MMS. The total operating costs of MMS were higher than those of CSE. No definitive conclusions about the recurrence rates of primary or recurrent CSE are yet possible.
Cook et al	MMS x traditional excision methods: permanent section margin excision, frozen section margin excision control	BCC and SCC	Head and neck (346) Extremities and external genitalia (22)	Mohs is a surgical excision method with high economic systemic value compared to traditional surgical excision
Ravitskiy et al	MMS x CSE with margin control	BCC and SCC	Head (275) Trunk and end (79)	MMS was the cheapest per tumor. This study confirms MMS as the cornerstone of cost-effective treatment, regardless of service location or type of pathology.

Source: own author

MMS: Mohs Micrographic Surgery; CSE: Conventional Surgical Excision; EB: Electronic Brachytherapy; BCC = Basal Cell Carcinoma; SCC = Squamous Cell Carcinoma.

mainly because MMS requires a longer surgery time and has costs with wanalysis.^{13,14,22} However, when considering the cost/benefit in different situations, there is a divergence. Essers et al(2006)¹³ found that in neither situation does MMS have a better cost/benefit ratio considering both primary and recurrent BCC for large-scale implementation, but that larger studies could eventually show better cost/benefit for recurrent cases and for specific locations such as ears. Cook et al (1998)²³ and Ravitskiy et al(2012)²²,

on the other hand, observed that, even with high cost, MMS has a better cost/benefit ratio than CSE. One possibility for the significant difference between the results may arise from the reality in which the studies were inserted, as the study by Essers took place in the Netherlands, while the one by Cook²³ and the one by Ravitskiy²² took place in the United States of America.

The results about complications occurred similarly between the studies. Comparing MMS to CSE

,Smeets et al(2004)¹⁴ andEssers et al(2006)¹³ showed no significant difference between complication rates regarding primary BCC. However, for recurrent BCC, both studies found complication rates of 19% for CSEand 8% for MMS, showing the superiority of MMS for these situations. Compared to electronic brachytherapy (EB), although MMS had a lower rate in almost all types of complications evaluated, both methods showed similar results with low rates, except for telangiectasias, which were much more common in EB (31.4%) than than after CMM (11.1%).

CONCLUSION

The Mohs micrographic surgery is a therapeutic method of proven efficacy for nonmelanoma skin cancer with low recurrence rates, excellent cosmetic results, and low complication rates when compared to other treatments, as observed. However, comparative studies regarding the effectiveness of MMS are still scarce and those that exist are concentrated in few regions of the world. Therefore, more studies are needed to confirm Mohs micrographic surgery as a treatment superior to conventional surgical excision considering nonmelanoma skin cancer.

REFERENCES

- Ladda MA, Lynde CW. Mohs Micrographic Surgery: Development of the Technique. *J cutan medic surger*. 2019; 23(2): 236.
- Wong E, Axibal E, Brown M. Mohs Micrographic Surgery. *Facial Plast Surg Clin North Am*. 2019; 27(1): 15-34.
- Van loo E, Mosterd K, Krekels GA, Roozeboom MH, Ostertag JU, Dirksen CD, et al. Surgical excision versus Mohs' micrographic surgery for basal cell carcinoma of the face: a randomised clinical trial with 10 year followup. *Eur J Cancer*. 2014; 50(17): 3011-20.
- Kauvar AN, Cronin JRT, Roenigk R, Hruza G, Bennett R. Consensus for nonmelanoma skin cancer treatment: basal cell carcinoma, including a cost analysis of treatment methods. *Dermatol Surg*. 2015; 41(5): 550-71.
- Tanese K. Diagnosis and Management of Basal Cell Carcinoma. *Curr Opin Oncol*. 2019; 20(2): 1-13.
- Murray C, Silva JD, Hanna TP, Bradshaw S, Solish N, Moran B, et al. Patient indications for Mohs micrographic surgery: a clinical practice guideline. *Curr Opin Oncol*. 2019; 26(1): 94-99.
- Sanchez FH, Estefan JL, Estefan LL. Cirurgia micrográfica de Mohs: estudo de 93 tumores operados em um centro de referência no Rio de Janeiro. *Surg Cosm Derm*. 2013; 5(3): 206-10.
- Pontes LT. Cirurgia micrográfica de Mohs em um serviço universitário: estudo retrospectivo de 5 anos [dissertação]. Campinas: Universidade Estadual de Campinas, Faculdade de Ciências Médicas; 2016.
- Reeder VJ, Gustafson C J, Mireku K, Davis SA, Feldman SR, Pearce DJ. Trends in Mohs surgery from 1995 to 2010: an analysis of nationally representative data. *Derm Surg*. 2015; 41(3): 397-403
- Correia STR, Silva R, Lopes JM. Carcinoma basocelular da pele (parte 2): diagnóstico, prognóstico e manejo. *Future Oncology*. 2015; 11(22): 3023-38.
- Moher D, Liberati A, Tetzlaff J, Altman DG, PRISMA Group. Itens de relatório preferidos para revisões sistemáticas e metanálises: a declaração PRISMA. *PLoS Med*. 2009; 6(7): e1000097.
- Patel R, Strimling R, Doggett S, Willoughby M, Miller K, Dardick L, et al. Comparison of electronic brachytherapy and Mohs micrographic surgery for the treatment of early-stage non-melanoma skin cancer: a matched pair cohort study. *J Contemp Brachytherapy*. 2017; 9(4): 338-44.
- Essers BAB, Dirksen CD, Nieman FHM, Smeets NWJ, Krekels GAM, Prins MH, et al. Cost-effectiveness of Mohs Micrographic Surgery vs Surgical Excision for Basal Cell Carcinoma of the Face. *Arch Dermatol*. 2006; 142(2): 187-94.
- Smeets NWJ, Krekels GAM, Ostertag JU, Essers BAB, Dirksen CD, Nieman FHM, et al. Surgical excision vs Mohs' micrographic surgery for basal-cell carcinoma of the face: randomised controlled trial. *Lancet*. 2004; 364(9447): 1766-72.
- Davis JL, Randle HW, Zalla MJ, Roenigk RK, Brodland DG. A comparison of Mohs Micrografic Surgery and wide excision for the treatment of atypical fibroxantoma. *Dermatol Surg*. 1997; 23(2): 105-10.
- Tolkachjov SN, Kelley BF, Alahdab F, Erwin PJ, Brewer JD. Atypical fibroxanthoma: Systematic review and meta-analysis of treatment with Mohs micrographic surgery or excision. *J Am Acad Dermatol*. 2008; 79(5): 929-34.
- Dubay D, Cimmino V, Lowe L, Johnson TM, Sondak VK. Low Recurrence Rate after Surgery for Dermatofibrosarcoma Protuberans: a multidisciplinary approach from a single institution. *Cancer*. 2004; 100(5): 1008-16.
- Boyer JD, Zitelli JA, Brodland DG, D' Angelo G. Local control of primary Merkel cell carcinoma: Review of 45 cases treated with Mohs micrographic surgery with and without adjuvant radiation. *J Am Acad Dermatol*. 2002; 47(6): 885-92.
- Wain RAJ, Tehrani H. Reconstructive outcomes of Mohs surgery compared with conventional excision: A 13-month prospective study. *Journal of Plastic, Reconstructive & Aesthetic Surgery*. 2015; 68(7): 946-52

20. Chren MM, Sahay AP, Bertenthal DS, Sen S, Landerfeld CS. Quality of Life Outcomes of Treatments for Cutaneous Basal Cell Carcinoma and Squamous Cell Carcinoma. *Journal of Investig Dermatol.* 2007; 127(6): 1351-57.
21. Muller FM, Dawe RS, Moseley H, Fleming CJ. Randomized Comparison of Mohs Micrographic Surgery and Surgical Excision for Small Nodular Basal Cell Carcinoma: Tissue-Sparing Outcome. *Dermatol Surg.* 2009; 35(9): 1349-54.

Corresponding Author:

João Augusto Gomes de Souza Monteiro de Brito
joaoaugustobrito@hotmail.com

Editor:

Prof. Dr. Paulo Henrique Manso

Received in: jun 01, 2020

Approved in: apr 14, 2021
