

Implant-supported Dental Prosthesis and Orthognathic Surgery for Rehabilitation of Patients with Obstructive Sleep Apnea

Prótese Dentária Implanto-suportada e Cirurgia Ortognática para Reabilitação de Pacientes com Apneia Obstrutiva do Sono

Sandro Isaías Santana¹, Breno de Souza Pedro Santana², Flaviana Soares Rocha³, Átila Roberto Rodrigues¹

ABSTRACT

Among the treatment options for Obstructive Sleep Apnea (OSA) we have surgery to correct dentofacial deformities. OSA patients are routinely and predictably submitted to surgical treatment for dentofacial deformities. Frequently, orthognathic surgery and osseointegrated implants may be necessary to enable fixed rehabilitation. Patients submitted to orthognathic surgery have a transient decrease in blood supply after maxillary and mandibular osteotomy procedures, which can impair the results in these cases. This case report aimed to present and discuss the conflicting situation of an OSA patient in need of orthognathic surgery and dental implants. The treatment consisted of: (1) extraction of all teeth; (2) complete rehabilitation of the upper and lower jaw with dental implants and prosthesis without compensation; (3) bimaxillary orthognathic surgery to re-establish the maxillomandibular relationship and increase the upper airway volume. This rehabilitation sequence was a safe alternative for a case of Class II OSA, and rapidly achieved a final restoration with enhanced esthetics, functionality, biomechanics, maintenance of oral hygiene, and patient satisfaction.

Keywords: Orthognathic surgery, Obstructive sleep apnea, Dental implants.

RESUMO

Entre as opções de tratamento da Apneia Obstrutiva do Sono (AOS) temos a cirurgia para correção das deformidades dentofaciais. Frequentemente, a combinação de cirurgia ortognática e implantes osseointegráveis pode ser necessária para permitir a reabilitação dental. Pacientes submetidos à cirurgia ortognática apresentam diminuição transitória do suprimento sanguíneo após procedimentos de osteotomia maxilar e mandibular, o que pode prejudicar os resultados nestes casos. Este relato de caso teve como objetivo apresentar e discutir a situação de um paciente com AOS que necessita de cirurgia ortognática e implantes dentários. O tratamento consistiu em: (1) extração de todos os dentes; (2) reabilitação completa da mandíbula superior e inferior com implantes dentários e próteses sem compensação; (3) cirurgia ortognática bimaxilar para restabelecer a relação maxilomandibular e aumentar o volume das vias aéreas superiores. Essa sequência de reabilitação foi uma alternativa segura para um caso de AOS Classe II, e rapidamente alcançou uma reabilitação com estética, funcionalidade, biomecânica aprimorada, manutenção da higiene oral e satisfação do paciente.

Palavras-chave: Cirurgia Ortognática, Apneia Obstrutiva do sono; Implantes Dentários.

1. University of Alfenas. University Hospital Alzira Velano. Department of Oral and Maxillofacial Surgery, Unifenas, Alfenas, (MG), Brazil.
2. University of São Paulo (Campus Ribeirão Preto) – FORP/USP, Ribeirão Preto, (SP), Brazil.
3. University of Brasília. Department, Health Science School, Brasília, (DF), Brazil.



INTRODUCTION

Obstructive sleep apnea (OSA) is characterized by recurrent episodes of complete or partial obstruction of the upper airway leading to reduced or absent breathing during sleep. OSA causes severe symptoms, such as excessive daytime somnolence, snoring, difficulties concentrating, morning headache and irritability, and is often associated with significant cardiovascular morbidity and mortality ¹.

Orthognathic surgery is one of the treatment options for OSA, with reliable results ¹. After accurate pre-surgical planning, this surgical technique is used to reposition the upper and/or lower jaw to the desired new location, which results in changes in the facial skeleton and soft tissues that cover these structures. Recently, there have been improvements in the maxillomandibular advancement techniques, and rotation of the occlusal plane ²⁻⁴ has provided another resource for improving the success rates of orthognathic surgery performed in OSA patients¹.

In the majority of orthognathic procedures, the vascular supply is manipulated. This is especially important when performing multisegmented Le Fort I osteotomies, because maxillary hard and soft tissues are dependent on their blood supply from the palatal and posterior buccal soft tissue pedicles ⁵. Excellent work on the revascularization and quantification of pre- and postoperative blood flow in monkeys has improved our knowledge of the biological basis for undertaking maxillary osteotomies ⁶⁻⁸. However, vascular necrosis continues to be a rare, but real complication ^{9,10}. Complications from this vascular ischemia include delayed healing, gingival tissue loss, periodontal defects, and loss of teeth and bone segments ⁹⁻¹¹, which may impair rehabilitation with dental implants in specific cases.

Considering that dental implants are often required in order to perform complete rehabilitation before or after orthognathic surgery ¹², careful planning is fundamental to guarantee osseointegration and the overall treatment success ¹³⁻¹⁶. This may consider the timing of implant placement, physical and chemical characteristics of the implant surface and mechanical stability to accelerate immune-inflammatory interactions, angiogenesis, and osteogenesis ¹⁷. This case report aimed to present and discuss the conflicting situation of an OSA patient in need of orthognathic surgery and dental implants.

CASE REPORT

The patient, a 53-year-old leukoderma female patient, sought care at the Oral and Maxillofacial Surgery Department of University Hospital Alzira Velano, in Alfenas - Brazil, complaining of a toothache, shortness of breath and snoring. She was referred by a doctor for treatment of OSA with orthognathic surgery. She had controlled hypertension and did not report chronic use of any other medications. An extrabuccal physical examination revealed labial incompetence, anteroposterior (AP) pogonion deficiency, with a raised mandibular plane and an increase in vertical height of the inferior third of the face. The intra-buccal examinations showed poor oral hygiene, gingival inflammation, increased periodontal probing pocket depth, unsatisfactory rehabilitation and mobility of maxillary anterior teeth, fistula near tooth 24, gingival recessions of mandibular incisors, and Class II malocclusion, with anterior open bite and marked over jet (Figure 1A-E).

The panoramic radiograph showed normal condyles (the patient had no joint complaints), teeth 17, 27, 28, 38, 46 and 47 were missing, generalized alveolar bone loss, endodontic treatment, and inadequate prostheses replaced the upper anterior teeth (Figure 1F). The lateral cephalometric radiograph mainly indicated the typical characteristics of dolichocephalic patients such as hyper-divergence of the mandibular and occlusal planes in relation to the base of the skull, vertical increase in the lower third of the face, with clockwise rotation of the mandible, AP mandibular deficiency and narrowing of the airways (Figure 1G), characteristic of patients with OSA.

Based on the clinical diagnosis, cost-effective maintenance of teeth, treatment duration and the patient's social condition, a treatment plan was established and included the following steps: (1) extraction of all teeth; (2) complete upper and lower jaw rehabilitation with dental implants (Branemark's protocol), dental prosthesis without compensation, and occlusion reproducing the bone discrepancies; (3) Bimaxillary orthognathic surgery to re-establish an adequate maxillomandibular relationship.

Firstly, all upper and lower teeth were removed under local anesthesia. Immediately after this, six implants were placed in the maxilla (Drive Ti Acqua®, Neodent, Curitiba, Paraná, Brazil) and four in the mandible (Titamax Ti Cortical®- Neodent, Curitiba, Paraná, Brazil), in positions compatible with the decompensated teeth extracted, dental arch alignment and labial support (Figure 2A).

Afterwards, full arch definitive maxillary, and mandibular prosthesis, which had previously been planned to reproduce the bone discrepancies, were immediately placed, without taking into consideration the correct maxillomandibular occlusion relationship. These steps were concluded before the orthognathic surgery was performed (Figure 2B-E). At that time, the patient was in a condition clinically similar to that of a conventional Class II patient prepared for undergoing orthognathic surgery. The postoperative panoramic radiograph showed the implants and metal framework (Figure 2F).

Preoperative radiographs for planning orthognathic surgery were obtained. A silicone plate with an internal metal foil covering the occlusal aspect of the maxillary molar and central incisor was fabricated on a plaster model of the implant prosthesis, in order to maintain the shape of the acrylic teeth in the radiographic exams, facilitating cephalometric tracings (Figure 3A-C). Conventional orthognathic surgery planning with facial analysis, predictive cephalometric tracing and model surgery were performed.

Two weeks after the placement of the implants and full arch definitive prosthesis, bimaxillary orthognathic surgery was performed under general anesthesia. First the mandible was treated with 11 mm advancement and counterclockwise rotation of the occlusal plane, followed by repositioning of the maxilla

to create an appropriate facial profile and occlusal relationship. The surgical procedure was uneventful, and surgical splints (intermediate and final) made from model surgery were used. Intraoperative intermaxillary fixation (IMF) was carried out with steel wires tied under the implant-supported prosthesis. Note that the implants inserted before the orthognathic surgery were important in assisting the surgeon to obtain and maintain the suitable final maxillomandibular position. There was no need for elastic therapy or prosthesis adjustment after surgery.

A significant improvement in the maxillo-mandibular relationship was achieved by correcting the large discrepancy in antero-posterior and vertical directions. Improvement in facial esthetics could also be noted, as a result of adequate horizontal and vertical positioning of the upper and lower jaws and satisfactory occlusion (Figure 4 A-E). Comparison between the lateral radiographs captured at the beginning of the treatment, implant placement and those captured post-orthognathic surgery showed a significant increase of the upper airways (Figure 4 F-H), resulting in a better quality of life. Postoperative radiographs showed proper positioning of the mandible and maxilla with no signs of relapse, and integrated dental implants. At the 1-year follow-up the patient was satisfied with the rehabilitation and did not report any complaints.

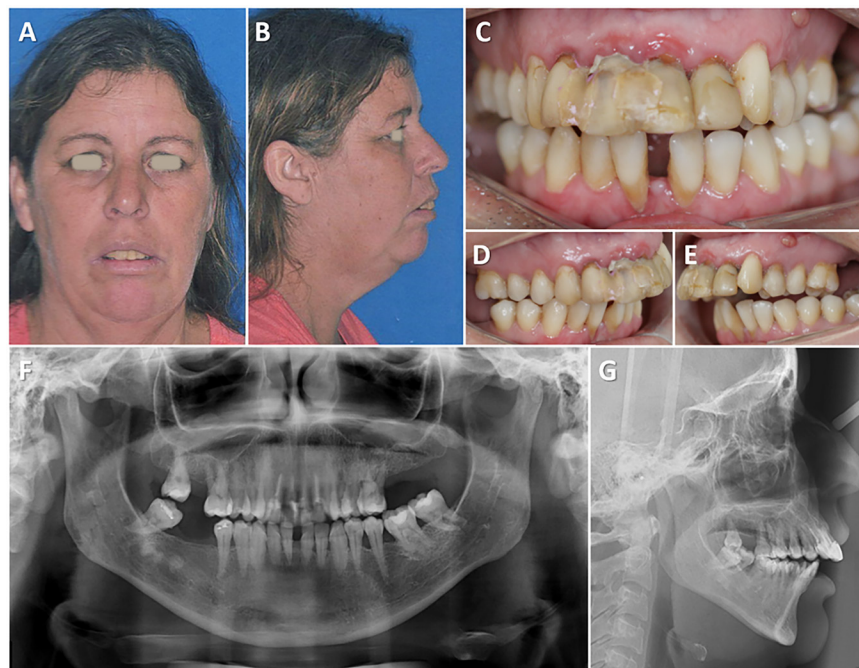


Figure 1. Frontal aspect (A) and facial profile (B) before treatment. Note vertical excess in the lower third and anteroposterior deficiency of the jaws. (C-E) Intra-buccal aspect evidencing class II malocclusion. Initial panoramic (F) and lateral cephalometric (G) radiographs. Note maxillo-mandibular discrepancy.

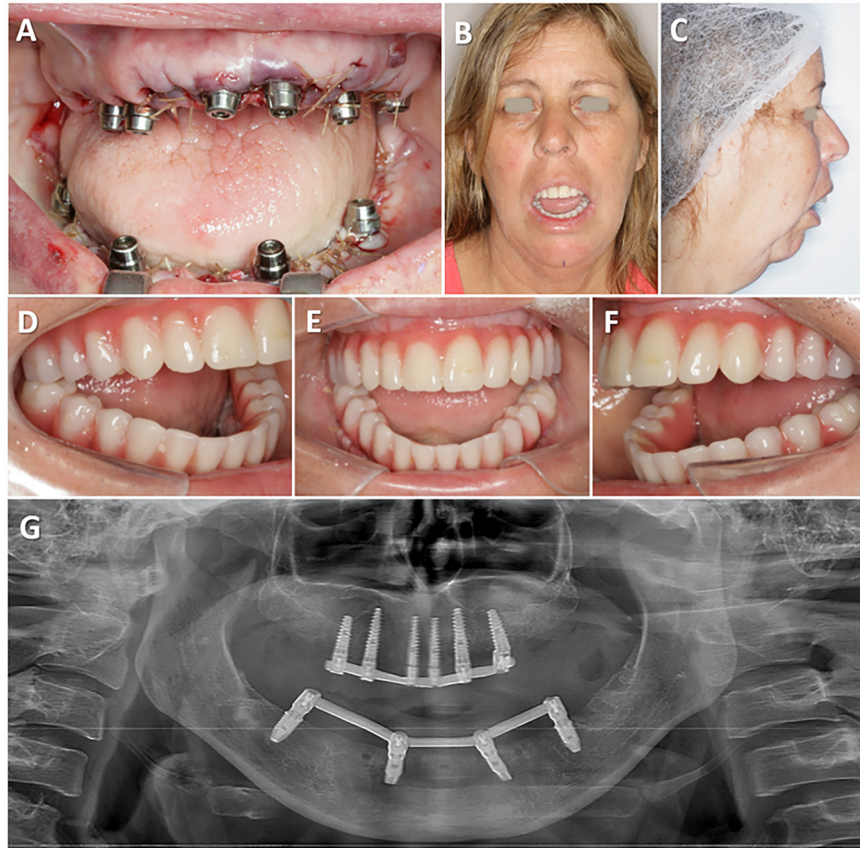


Figure 2. (A) Implants placed immediately after teeth extraction. Frontal aspect (B), facial profile (C) and Intra-buccal view (D-F) after implant placement. Note the prostheses maintaining maxillo-mandibular discrepancy. (G) Panoramic radiograph after implant installation.

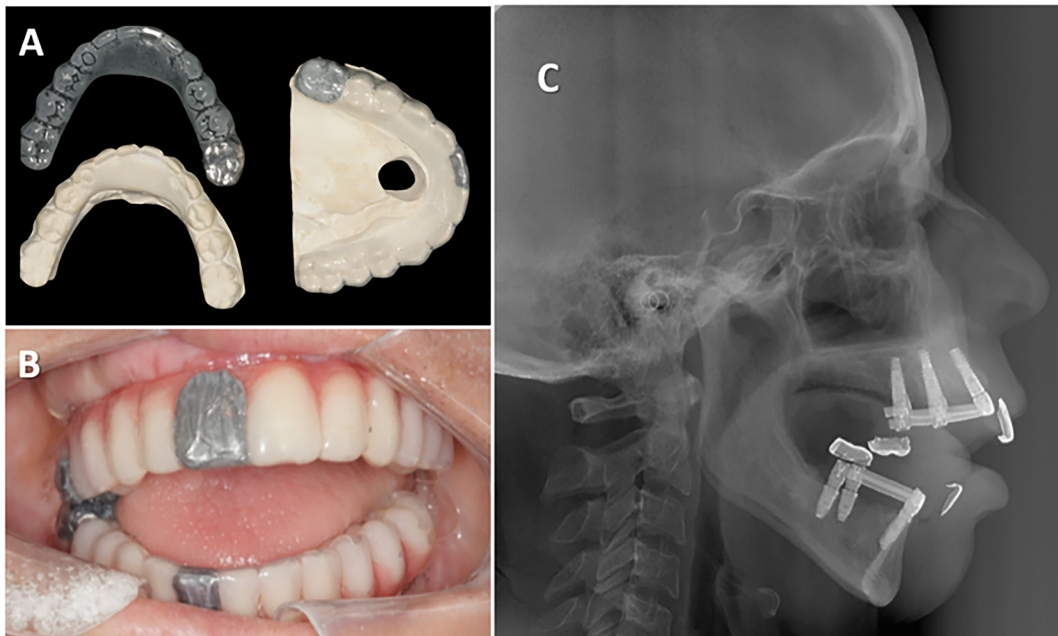


Figure 3. (A) Silicone plate with an internal metal foil covering molar and incisor fabricated using a plaster model. Silicone plate positioned in the patient's mouth (B) and in lateral cephalometric radiograph (C). Note that the divergence of the of the maxilla and mandible occlusal planes is similar to that between the palatine and mandibular planes.

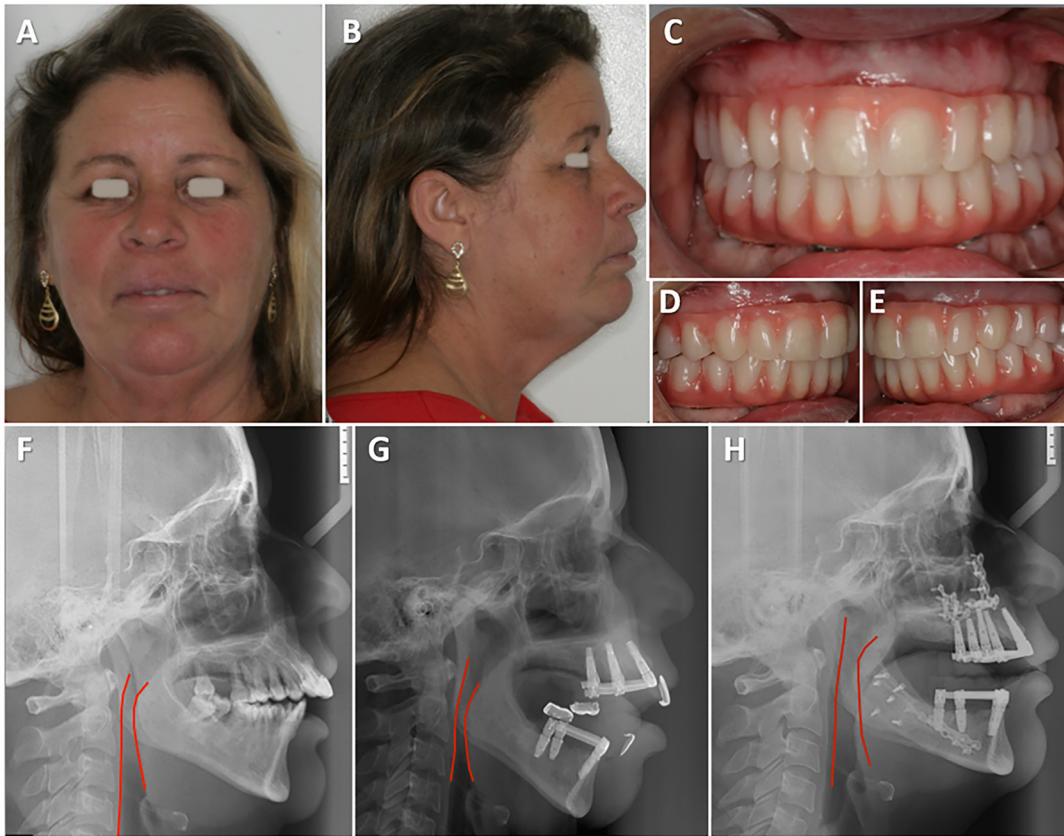


Figure 4. Frontal aspect (A), facial profile (B) and Intra-buccal view (C-E) after orthognathic surgery. Note the facial aesthetics and proper occlusion. Lateral radiographs before treatment (F), after implant placement (G) and after orthognathic surgery (H) illustrating the final increase of the airways.

DISCUSSION

Management of patients with skeletal malocclusion, OSA and periodontal disease has always been challenging. These patients often have a poor quality of life, inappropriate maxillomandibular relationship, missing teeth, and unfavorable profile, conditions that require interdisciplinary treatment¹. This may be even more important in patients in whom extensive maxillomandibular advancement is necessary to guarantee traction of the supra-hyoid muscles and a significant increase in upper airway dimensions^{3,4}. In the cases of OSA patients, this is why orthognathic surgery is planned to permit bi-maxillary advancement and counterclockwise rotation of the occlusal plane². For this purpose, the pre-surgical orthodontic treatment is conventionally performed to align and level the teeth within their bony bases, decompensating the inadequate angles of the incisors, and after orthognathic surgery, stability is finally achieved with the upper and lower teeth fitting in proper occlusion².

However, in the present case, tooth extractions were performed due to periodontal disease, making this conventional approach impossible. Therefore, our planning included both orthognathic surgery and implant-prosthetic care.

Some studies have discussed the combination of implant-supported rehabilitation and orthognathic surgery^{12-15,18}; however, clinical sequences vary considerably, especially when bone graft procedures are also necessary. In our case, the chosen approach was to place the implants before the orthognathic surgery. In this situation, an implant-supported fixed prosthesis was fabricated without compensation and reproduced the bone discrepancies¹⁴. This made it possible to identify the relationship between the upper and lower lip and the incisors. Furthermore, the midline, anteroposterior and vertical corrections could be measured more accurately when the fixed prosthesis were in place, which facilitated the orthognathic surgery planning^{14,16,18}. Moreover, this made it possible to perform regular surgical steps such as the use of surgical splints and IMF.

Thus, planning and stability of orthognathic surgery seem to be more predictable using this approach, because the pre-, peri-, and postoperative management of these patients becomes similar to that of a conventional patient¹⁶.

Although this technique has many advantages, it is important to note that optimal three-dimensional positioning of the implants is crucial, and the design of the final implant-supported fixed prosthesis depends on the mentioned implant positioning¹⁴. A fixed prosthesis without compensation allows for better esthetics, function, and has shown lower failure rates due to improved biomechanical stability, contributing to achieving better treatment results¹⁸.

At present, one of the clinical indications of maxillomandibular advancement surgery is the treatment of OSA patients¹. In this case study, the patient complained that she did not sleep well, slept when seated, and constantly felt the need to sleep outdoors to reduce her shortness of breath. The proposed maxillomandibular advancement with counterclockwise rotation increased the pharyngeal airway space and strengthened the suprahyoid and palatopharyngeal musculature because it altered the position of their bone fixations^{3,4}. This morphological change interrupted the repetitive collapse and consequently reduced hypopnea and apnea, normalizing the cardiorespiratory functions¹. Thus, the patient stated that she no longer had any symptoms of OSA.

There is a consensus that orthognathic surgery generates a decrease in blood flow, even if only transiently⁵⁻⁸. Considering the complications arising from this possible vascular ischemia, there was a major concern about selecting implants that optimize the bone repair, enhance the bone-to-implant interface, and improve osseointegration, especially when inserted only 2 weeks before orthognathic surgery, as occurred in the present case. The surface properties of dental implants appear to be one of the most important parameters affecting the speed of osseointegration¹⁹, especially in low density bone tissue, thus in the present case, the Drive Ti Acqua® was selected for the maxilla. Apparently, these modified hydrophilic surface properties favor the adsorption of proteins and are capable of activating osteoblasts into a more osteogenic phenotype¹⁹. Whereas the insertion of implants with this type of surface into the bone with greater density, such as the mandible, offers no advantages. Therefore, Titamax Ti Cortical® was chosen for mandibular implants, as they are known to favor osteogenesis, compared with machined implants²⁰.

Another determining factor for successful osseointegration is the primary stability of the implant, which is dependent on bone density, bone quality, and implant location^{21,22}. Furthermore, different macro-geometries influence primary stability^{22,23}. This was the reason for selecting conical implants for the maxilla in the present case. Cylindrical implants were used for the mandible, with cutting apex for the anterior, and conical apex for the posterior region (Easy, Connection Prosthetic System® - São Paulo, Brazil).

This rehabilitation sequence of dental implant placement and orthognathic surgery was a safe and predictable alternative for the case of Class II OSA, and rapidly achieved a final restoration with enhanced esthetics, functionality, biomechanics, maintenance of oral hygiene, and patient satisfaction. However, to assess the success rate of implants followed by orthognathic surgery, a longer follow-up period with a larger group of cases would be required.

CONCLUSION

Implant-supported dental prosthesis and orthognathic surgery for the rehabilitation of patients with obstructive sleep apnea resulted in improved respiratory and masticatory functions. The implants used exhibited good primary stability, and to date, there have been no signs of complications. In addition, there was a significant improvement in the patient's facial esthetics and quality of life.

REFERENCES

1. Andrews, B. T., Lakin, G. E., Bradley, J. P. & Kawamoto, H. K. Orthognathic surgery for obstructive sleep apnea: Applying the principles to new horizons in craniofacial surgery. *J. Craniofac. Surg.* **23**, 2038–2041 (2012).
2. Esteves, L. S., Ávila, C. & Medeiros, P. J. Changes in occlusal plane through orthognathic surgery TT - Alteração do plano oclusal na cirurgia ortognática. *Dental Press J. Orthod.* **17**, 160–173 (2012).
3. Araújo, P. M. *et al.* Pharyngeal airway space changes after maxillomandibular advancement: a five-year retrospective study. *Int. J. Oral Maxillofac. Surg.* (2019) doi:10.1016/j.ijom.2019.01.003.
4. Prado, F. B. *et al.* Pharyngeal airway space and frontal and sphenoid sinus changes after maxillomandibular advancement with counterclockwise rotation for class II anterior open bite malocclusions. *Dentomaxillofacial Radiol.* (2012) doi:10.1259/dmfr/22419253.

5. Garg, S. & Kaur, S. Evaluation of Post-operative Complication Rate of Le Fort I Osteotomy: A Retrospective and Prospective Study. *J. Maxillofac. Oral Surg.* **13**, 120–127 (2014).
6. Bell, W. H. Biologic basis for maxillary osteotomies. *Am. J. Phys. Anthropol.* **38**, 279–289 (1973).
7. Bell, W. H., Fonseca, R. J., Kennedy, J. W. & Levy, B. M. Bone healing and revascularization after total maxillary osteotomy. *J. Oral Surg. (Chic.)* (1975).
8. Bell, W. H., You, Z. H., Finn, R. A. & Fields, R. T. Wound healing after multisegmental le fort i osteotomy and transection of the descending palatine vessels. *J. Oral Maxillofac. Surg.* (1995) doi:10.1016/0278-2391(95)90670-3.
9. Pereira, F. L., Yaedú, R. Y. F., Sant'Ana, A. P. & Sant'Ana, E. Maxillary Aseptic Necrosis After Le Fort I Osteotomy: A Case Report and Literature Review. *J. Oral Maxillofac. Surg.* (2010) doi:10.1016/j.joms.2009.07.099.
10. Teemul, T. A., Perfettini, J., Morris, D. O. & Russell, J. L. Post-operative avascular necrosis of the maxilla: a rare complication following orthognathic surgery. *J. Surg. Case Reports* **2017**, rjw240 (2017).
11. Lanigan, D. T., Hey, J. H. & West, R. A. Aseptic necrosis following maxillary osteotomies: Report of 36 cases. *J. Oral Maxillofac. Surg.* **48**, 142–156 (1990).
12. Bayat, M., Khobyari, M. M., Dalband, M. & Momen-Heravi, F. Full mouth implant rehabilitation of a patient with ectodermal dysplasia after orthognathic surgery, sinus and ridge augmentation: A clinical report. *J. Adv. Prosthodont.* **3**, 96–100 (2011).
13. Lopes, J. F. S., Pinto, J. H. N., Lopes, M. M. W., Mazottini, R. & Soares, S. Interrelationship between implant and orthognathic surgery for the rehabilitation of edentulous cleft palate patients: A case report. *J. Appl. Oral Sci.* **23**, 224–229 (2015).
14. Batista Mendes, G. C., Laskarides, C., Ayub, E. A. & Ribeiro-Junior, P. D. Dental Implants Can Facilitate Orthognathic Surgery in a Patient With Severe Maxillary Atrophy. *J. Oral Maxillofac. Surg.* (2019) doi:10.1016/j.joms.2018.11.004.
15. Cao, J., Zhou, W., Shen, S., Wu, Y. & Wang, X. Implant-supported provisional prosthesis facilitated the minor revision of occlusion and incisor exposure after orthognathic surgery of extended oligodontia in maxilla. *J. Dent. Sci.* (2020) doi:10.1016/j.jds.2020.01.001.
16. Gil, J. N., Claus, J. D. P., Campos, F. E. B. & Lima, S. M. Management of the severely resorbed maxilla using Le Fort I osteotomy. *Int. J. Oral Maxillofac. Surg.* (2008) doi:10.1016/j.ijom.2008.10.003.
17. Feller, L. *et al.* Osseointegration: biological events in relation to characteristics of the implant surface. *SADJ: journal of the South African Dental Association = tydskrif van die Suid-Afrikaanse Tandheelkundige Vereniging* (2014).
18. Khojasteh, A., Payaminia, L. & Alikhasi, M. Implant assisted ortho-surgery in edentulous jaws: a clinical report. *Clin. Case Reports* **3**, 920–926 (2015).
19. Sartoretto, S. C. *et al.* Early osseointegration driven by the surface chemistry and wettability of dental implants. *J. Appl. Oral Sci.* (2015) doi:10.1590/1678-775720140483.
20. Xavier, S. P., Ikuno, K. E. & Tavares, M. G. Enhanced bone apposition to Brazilian microrough titanium surfaces. *Braz. Dent. J.* (2010) doi:10.1590/s0103-64402010000100003.
21. Farré-Pagès, N. *et al.* Relation between bone density and primary implant stability. *Med. Oral Patol. Oral Cir. Bucal* (2011) doi:10.4317/medoral.16.e62.
22. Falco, A., Berardini, M. & Trisi, P. Correlation Between Implant Geometry, Implant Surface, Insertion Torque, and Primary Stability: In Vitro Biomechanical Analysis. *Int. J. Oral Maxillofac. Implants* (2018) doi:10.11607/jomi.6285.
23. Valente, M. L. da C., de Castro, D. T., Shimano, A. C., Lepri, C. P. & dos Reis, A. C. Analysis of the influence of implant shape on primary stability using the correlation of multiple methods. *Clin. Oral Investig.* (2015) doi:10.1007/s00784-015-1417-4.

Author contribution:

Santana, SI (responsible for: performing the surgeries as well as postoperative follow-up and scientific review);

Santana, BSP (responsible for: bibliographical update of the article, photo editing and scientific review).

Rocha, FS (responsible for: writing the manuscript and scientific review)

Rodrigues, AR (responsible for: performing the surgeries as well as postoperative follow-up and scientific review).

Corresponding Author:

Sandro Isaías Santana

sandro@bucomaxilosuldeminas.com.br

Editor:

Prof. Dr. Marcelo Riberto

Received: Jan 05, 2021

Approved: oct 04, 2021
