




Telogen Effluvium and COVID-19: a case and a brief review of literature

Eflúvio Telógeno e COVID-19: um caso e uma breve revisão de literatura

Francisco Kleyton Zacarias Florêncio^{1,2}, Maiza de Oliveira Tenório³, Sandro Gonçalves de Lima^{1,3,4}

ABSTRACT

COVID-19 is a new disease that has brought a great impact on global morbidity and mortality. There have been increasingly frequent reports of persistent symptoms and/or clinical manifestations attributed to COVID-19 after the acute phase of the disease. In this article, we present a case of post-COVID-19 telogen effluvium in a 39-year-old hypertensive and obese patient who looked for medical attention due to massive hair loss. Previous history of moderate COVID-19 4 months ago. After investigation and exclusion of other possible causes of telogen effluvium well established in the literature, the condition was attributed to the previous episode of COVID-19. Persistent fever, the cytokine storm, and the entire immunological cascade of COVID-19 can lead to apoptosis of the keratinocytes of the hair follicles, initiating the catagen phase early followed by the telogen phase with a consequent capillary release. Late symptoms possibly secondary to COVID-19 should receive attention and interest from the medical and scientific community. As it is a new disease, whose late consequences are not yet fully known/elucidated, careful observation and careful clinical follow-up of these patients are recommended.

Keywords: Alopecia, Coronavirus infections, Fever, Immune system, Cytokines.

RESUMO

A COVID-19 é uma doença nova que vem provocando grande impacto na morbimortalidade mundial. Relatos de persistência de sintomas e/ou manifestações clínicas atribuídas à COVID-19 após a fase aguda da doença tem sido cada vez mais frequentes. Neste artigo, apresentamos um caso de eflúvio telógeno pós COVID-19 em um paciente de 39 anos, hipertenso e obeso, que procurou atendimento médico devido à queda volumosa de cabelos. Histórico prévio de COVID-19 moderada há 4 meses. Após investigação e exclusão de outras possíveis causas de eflúvio telógeno bem estabelecidas na literatura o quadro foi atribuído ao episódio prévio de COVID-19. É possível que a febre persistente, a tempestade de citocinas e toda a cascata imunológica da COVID-19 possam levar à apoptose dos queratinócitos dos folículos capilares, iniciando, assim, precocemente a fase catágena seguida pela fase telógena com consequente liberação capilar. Sintomas tardios possivelmente secundários à COVID-19 devem ser alvo de atenção e interesse da comunidade médica e científica. Por se tratar de uma doença nova, cujas consequências tardias ainda não se encontram completamente conhecidas/elucidadas, recomenda-se a observação atenta e o seguimento clínico criterioso desses pacientes.

Palavras-chave: Alopecia, Infecções por Coronavírus, Febre, Sistema imunitário, Citocinas.

1. Hospital das Clínicas da Universidade Federal de Pernambuco, Recife, (PE), Brasil.
2. Hospital Metropolitano Sul Dom Hélder Câmara. Cabo de Santo Agostinho, (PE), Brasil.
3. Universidade Federal de Pernambuco. Centro de Ciências Médicas, Recife, (PE), Brasil.
4. Universidade Federal de Pernambuco. Departamento de Medicina Clínica, Recife, (PE), Brasil.



INTRODUCTION

COVID-19 is a new disease with a complex pathophysiology and has brought a great impact on global morbidity and mortality¹. The disease has already caused six million deaths worldwide², and, by march 2022, Brazil will have accumulated more than 650,000 deaths³.

Over the last few months, there have been increasingly frequent reports of persistent symptoms and/or clinical manifestations attributed to COVID-19, which were not presented during the acute phase of the disease⁴⁻⁷. Some of the clinical manifestations after the acute phase of COVID-19 reported in the literature have been increased heart rate at rest⁴, thrombosis in the right atrium⁵, delirium⁷, and cognitive and psychological manifestations⁷. Regarding the cutaneous manifestations, maculopapular rash⁸, pernio-like skin lesions, purpura and necrosis were described in the literature⁹. Identifying and understanding these conditions is essential in clinical practice, in order to promote better patient management and rehabilitation.

Knowledge regarding the pathophysiology of these conditions after the acute phase of COVID-19 is still somewhat limited. The explanation for such clinical manifestations may come from mechanisms such as hypercoagulability¹⁰, endothelial injury^{10,11}, dysregulation of the ACE2 receptor¹², cytokine storm¹³, amongst others.

Below, we present the clinical case of a patient who presented telogen effluvium as a late clinical manifestation of covid-19.

CASE REPORT

A 39-year-old, white, male patient, a trader and lawyer, living in the town of Santa Cruz do Capibaribe, in the state of Pernambuco, Brazil, sought medical advice because he had suffered from persistent, bulky hair loss over a period of one month. The patient denied having previously noticed such hair loss with similar characteristics. He presented with no other symptoms at the time of the consultation.

The patient had systemic arterial hypertension (taking chlortalidone 50 mg once a day) and was obese, with a BMI of 33.05 kg/m². He reported no history of kidney disease, hyper or hypothyroidism, liver disease, coronary artery or cerebrovascular disease, diabetes mellitus, past bleeding or allergies.

He stated that he had experienced no acute stress or trauma over the previous few months. He reported taking no other medication, except for the abovementioned antihypertensive, including those commonly associated with telogen effluvium (beta-blockers, anticonvulsants, retinoids, amongst others).

He also reported that he had been diagnosed four months earlier with moderate COVID-19, characterized by a low to moderate persistent fever for six days, with a maximum peak of 38.5°C. As a complication of the disease, he presented with bacterial infection of the respiratory tract, and had taken amoxicillin (875mg) with clavulanate (125mg) twice a day for seven days. He was not referred for hospitalization during the acute illness.

On physical examination, it was possible to observe areas of hair rarefaction more evident in the bitemporal recess, frontal region and the cranial vertex (Figures 1 and 2).

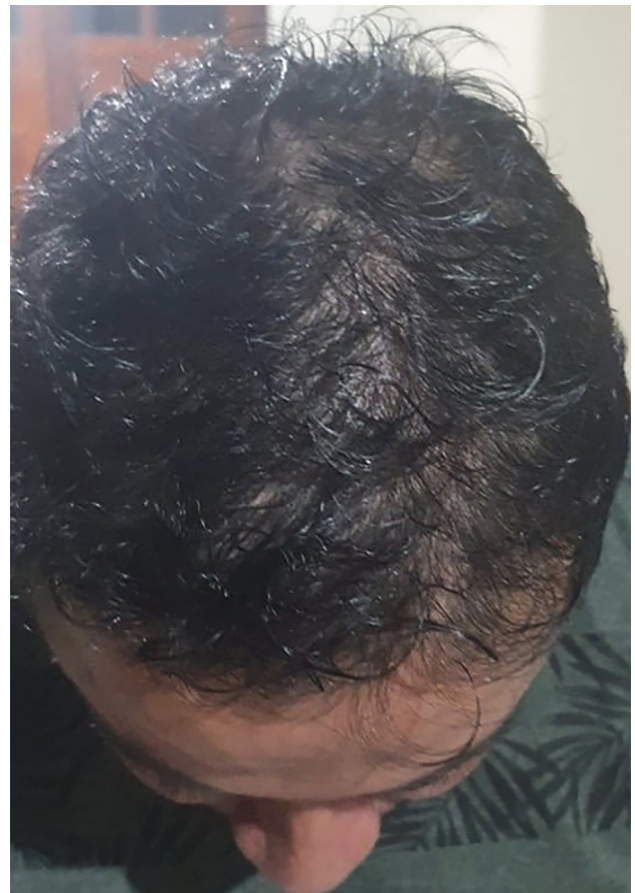

Figure 1. view from above showing hair rarefaction in the bitemporal recess, fronto-parietal and vertex regions.

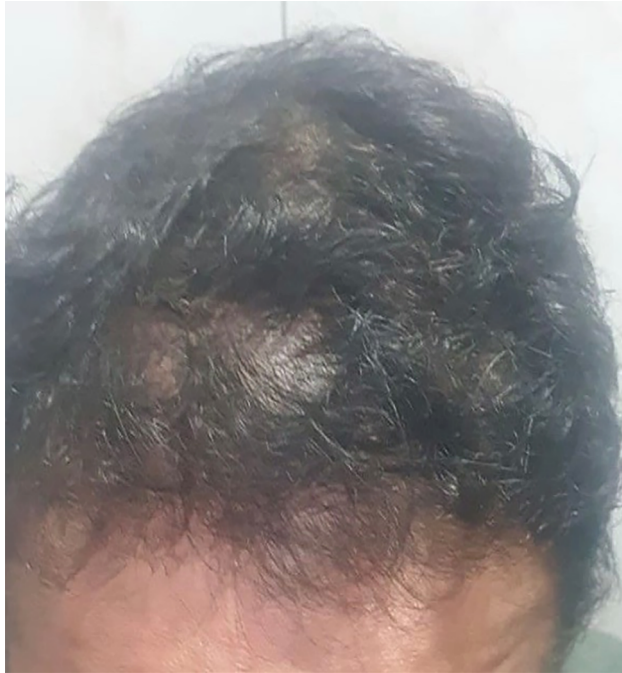

Figure 2. hair rarefaction details.

The patient was diagnosed with telogen effluvium. Additional exams were requested so as to investigate the most frequent causes of telogen effluvium: blood count, ferritin, iron kinetics, TSH, free T4, syphilis serology test and type 1 urine test. The laboratory results presented no changes, except for increased ferritin (523.5 mg/dL), a slight elevation of the blood sugar (101 mg/dL) and an increase in leukocytes in type I urine (24,000/mL).

DISCUSSION

Telogen effluvium is one of the most common non-scarring alopecia, and is characterized by excessive, diffuse hair loss¹⁴, the onset of which usually occurs 3 to 4 months after a triggering event.¹⁵ Multiple events may lead to the occurrence of telogen effluvium, such as post-childbirth, drugs (anticonvulsants, beta-blockers, oral contraceptives), hyper or hypothyroidism, iron deficiency anemia, infections, systemic lupus erythematosus, amongst others.^{14,15} In the clinical history and laboratory tests of the patient in the present report, no clinical condition or data were identified that could enable us to suggest a causal link with any of these events, which led us to raise the hypothesis of a manifestation secondary to the previous condition of COVID-19.

Other infectious diseases may also lead to telogen effluvium, the most frequent of which are syphilis, tuberculosis, typhoid, dengue and malaria.¹⁵ There are multiple mechanisms that explain how telogen effluvium secondary to infectious diseases occurs. It is possible that, in COVID-19, it occurs due to an immediate release of the anagen phase, leading to the occurrence of a loss of telogen strands over the following months. During infectious febrile episodes, released cytokines are able to promote apoptosis of the hair follicular keratinocytes, thus beginning the catagen phase followed by the telogen with hair loss¹⁵. The cytokine storm and the entire immune cascade described in cases of COVID-19, associated with a persistent fever for six days, reported by the presented patient, could explain the development of telogen effluvium.

In addition to the reported clinical presentation, it has been reported that patients with previous COVID-19 have developed other conditions after the acute infection. Mitrani et al. reported that up to 30% of patients hospitalized with COVID-19 present some degree of myocardial impairment, which, in the long term, may generate the risk of clinical or subclinical cardiomyopathies, as well as arrhythmias¹⁶. Torres et al. reported a case of thrombus in the right auricle after the disease⁵. In these cases of cardiac involvement and thrombosis, in addition to the immune cascade, hypercoagulability and a process of endothelial injury in COVID-19 justify these long-term clinical consequences. Histopathological studies have clearly demonstrated the process of endotheliitis and thrombosis as part of the pathophysiology of the disease.^{10,11}

The hypoxia that may occur during the acute phase of COVID-19 could also be responsible for manifestations after the disease. Lang et al. reported a case of leukoencephalopathy, possibly secondary to hypoxemia of the acute infectious process¹⁷. In addition to hypoxia, metabolic and immunological abnormalities could explain delirium and encephalopathy in patients who survived the acute phase⁷.

It is evident in the literature that COVID-19 can bring relevant cutaneous manifestations in both the acute and late phases. The study by Recalti et al.¹⁸ was one of the first studies published at the beginning of the pandemic alerting to this fact by showing that about 20.8% of the analyzed patients had cutaneous manifestations associated with the acute disease.

With the advancement of the pandemic, late manifestations such as pernio-like⁹, maculopapular rash⁸ and telogen effluvium¹⁹ were evidenced in studies. Besides, an increase in cases of alopecia areata²⁰ has also been associated, however the pathophysiology of this correlation is less clear. Most of these late dermatological manifestations may be due to the immunological stress caused by COVID-19.

Late symptoms possibly secondary to COVID-19 should be the subject of attention and interest for the scientific community. Since it is a new disease, the later consequences of which are not yet fully known, careful observation and careful clinical follow-up should be offered to patients to achieve a better pathophysiological understanding, accurate diagnosis, effective treatment, and rehabilitation.

REFERENCES

- Baj J, Karakula-Juchnowicz H, Teresiński G, Buszewicz G, Ciesielka M, Sitartz E et al. COVID-19: Specific and Non-Specific Clinical Manifestations and Symptoms: The Current State of Knowledge. *J. Clin. Med.* 2020;9(6):1753. DOI: <https://doi.org/10.3390/jcm9061753>
- John Hopkins University [homepage on internet]. COVID-19 Map [accessed on 03 mar 2022]. Available in: <https://coronavirus.jhu.edu/map.html>
- Ministério da Saúde [homepage on internet]. Painel Coronavírus [accessed on 03 mar 2022]. Available in: <https://covid.saude.gov.br/>
- Xiong Q, Xu M, Li J, Yinghui L, Zhang J, Xu Y, et al. Clinical sequelae of COVID-19 survivors in Wuhan, China: a single-centre longitudinal study. *Clin Microbiol Infect.* 2020;27(1):89-95. DOI: <https://doi.org/10.1016/j.cmi.2020.09.023>
- Torres LA, Garrido EC, Borja PM. Trombo en la aurícula derecha tras neumonía por COVID-19. *Rev Esp Cardiol.* 2020;73(10):845. DOI: <https://doi.org/10.1016/j.recesp.2020.06.007>
- Tung-Chen Y, Blanco-Alonso S, Antón-Huguet B, Figueras-López C, Ugueto-Rodrigo C. Dolor torácico persistente tras resolución de la enfermedad por coronavirus 2019 (COVID-19). *Semergen.* 2020;46(S1):88-90. DOI: <https://doi.org/10.1016/j.semerg.2020.06.006>
- Azizi SA, Azizi S. Neurological injuries in COVID-19 patients: direct viral invasion or a bystander injury after infection of epithelial/endothelial cells. *J Neurovirol.* 2020;26:631-41. DOI: <https://doi.org/10.1007/s13365-020-00903-7>
- Revés J, Brochado AI, Costa CA, Araújo IM. Exantema Maculopapular como Manifestação Tardia da Infecção por SARS-CoV-2. *Medicina Interna.* 2020;27(4):324-5. DOI: <https://doi.org/10.24950/Imagem/150/20/4/2020>
- Seque CA, Simões MM, Enokihara S, Porro AM, Tomimori J. Manifestações Cutâneas Associadas à COVID-19. *Anais Brasileiros de Dermatologia.* 2022;97(1):75-88.
- Ackermann M, Verleden SE, Kuehnel M, Haverich A, Welte T, Laenger F, et al. Pulmonary Vascular Endothelialitis, Thrombosis, and Angiogenesis in Covid-19. *N Engl J Med [Internet].* 2020;383(2):120–8. DOI: <https://doi.org/10.1056/NEJMoa2015432>
- Varga Z, Flammer AJ, Steiger P, Haberecker M, Andermatt R, Zinkernagel AS, et al. Endothelial cell infection and endotheliitis in COVID-19. *Lancet [Internet].* 2020;395(10234):1417–8. DOI: [https://doi.org/10.1016/S01406736\(20\)30937-5](https://doi.org/10.1016/S01406736(20)30937-5)
- Bourgonje AR, Abdulle AE, Timens W, Hillebrands JL, Navis GJ, Gordijn SJ, et al. Angiotensin-converting enzyme 2 (ACE2), SARS-CoV-2 and the pathophysiology of coronavirus disease 2019 (COVID-19). *J Pathol.* 2020;251(3):228-48. DOI: <https://doi.org/10.1002/path.5471>
- Hu B, Huang S, Yin L. The cytokine storm and COVID-19. *J Med Virol.* 2020;1-7. DOI: <https://doi.org/10.1002/jmv.26232>
- Asghar F, Shamim N, Farooque U, Sheikh H, Aqeel R. Telogen Effluvium: A Review of the Literature. *Cureus.* 2020;12(5):e8320. DOI: <https://doi.org/10.7759/cureus.8320>
- Malkud S. Telogen Effluvium: A Review. *J Clin Diagn Res.* 2015;9(9):WE01-3. DOI: <https://doi.org/10.7860/JCDR/2015/15219.6492>
- Mitrani RD, Dabas N, Goldberger JJ. COVID-19 cardiac injury: Implications for long-term surveillance and outcomes in survivors. *Heart Rhythm.* 2020;17(11):1984-90. DOI: <https://doi.org/10.1016/j.hrthm.2020.06.026>
- Lang M, Buch K, Li MD, Mehan WA, Lang AL, Leslie-Mazwi TM, et al. Leukoencephalopathy associated with severe COVID-19 infection: sequela of hypoxemia?. *Am J Neuroradiol.* 2020;41(9):1641-5. DOI: <https://doi.org/10.3174/ajnr.A6671>
- Recalcati S. Cutaneous manifestations in COVID-19: a first perspective. *J. Eur. Acad. Dermatol. Venereol.* 2020, 34(5):e212-13. DOI: <https://doi.org/10.1111/jdv.16387>
- Soto SMA, Mestre MPD. Efluvio telógeno: una manifestación del síndrome Post-COVID-19. *Piel.* 2021;1-3. DOI: <https://doi.org/10.1016/j.piel.2021.06.013>
- Kutulcu Ö, Aktas H, İmren I, Metin H. Short-term stress-related increasing cases of alopecia areata during the COVID-19 pandemic. *Journal of Dermatological Treatment.* 2020; 1. DOI: <https://doi.org/10.1080/09546634.2020.1782820> [published online ahead of print, 2020 Jun 19].

Authors' contribution

FKZF: Conception and design of the study, Acquisition of data, Drafting the article; **MOT:** Drafting the article and Responsible to review the article; **SGL:** Conception and design of the study, Supervisor in the elaboration of the content of this article.

Conflicts of interest

None.

Autor Correspondente:
Maiza de Oliveira Tenório
maizatenorio@hotmail.com

Editor:
Prof. Dr. Felipe Villela Gomes

Received in: jan 12, 2021
Approved in: apr 29, 2022
